



th

# APVRS 2017

## Asia-Pacific Vitreo-retina Society Congress 2017

8<sup>th</sup> - 10<sup>th</sup> December 2017

Kuala Lumpur Convention Centre, Malaysia

<http://2017.apvrs.org>



Organised by



MALAYSIAN SOCIETY OF  
OPHTHALMOLOGY

Supported by







# CONTENTS

<b>1. FREE PAPERS .....</b>	<b>3</b>
1.1 Intraocular Inflammation, Uveitis & Scleritis.....	3
1.2 Retina (Medical).....	6
1.3 Retina (Surgical).....	27
<b>2. POSTERS.....</b>	<b>45</b>
2.1 Intraocular Inflammation, Uveitis & Scleritis.....	45
2.2 Retina (Medical).....	53
2.3 Retina (Surgical).....	85
<b>3. E-POSTERS.....</b>	<b>110</b>
3.1 Intraocular Inflammation, Uveitis & Scleritis.....	110
3.2 Retina (Medical).....	117
3.3 Retina (Surgical).....	136
<b>4. VIDEOS .....</b>	<b>150</b>
4.1 Intraocular Inflammation, Uveitis & Scleritis.....	150
4.2 Retina (Surgical).....	150





## FREE PAPERS

### Intraocular Inflammation, Uveitis & Scleritis

Dec 09, 2017 (Sat) 11:00 - 12:30

Venue: Room 302 & 303

#### Changing Trends in the Etiology of Exogenous Endophthalmitis: Is This a Paradigm Shift?

First Author: Jane **FOO**

Co-Author(s): Jay **CHANDRA**

**Purpose:** To describe a change in the etiology of cases of exogenous endophthalmitis from a tertiary referral center in Australia from 2000 to 2017.

**Methods:** Retrospective chart review.

**Results:** A total of 20 presumed exogenous endophthalmitis cases were identified: 10 after intravitreal injections (IVI group), while in the non-IVI group, there were 6 cases after cataract surgeries and 4 secondary to corneal ulcers. There were no cases of endophthalmitis in the IVI group until 2013. From 2013 to 2017, cases due to IVI were about 2-fold the number of cases in the non-IVI group. Mean age was older in the IVI group (77 versus 61 years). The major indication for IVI was age-related macular degeneration. Upon diagnosis, 100% in the IVI group had visual acuity of counting fingers or worse compared to 70% in the non-IVI group. In the IVI group, 9 out of 10 patients underwent vitreous tap with intravitreal antibiotic injection and all 10 cases required vitrectomy. The tenth case underwent immediate vitrectomy with intravitreal antibiotics on the day of presentation. In the non-IVI group, all 7 patients received intravitreal antibiotics upon diagnosis while only 4 underwent vitrectomy. Visual acuity 3 months after treatment was comparable in both groups, ie, in the IVI group, 70% achieved vision 3/60 or better compared to 60% in the non-IVI group.

**Conclusions:** Intravitreal injections are now

emerging as a major cause of exogenous endophthalmitis, replacing other causes (such as after cataract surgery, corneal pathology), a paradigm shift in the etiology of this complication.

Dec 09, 2017 (Sat) 11:00 - 12:30

Venue: Room 302 & 303

#### Correlation of Panoramic Optical Coherence Tomography Angiography Characteristics of Active and Healing Serpiginous-Like Choroiditis With Indocyanine Green Angiography

First Author: Rakesh **JUNEJA**

Co-Author(s): Ashish **JAIN**, Navneet **MEHROTRA**, Manish **NAGPAL**, Avijit **VISHNOI**

**Purpose:** To analyze the panoramic optical coherence tomography angiography (OCTA) imaging characteristics of serpiginous-like choroiditis and to compare these findings with indocyanine green angiography (ICGA) features.

**Methods:** Prospective cross-sectional study. Multimodal imaging was performed in subjects with serpiginous-like choroiditis using panoramic OCTA (NIDEK RS-3000), OCT (Heidelberg Spectralis), fundus autofluorescence, fluorescein angiography (Heidelberg Spectralis), and ICGA. Morphologic features at the sites of choroiditis lesions were analyzed using panoramic OCTA imaging and compared with ICGA with minimum 6 months of follow-up.

**Results:** Twenty eyes were included in the study. In the active stage, the en face panoramic OCTA images demonstrated discrete areas of flow void beneath the retinal pigment epithelium–Bruch membrane layer suggestive of choriocapillaris hypoperfusion that corresponded well with hypofluorescence in ICGA. In advanced stages of healing, preserved capillaries were observed corresponding to the



healed areas in ICGA. It gave a wider field of view than conventional OCTA.

**Conclusions:** The panoramic OCTA images are a useful noninvasive tool to study areas of activity in eyes with serpigino-like choroiditis. The changes observed during active and healing stages in panoramic OCTA correlated and corresponded well with ICGA images.

**Dec 09, 2017 (Sat) 11:00 - 12:30**

**Venue: Room 302 & 303**

### **Corticosteroid Tapering Success With Every-Other-Month Intravitreal Sirolimus for Noninfectious Uveitis of the Posterior Segment: Results of the SAKURA Program**

*First Author: Kalpana Babu MURTHY*  
*Co-Author(s): Abu ABRAHAM*

**Purpose:** To report corticosteroid (CST) tapering success in subjects with noninfectious uveitis of the posterior segment (NIU-PS) receiving every-other-month intravitreal (IVT) sirolimus.

**Methods:** The SAKURA program comprised 2 phase III, multinational, multicenter, randomized, double-masked studies. Patients had vitreous haze (VH)  $\geq 1.5+$  in the study eye at baseline. Subjects from both studies comprised the integrated intent-to-treat (ITT) population evaluating sirolimus 440  $\mu\text{g}$  ( $n = 208$ ) vs 44  $\mu\text{g}$  active control ( $n = 208$ ). Systemic immunosuppressants and topical CSTs were discontinued before baseline. VH = 0 and CST tapering success (overall prednisone-equivalent dose  $\leq 5$  mg/d without any rescue therapy) were assessed at month 5 (M5) in 46 subjects from the 440  $\mu\text{g}$  group and 32 from the 44  $\mu\text{g}$  group with overall prednisone-equivalent dose  $> 5$  mg/d at baseline (intent-to-taper population). Tapering success with VH 0/0.5+ at M5 was also assessed. Safety was assessed through month 6 (M6).

**Results:** A total of 21.2% and 13.5% of subjects (440 and 44  $\mu\text{g}$ , respectively) in the integrated ITT population achieved the primary endpoint of VH = 0 at M5 ( $P = 0.0381$ ). Tapering success

was achieved in 69.6% and 68.8% of 440 and 44  $\mu\text{g}$  subjects, respectively. Tapering success with VH 0/0.5+ was higher in 440  $\mu\text{g}$  vs 44  $\mu\text{g}$  (43.5% vs 28.1%,  $P = 0.1676$ ). Serious ocular adverse events (AEs) occurred in 11.1% ( $n = 5$ ) of 440  $\mu\text{g}$  and 16.7% ( $n = 5$ ) of 44  $\mu\text{g}$  intent-to-taper subjects.

**Conclusions:** Integrated analysis of the SAKURA program demonstrated that IVT sirolimus 440  $\mu\text{g}$  every other month achieved statistically significant improvements in VH at M5 in subjects with active NIU-PS. IVT sirolimus 440  $\mu\text{g}$  demonstrated potential as an effective CST-sparing agent.

**Dec 09, 2017 (Sat) 11:00 - 12:30**

**Venue: Room 302 & 303**

### **Endogenous Endophthalmitis Complicated by Pyogenic Liver Abscess: A Review of 9 Years' Experience**

*First Author: Lei GAO*

**Purpose:** Hepatic abscess induced endophthalmitis is one of the most common types of endogenous endophthalmitis. It is easily underdiagnosed or misdiagnosed in the early stage. The treatment is more complicated, requiring multispecialty cooperation throughout the whole process. We investigated the clinical features and treatment outcomes of endogenous endophthalmitis over the past 9 years at 1 center.

**Methods:** The clinical data of patients with hepatic abscess endophthalmitis treated in Yantai Yuhuangding Hospital from June 2008 to July 2017 were analyzed retrospectively.

**Results:** There was a total of 19 patients (10 male, 9 female; 21 eyes) with hepatic abscess induced endophthalmitis with the average age of 58.5. Patients were initially hospitalized in the hepatic biliary surgery department. Thirteen patients had diabetes, and 7 patients had positive culture for *Klebsiella pneumoniae* from vitreous body culture. Nineteen eyes were initially treated with intravitreal injection, and 2 eyes underwent emergency vitrectomy. Among





19 eyes with injections, vitrectomy had to be performed in 8 eyes. Among the pars plana vitrectomy (PPV) group, 9 eyes retained light perception vision; visual acuity of 4 eyes was better than 0.1, and there was only 1 case of evisceration. In the injection group of 9 eyes, there were 8 eyes with no light perception, of which 7 underwent evisceration and there was only 1 case of light vision preservation.

**Conclusions:** Hepatic abscess endophthalmitis is a serious clinical condition with poor prognosis. Physicians should pay attention to ocular symptoms as early diagnosis and intensive treatment with multispecialty collaboration are required to achieve improvements in visual outcome.

**Dec 09, 2017 (Sat) 11:00 - 12:30**

**Venue: Room 302 & 303**

### **NLRP3 Inflammasome Is Activated in Peripheral Mononuclear Blood Cells of Patients With Diabetic Retinopathy**

*First Author: Hui CHEN*

*Co-Author(s): Feng WEN*

**Purpose:** The purpose of this study was to determine whether NLRP3 activation occurs in patients with diabetic retinopathy (DR).

**Methods:** In total, 64 consecutive diabetic patients (43 with DR and 21 without DR, NDR) and 25 healthy controls were enrolled, and blood samples were collected for analysis. Protein expression of NLRP3 inflammasome components was detected by Western blot. Messenger RNA expression of NLRP3 inflammasome components was detected with quantitative real-time reverse transcription polymerase chain reaction (PCR). Interleukin (IL)-1 $\beta$  and IL-18 released in the medium of peripheral blood mononuclear cell (PBMC) cultures after treatment with lipopolysaccharide (LPS) alone or LPS and ATP was measured by enzyme-linked immunosorbent assay (ELISA). Immunohistochemical staining for apoptosis-associated speck-like protein (ASC), caspase-1, and NLRP3 expression was performed in fibrovascular membranes from 21 proliferative

DR (PDR) patients and 22 controls with idiopathic epiretinal membranes.

**Results:** We observed increased gene and protein expression of NLRP3, ASC, and caspase-1 in PBMCs from DR patients compared to healthy controls. Additionally, increased expression of NLRP3 and ASC was observed in lesions from 21 PDR patients compared to 22 controls. Compatible with this, secretion of IL-1 $\beta$  and IL-18 by PBMCs stimulated with LPS alone or LPS plus ATP was increased in DR patients compared to healthy controls.

**Conclusions:** These results indicated upregulation of NLRP3 inflammasomes in patients with DR and suggested an important role for inflammasomes in the pathogenesis and progression of DR.

**Dec 09, 2017 (Sat) 11:00 - 12:30**

**Venue: Room 302 & 303**

### **Study of Diverse Spectrum of Isolated Ocular Tuberculosis From Urban Population of Same Area**

*First Author: Shamik MOKADAM*

*Co-Author(s): Mandar JOGLEKAR, Vignesh RAJA, Smita UPADHYE*

**Purpose:** To report diversity in clinical presentation in urban patients presenting with ocular tuberculosis (TB) from the same geographic area.

**Methods:** Clinical features of 5 patients with ocular tuberculosis with strongly positive Mantoux test were thoroughly examined with slit lamp biomicroscopy and indirect microscopy. Angiography, optical coherence tomography, and anterior segment photography were done as indicated.

**Results:** Of the 5 cases, all presented with blurring of vision, 2 presented with ocular pain and headache on the involved side, 2 presented with floaters, and 1 with proptosis. Four patients had anterior chamber reaction and vitritis and 1 had a quiet eye (due to system intake of weekly methotrexate for psoriatic





lesions). Two patients had choroidal granuloma (1 at equator and 1 at the disc), 2 had intermediate uveitis, and 1 had serpiginous-like chorioretinitis. All patients were strongly positive for tuberculin skin test and/or TB Quantiferon Gold test. However, none had signs suggestive of systemic TB (confirmed by an infectious diseases specialist).

**Conclusions:** TB must be suspected especially in endemic countries in patients presenting with vitreous cells. The treating physician must bear in mind its diverse spectrum of presentation.

**Dec 09, 2017 (Sat) 11:00 - 12:30**

**Venue: Room 302 & 303**

### Sympathetic Ophthalmia in the Pediatric Population

*First Author: Mohit DOGRA*

*Co-Author(s): Ramandep SINGH, Pallavi SINGH*

**Purpose:** To study the clinical presentation, management, and outcomes of sympathetic ophthalmia (SO) in the pediatric population.

**Methods:** Retrospective study of patients less than 18 years of age with a diagnosis of SO presenting to a tertiary care eye center in India over a 15-year period.

**Results:** Fifteen pediatric patients with SO were included: 10 were posttraumatic and 5 postsurgical. Anterior chamber inflammation and exudative retinal detachment (RD) were the most common clinical signs and early appearance of nummular scars was seen in most patients. Postsurgical SO patients had poorer outcomes as compared to posttraumatic SO patients.

**Conclusions:** Early recognition of signs of SO in pediatric patients with timely management can help in not only salvaging the sympathizing eyes but may also aid in visual rehabilitation of inciting eyes.

### Retina (Medical)

**Dec 08, 2017 (Fri) 08:30 - 10:00**

**Venue: Room 304 & 305**

### 1-Year Outcomes of Ranibizumab 0.5 mg in Treatment-Naive Asian Patients With Polypoidal Choroidal Vasculopathy: Results From the Real-World LUMINOUS Study

*First Author: Adrian KOH*

*Co-Author(s): Timothy LAI, Wayne MACFADDEN, Philippe MARGARON, Kalpesh PRAJAPATI*

**Purpose:** LUMINOUS (NCT01318941) was designed to evaluate the long-term effectiveness, safety, and treatment patterns with ranibizumab 0.5 mg in routine clinical practice across all approved indications. We present the baseline characteristics and 1-year outcomes of ranibizumab treatment in treatment-naive neovascular age-related macular degeneration (nAMD) patients of Asian descent with or without polypoidal choroidal vasculopathy (PCV), a frequent subtype in nAMD, enrolled in LUMINOUS.

**Methods:** This 5-year global observational study recruited over 30,000 patients who were treated as per the local ranibizumab label. Patients with nAMD were categorized as PCV or non-PCV based on the presence of lesions at baseline, as reported by the investigators.

**Results:** Among the treatment-naive nAMD patients of Asian descent, 421 had PCV and 1396 were without PCV. At baseline, for PCV/non-PCV patients, mean age was 72.5/71.8 years, 67.5/59.8% were male, and mean visual acuity (VA, letters) was 54.9/46.3, respectively. At 1 year, in PCV and non-PCV patients, mean VA improved by 6.3 (baseline, 57.5; n = 186) and 4.8 (baseline, 51.8; n = 483), with a mean of 3.4 and 2.9 ranibizumab injections and 7.3 and 6.0 visits, respectively. Adverse events (AEs) such as retinal and vitreous hemorrhage occurred in 1 (0.238%)/4 (0.287%) patients and 1 (0.238%)/1 (0.072%) patient in the PCV/non-PCV groups, respectively. A single case of vitreous hemorrhage was reported as a serious







AE in the non-PCV group.

**Conclusions:** LUMINOUS confirmed the benefits of ranibizumab in treatment-naive Asian patients with nAMD, with similar visual outcomes regardless of the PCV status at 1 year. No new safety findings were identified.

Dec 08, 2017 (Fri) 08:30 - 10:00

Venue: Room 304 & 305

### 5-Year Outcomes of Polypoidal Choroidal Vasculopathy in Unaffected Fellow Eyes

First Author: Eung Suk **KIM**

Co-Author(s): Do-Gyun **KIM**, Jae Min **KIM**, Seung Young **YU**

**Purpose:** To evaluate the incidence of polypoidal choroidal vasculopathy (PCV) or choroidal neovascularization (CNV) in the fellow eyes of patients with unilateral PCV and to identify the ocular risk factors related to the development of neovascular changes in the fellow eyes of patients with unilateral PCV.

**Methods:** We retrospectively reviewed the medical records of 48 patients with unilateral PCV, all of whom had completed at least 60 months of follow-up. The angiographic features were evaluated including the development of active PCV over time, choroidal vessel dilation, choroidal vascular hyperpermeability, and branching vascular network (BVN) on indocyanine green angiography (ICGA).

**Results:** The mean follow-up period was  $73.10 \pm 14.33$  months. The development of active PCV and CNV was noted in 8 fellow eyes (17%). The presence of choroidal thickness  $> 200 \mu\text{m}$  ( $P = 0.002$ ), irregular retinal pigment epithelium (RPE) elevation ( $P < 0.001$ ), choroidal vascular dilation ( $P < 0.001$ ), choroidal vascular hyperpermeability ( $P < 0.001$ ), and BVN ( $P < 0.001$ ) in the fellow eye had statistically significant correlations with development of PCV (examined with Fisher exact test). In multivariate regression, BVN on IGGA [ $P = 0.045$ , odds ratio (OR) = 24.66] in the fellow eye was a significant risk factor for the development of PCV or CNV (examined

with logistic regression).

**Conclusions:** PCV or CNV developed in 17% of fellow eyes during the follow-up period ( $\geq 60$  months). Because BVN on IGGA in the fellow eye was a significant risk factor for the development of PCV or CNV, PCV patients with contralateral BVN are recommended close follow-up for future development of PCV or CNV in fellow eyes.

Dec 08, 2017 (Fri) 08:30 - 10:00

Venue: Room 304 & 305

### Analysis of HtrA1/ARMS2 and CFH Gene Polymorphisms With Susceptibility to Neovascular Age-Related Macular Degeneration in Yogyakarta Indonesia: Preliminary Data

First Author: Supanji **SUPANJI**

Co-Author(s): Angela **AGNI**, Dewi **ROMDHONIYAH**, Muhammad **SASONGKO**, Firman **WARDHANA**, Tri **WIDAYANTI**

**Purpose:** It has been demonstrated that genetic factors play an important role in the etiology of neovascular age-related macular degeneration (nAMD). This study analyzed the polymorphisms of HtrA1 rs10490924, ARMS2 In/Del sites, and CFH rs1061170 in the population of Yogyakarta, Indonesia in order to determine the disease risk conferred by these factors.

**Methods:** This was a case control study involving 63 nAMD patients and 32 matched non-AMD (healthy) subjects. After clinical examination by a vitreoretinal specialist, information related to medical history was collected along with blood samples. The genomic DNA samples were genotyped for the representative single nucleotide polymorphisms (SNPs) by allele-specific digestion of PCR products.

**Results:** The allelic frequencies complied with Hardy-Weinberg equilibrium. An odds ratio of 3.09 (95% CI: 1.65–5.77,  $P < 0.0001$ ), 3.72 (95% CI: 1.98–6.99,  $P < 0.0001$ ), and 1.09 (95% CI: 0.44–2.69,  $P = 0.848$ ) was obtained for risk allele carriers with TT genotype in HtrA1





promoter, TT genotype in the ARMS2, and CC genotype in CFH Y402H. The joint risk analysis of TT genotype interaction in HtrA1 promoter and ARMS2 was 3.51 for odds ratio (95% CI: 1.85–6.64,  $P < 0.0001$ ). The odds ratio for gene interaction of TT genotype in HtrA1, ARMS2, and CC genotype in CFH Y402H was 3.55 (95% CI: 0.82–15.3,  $P = 0.089$ ).

**Conclusions:** The results of our study indicate that both independently and the interaction of HtrA1/ARMS2 polymorphisms are associated with the risk of developing nAMD. CFH polymorphisms independently and the interaction between CFH and HtrA1/ARMS2 genotypes were not significantly associated with nAMD.

**Dec 08, 2017 (Fri) 14:00 - 15:30**

**Venue: Room 304 & 305**

### Characteristics of Optical Coherence Tomography in Central Serous Chorioretinopathy

*First Author: Rinku PAUL*

*Co-Author(s): Dipak NAG, Pankaj ROY*

**Purpose:** To report the morphological changes seen in the retinal pigment epithelium (RPE) in the symptomatic eyes of patients with idiopathic central serous chorioretinopathy (CSR).

**Methods:** In this study 20 consecutive patients with unilateral CSR underwent spectral-domain optical coherence tomography (SD-OCT) scans for affected symptomatic eyes. Three-dimensional single-layer RPE map was studied in eyes for morphological alterations, and findings were correlated with clinical presentation. OCT was performed corresponding to the site of leaking on fundus fluorescein angiography (FFA) or centered in the fovea using macular cube 512 × 128 for documentation of RPE morphological changes.

**Results:** Eighteen (90%) eyes showed defect in the RPE layer. Four different patterns of distinct RPE changes were found in OCT. In the first category, bulges of RPE characteristic of

pigment epithelial detachment (PED) were seen in 8 (40%) patients. In the second pattern, an irregular appearance in RPE, a typical feature of "sick RPE," was found in 6 (30%) patients. The third variety characterized by RPE hypertrophy and protrusion were seen in 4 (20%) and the fourth group showed no remarkable changes in RPE in 2 (10%) patients. Two patients who had chronic or recurrent CSR had sick RPE. Two patients came for follow-up and OCT showed that, even after resolution of fluid, there was persistence of PED.

**Conclusions:** Spectral-domain optical coherence tomography showed morphologic alterations in retinal pigment epithelium in eyes of patients with idiopathic central serous chorioretinopathy and offers a new approach to understand the pathology and to predict the prognosis of the disease.

**Dec 08, 2017 (Fri) 08:30 - 10:00**

**Venue: Room 304 & 305**

### Choroidal Vasculature Under Pigment Epithelial Detachment in Polypoidal Choroidal Vasculopathy and Age-Related Macular Degeneration

*First Author: Danny NG*

*Co-Author(s): Malini BAKTHAVATSALAM, Marten BRELEN, Timothy LAI, Chi Wai TSANG*

**Purpose:** To quantitatively assess the proportion of choroidal vasculature underlying pigment epithelial detachment (PED) in polypoidal choroidal vasculopathy (PCV) and age-related macular degeneration (AMD).

**Methods:** A total of 105 consecutive eyes of 75 patients with PED due to PCV or AMD had multimodal imaging including fluorescence (FA) and indocyanine green angiography (ICGA), swept source optical coherence tomography (SS-OCT), and OCT angiography (OCTA). Choroidal thickness (CT) and choroidal vascularity index (CVI), defined as ratio of luminal area over the specified choroidal area in the subfoveal (SF) region or under the PED, were computed from OCT binarized images.





**Results:** The mean SFCT for 25 neovascular AMD eyes ( $142.80 \pm 56.54 \mu\text{m}$ ) was significantly thinner than the 50 PCV eyes ( $223.12 \pm 96.65 \mu\text{m}$ ,  $P < 0.01$ ) and 50 healthy eyes from normal controls ( $221.17 \pm 43.70 \mu\text{m}$ ,  $P < 0.01$ ). The SFCVI for AMD eyes ( $60.28 \pm 4.69\%$ ) and PCV eyes ( $63.64 \pm 5.27\%$ ) were both significantly reduced compared with controls ( $66.77 \pm 11.44\%$ ,  $P < 0.01$  and  $P = 0.01$ , respectively). When comparing the measurements within the eyes with an eccentric PED, the mean CT and CVI under the PED were significantly higher than SFCT ( $219.16 \pm 90.56 \mu\text{m}$  vs  $180.20 \pm 92.74 \mu\text{m}$ ,  $P < 0.01$ ) and SFCVI ( $66.07 \pm 5.67\%$  vs  $62.09 \pm 5.26\%$ ,  $P < 0.01$ ). There were more PCV eyes than AMD eyes (39 vs 11) that had an eccentric PED.

**Conclusions:** Regional increases in CT and CVI may occur under the PED, and measurements only in the subfoveal region can underestimate the severity of choroidal morphological changes.

Dec 08, 2017 (Fri) 08:30 - 10:00

Venue: Room 304 & 305

### Comparison of Ranibizumab and Aflibercept in Patients With Neovascular Age-Related Macular Degeneration Treated Following a "Treat and Extend" Protocol: Efficacy Variables From the Prespecified 12-Month Interim Analysis of the RIVAL Study

First Author: Ian **MCALLISTER**

Co-Author(s): Jennifer **ARNOLD**, Mark **GILLIES**, Robyn **GUYMER**, Alex **HUNYOR**, Francois **PECHEUR**

**Purpose:** To report results of the prespecified 12-month interim analysis of key secondary endpoints from the RIVAL study: number of injections and change in best corrected visual acuity (BCVA) from baseline at month 12. The study's primary endpoint will compare the rate of development of geographic atrophy at 24 months in neovascular age-related macular degeneration (nAMD) patients treated with 0.5 mg ranibizumab (RBZ) and 2.0 mg aflibercept (AFL) using a "treat and extend" regimen (T&E).

**Methods:** RIVAL is a 24-month, randomized,

partially masked, multicenter phase IV study. A total of 281 eyes were randomized 1:1 to RBZ or AFL arms. Following 3 initial monthly injections, patients entered the T&E phase.

**Results:** A total of 278 patients ( $n = 141$  RBZ;  $n = 137$  AFL) were included in the interim analysis. Demographics and baseline characteristics were comparable between the 2 arms. The mean BCVA at baseline was 65.3 letters (RBZ) vs 65.1 letters (AFL). At month 12, the mean BCVA for completers was 72.9 letters for RBZ ( $n = 127$ ) and 70.5 letters for AFL ( $n = 121$ ). When applying a random effects mixed model, the change from baseline at month 12 was assessed to be  $+7.14$  (95% CI: 5.45-8.83) for RBZ and  $+4.85$  (95% CI: 3.13-6.57) for AFL (treatment effect: 2.29 letters;  $P = 0.063$ ). The mean number of injections over 12 months was 9.7 injections in both arms.

**Conclusions:** This preplanned interim analysis of key secondary endpoints from the RIVAL study showed that significant visual improvements were achieved at 12 months with both ranibizumab and aflibercept in nAMD patients, with a similar number of injections using a T&E regimen.

Dec 08, 2017 (Fri) 14:00 - 15:30

Venue: Room 304 & 305

### Disorganization of Retinal Inner Layers and Ellipsoid Zone Disruption Predict Vision Outcomes in Central Retinal Vein Occlusion Macular Edema

First Author: Errol **CHAN**

Co-Author(s): John **CHEN**, Mohab **ELDEEB**, Amer **OMAR**, Vincent **SUN**

**Purpose:** To determine if early changes in spectral domain optical coherence tomography (SD-OCT) parameters predict 1-year visual acuity (VA) in macular edema secondary to nonischemic central retinal vein occlusion.

**Methods:** Longitudinal cohort study of 91 participants. Two independent masked graders assessed SD-OCT parameters in the central 1500  $\mu\text{m}$  foveal zone at baseline and 3 months





for disorganization of retinal inner layers (DRIL), ellipsoid zone (EZ) and external limiting membrane (ELM) disruption, cone outer segment tips (COST) visibility, and cysts.

**Results:** In multivariate analyses, 1-year interval increases in DRIL (point estimate, 0.06; 95% CI, 0.03 to 0.09 per 100  $\mu\text{m}$ ;  $P < 0.001$ ) and EZ disruption (0.07; 95% CI, 0.01 to 0.13 per 100  $\mu\text{m}$ ;  $P = 0.023$ ), and decreased visible COST (-0.09; 95% CI, -0.16 to -0.02 per B-scan;  $P = 0.018$ ) correlated with VA worsening over 1 year. Early 3-month changes in DRIL (0.05; 95% CI, 0.02 to 0.08 per 100  $\mu\text{m}$ ;  $P = 0.003$ ) and EZ disruption (0.10; 95% CI, 0.07 to 0.13 per 100  $\mu\text{m}$ ;  $P < 0.001$ ) predicted VA worsening over 1 year, corresponding to VA worsening of 1 line for worsening of every DRIL 250  $\mu\text{m}$  or 125  $\mu\text{m}$  of EZ disruption. DRIL improvement and worsening  $\geq 250$   $\mu\text{m}$  in the first 3 months predicted 1-line VA change probabilities of 69% for improvement and 87.5% for worsening, respectively. Improvement and worsening of EZ disruption  $\geq 250$   $\mu\text{m}$  was associated with 81% and 67.5% probabilities for 1-line VA improvement and worsening, respectively.

**Conclusions:** Early changes in DRIL and EZ disruption are independently associated with 1-year VA outcomes, indicating potential for further evaluation as prognostic variables.

**Dec 08, 2017 (Fri) 14:00 - 15:30**

**Venue: Room 304 & 305**

### Efficacy of Primary Intravitreal Ranibizumab for Treatment of Retinopathy of Prematurity in China

*First Author: Jing FENG*

*Co-Author(s): Yanrong JIANG*

**Purpose:** To evaluate the efficacy of low-dose intravitreal ranibizumab (IVR) in patients with retinopathy of prematurity (ROP).

**Methods:** A total of 629 eyes of 331 premature infants with high-risk type 1 prethreshold or threshold ROP were included. All of the participants were treated with IVR at an initial dose of 0.25 mg/0.025 mL. Outcome measures included ROP regression and recurrence.

All treated infants had at least 6 months of follow-up and were examined until total ROP regression had occurred.

**Results:** Complete resolution of ROP occurred in 384 (61.0%) eyes. However, ROP recurrence occurred in 245 (39.0%) eyes at  $8.57 \pm 3.73$  weeks after initial treatment. A comparison of the completely cured eyes with the recurrent ROP eyes showed significant differences with regard to postmenstrual age (PMA) ( $38.65 \pm 11.59$  weeks vs  $37.57 \pm 18.09$  weeks, respectively,  $P = 0.001$ ) and chronological age (CA) ( $8.84 \pm 3.96$  weeks vs  $8.00 \pm 3.31$  weeks, respectively,  $P = 0.007$ ). Significant treatment effects were also observed with regard to type 1 prethreshold ROP (84.1%), but not for aggressive posterior ROP (33.3%,  $P < 0.001$ ), and for zone II ROP (69.0%) but not for zone I ROP (38.4%,  $P < 0.001$ ). Retreated eyes were primarily administered laser therapy (145 eyes, 58.7%). After a maximum of 3 treatments, all of the eyes attained anatomic success. The mean number of IVR injections was  $1.20 \pm 0.49$ . Macular dragging left occurred in 4 eyes.

**Conclusions:** IVR monotherapy shows a significant benefit in the treatment of ROP, but recurrence of ROP after initial treatment is common, so increased monitoring and close follow-up should be implemented. The recurrence is associated with ROP classification.

**Dec 08, 2017 (Fri) 08:30 - 10:00**

**Venue: Room 304 & 305**

### Evaluation of Polyp Status and Predictors of Complete Polyp Regression Over 12 Months in the EVEREST II Study

*First Author: Colin TAN*

*Co-Author(s): Tadhg GUERIN, Tock Han LIM, Philippe MARGARON*

**Purpose:** To evaluate polyp status and potential predictors of complete polyp regression (CPREG) in EVEREST II.

**Methods:** EVEREST II was a 24-month, multicenter study in which 322 patients diagnosed with symptomatic polypoidal





choroidal vasculopathy were randomized 1:1 to receive ranibizumab 0.5 mg plus verteporfin photodynamic therapy (n = 168) or ranibizumab 0.5 mg monotherapy (n = 154). Presence and size of polyps were assessed using indocyanine green angiography (ICGA) by the Fundus Image Reading Center at baseline, months 3, 6, and 12. Predictors of CPREG at month 12 were studied by backward selection multiple logistic regression using demographic, ocular, anatomic, and angiographic parameters in 2 separate models that used either the baseline predictors or on-treatment predictors at month 3.

**Results:** Baseline ICGA characteristics were comparable between both treatment groups. At month 3, 71.4% of patients treated with combination therapy achieved CPREG that remained stable at months 6 and 12 (71.3% and 69.7%, respectively). In the ranibizumab monotherapy group, the proportion increased from 23.3% at month 3 to 28.0% and 33.8% at months 6 and 12, respectively. Treatment with combination therapy [odds ratio (OR), 4.60 (baseline model) and 2.25 (month 3 model)], absence of pulsation of nodule at baseline (OR, 2.67), and CPREG at month 3 (OR, 0.15) were associated with a higher probability of CPREG at month 12.

**Conclusions:** At month 12, treatment with combination therapy was associated with higher probability of achieving CPREG than ranibizumab monotherapy. The results contribute to the further understanding of the response of PCV-associated polyps to ranibizumab with or without vPDT.

Dec 08, 2017 (Fri) 14:00 - 15:30

Venue: Room 304 & 305

### Gender Variations in Central Serous Chorioretinopathy

First Author: Sankeert **GANGAKHEDKAR**  
Co-Author(s): Alay **BANKER**, Daniel **CHERFAN**, Jay **CHHABLANI**, Felipe **FERREIRA**, Daren **HANUMUNTHADU**

**Purpose:** Comparison of presentation and

outcomes of central serous chorioretinopathy (CSC) between age-matched male and female subjects.

**Methods:** This retrospective analysis included demographics details, clinical presentations, imaging features, and treatment outcomes of subjects with CSC. Statistical analyses included Mann-Whitney and Fisher exact test.

**Results:** A total of 83 males and 105 females, with mean age of  $41.7 \pm 8.1$  and  $55.5 \pm 12.0$  years ( $P = 0.08$ ), respectively, were included. Subretinal deposits on optical coherence tomography were higher in females ( $P < 0.001$ ); however, pigment epithelial detachment and hyperreflective foci were more common in males ( $P < 0.005$ ). Diffuse leakage and pigment epithelium tracts on angiography were common in males ( $P = 0.01$  and  $P = 0.0015$ ) and point leakage in females ( $P = 0.001$ ). Visual outcomes at 1 year were better in females ( $P = 0.002$ ).

**Conclusions:** Females with CSC appear to have better outcomes, with less chance of diffuse RPE damage compared to males.

Dec 08, 2017 (Fri) 11:00 - 12:30

Venue: Room 304 & 305

### Gli1 Expression in Human Epiretinal Membranes

First Author: Sohee **JEON**  
Co-Author(s): Won Ki **LEE**

**Purpose:** To evaluate the expression of Gli1 in human epiretinal membranes (ERM) and to correlate this with clinical data.

**Methods:** We prospectively recruited patients with ERM. Thirty-three human ERM specimens were immunolabeled with anti-Gli1 antibody and the number of total cells/hyperfield (HF), Gli1 (+) cells/HF, and the percentage of Gli1 (+) cells/total cells were calculated. We evaluated the interrelationship of cellular properties and clinical findings, such as presence of diabetic retinopathy (DR), retinal breaks, intraocular inflammation, central foveal thickness, maximal retinal thickness, retinal contraction, lamellar holes, pseudoholes, the attenuation or absence





of an inner segment/outer segment (IS/OS) junction/external limiting membrane (ELM), cystic changes, and paravascular inner retinal defects.

**Results:** Among 33 specimens, 25 specimens (75.8%) showed nuclear Gli1 expression. The mean Gli1 (+) cells/total cells was  $54.0 \pm 36.7\%$  (range, 0–92.8%). There was significantly higher expression of Gli1 (+) cells in ERM specimens from patients with DR ( $P = 0.014$ ) and lower expression from patients with retinal breaks ( $P = 0.022$ ). ERM specimens from patients with alteration of IS/OS junction/ELM or cystic changes on optical coherence tomography (OCT) showed higher percentage of Gli1(+) cells/total cells.

**Conclusions:** Gli1 expression was detected in most ERM specimens. Patients who had DR or OCT findings indicating chronic retinal insults showed higher Gli1 expression. Gli1 may have a role in the pathogenesis of ERM after chronic retinal insults.

**Dec 08, 2017 (Fri) 08:30 - 10:00**

**Venue: Room 304 & 305**

### **Incidence and Risk Factors of Massive Subretinal Hemorrhage in Retinal Angiomatous Proliferation**

*First Author: Jae Hyung LEE*

*Co-Author(s): Mee Yon LEE, Won Ki LEE*

**Purpose:** To evaluate the incidence and associated risk factors of massive subretinal hemorrhage (SRH) in patients with retinal angiomatous proliferation (RAP).

**Methods:** A total of 187 eyes of 135 treatment-naive patients diagnosed with RAP were evaluated retrospectively. Clinical records including the time between the initial visit, last anti-vascular endothelial growth factor (VEGF) treatment, last stable examination, and the date of massive SRH were reviewed. Imaging findings including indocyanine green angiography (ICGA) and optical coherence tomography (OCT) were analyzed.

**Results:** Massive SRH developed in 18 eyes

(9.6%) a median of 20 months after the initial presentation. Kaplan-Meier survival analysis revealed that the incidence (2.8, 5.8, 13.1, and 21.0% after 1, 2, 5, and 10 years, respectively) continuously increased. Among 14 eyes with discernible vascular anastomosis on baseline ICGA, 13 (92.8%) showed retinal arteriole involvement. On spectral-domain OCT imaging of the last visit prior to the massive SRH, a layered lamellar tissue complex was noted under the retinal pigment epithelium in 9 of 13 eyes, which was significantly associated with massive SRH [hazard ratio (HR), 5.883;  $P = 0.010$ ]. The average time between the last stable examination/last injection and the massive SRH was 2 and 5 months, respectively. The patients were treated with anti-VEGF, gas, and recombinant tissue plasminogen activator injection; however, all except 1 eye had visual acuity worse than 20/1000 at the final visit.

**Conclusions:** Massive SRH can occur in RAP in the course of anti-VEGF treatment, resulting in severe vision loss. A proactive dosing regimen may be more appropriate for these RAP eyes.

**Dec 08, 2017 (Fri) 14:00 - 15:30**

**Venue: Room 304 & 305**

### **Outcomes of Telescreening for Retinopathy of Prematurity in Rural South India**

*First Author: Venkatapathy NARENDRAN*

*Co-Author(s): Parag SHAH*

**Purpose:** To report the outcomes of retinopathy of prematurity (ROP) telescreening carried out in rural parts of South India.

**Methods:** The ROP telescreening team consisted of a manager, 2 nurses trained in taking the digital images using Retcam Shuttle and uploading them to a secure server using wireless internet, a driver responsible for taking the team along with the Retcam Shuttle in a customized van from the base hospital to the neonatal units, and a remote ROP expert at the base hospital to grade the images and send reports. The geographical area covered was a radius of around 250 km from Coimbatore city covering 2 states of Tamilnadu and Kerala





across 12 districts.

**Results:** From August 12, 2015 till May 14, 2017, 7299 babies were screened (4234 new plus 3065 review). Any stage ROP was seen in 1431 babies. One hundred eleven babies (213 eyes) were identified with vision threatening ROP and appropriate treatment was given; 76 were males (68.5%). The mean gestational age and birth weight of the treated babies was 30 weeks and 1269 g, respectively. Laser was given in 129 eyes, intravitreal Avastin injection in 78 eyes, and Lucentis injection in 6 eyes. Vitrectomy (in addition to laser) was performed in 4 eyes. To increase ROP awareness, continuous medical education programs were held every 6 weeks and 718 neonatal staff were made aware of ROP screening.

**Conclusions:** There is a large lacuna in providing ROP screening services in rural India.

Dec 08, 2017 (Fri) 08:30 - 10:00

Venue: Room 304 & 305

### Polypoidal Choroidal Vasculopathy Subtypes and the Angiographic Factors Affecting Long-Term Visual Outcomes

First Author: Colin **TAN**

Co-Author(s): Louis **LIM**, Tock Han **LIM**, Wei Kiong **NGO**

**Purpose:** Polypoidal choroidal vasculopathy (PCV) has high prevalence among Asians, with variable clinical course and visual prognosis, suggesting the existence of clinical subtypes. We describe a novel classification system for PCV and correlate it with long-term visual outcomes.

**Methods:** Study of 107 consecutive patients with PCV presenting over a 24-month period. Patients were imaged using confocal scanning laser ophthalmoscopy fluorescein angiography (FA) and indocyanine green angiography (ICGA). Color fundus photographs and angiograms were graded independently by 2 ophthalmologists. The diagnosis of PCV was made using standardized diagnostic criteria. The angiographic features were used to classify

the PCV cases, and this was correlated with clinical presentation and visual acuity (VA) for 5 years.

**Results:** Of the 107 patients, significant FA leakage was observed in 57 patients (53.3%). Patients with FA leakage had significantly worse logarithm of the minimum angle of resolution (logMAR) VA at all time points compared with those without leakage (logMAR 1.04 vs 0.32 at 5 years,  $P < 0.001$ ) and experienced higher rates of moderate visual loss (60% vs 0%,  $P < 0.001$ ). Those without FA leakage experienced higher rates of good visual acuity ( $\geq 20/40$ ) (74.4% vs 19.6%,  $P < 0.001$ ) at all follow-up visits.

**Conclusions:** We have established a novel classification system for PCV using FA and ICGA features. The visual outcomes vary with subtype, demonstrating that PCV consists of distinct, previously unrecognized clinical subtypes instead of a single disease entity as originally believed. This classification system has potential application in clinical practice and multicenter randomized trials.

Dec 08, 2017 (Fri) 08:30 - 10:00

Venue: Room 304 & 305

### RG7716: A Novel Bispecific Anti-VEGF/ Anti-Angiopoietin-2 Monoclonal Antibody for Neovascular Age-Related Macular Degeneration and Diabetic Macular Edema

First Author: Timothy **LAI**

Co-Author(s): Patrick **CECH**, Jayashree **SAHNI**, Dietmar **SCHWAB**, Piotr **SZCZESNY**, Robert **WEIKERT**

**Purpose:** To report the design, binding properties, preclinical, and clinical outcomes of the novel bispecific antibody RG7716 that simultaneously inhibits VEGF-A and angiopoietin-2 (Ang2).

**Methods:** Review of data from preclinical studies of RG7716 and a phase 1 clinical trial in patients with refractory neovascular age-related macular degeneration (AMD).

**Results:** Both VEGF-A and Ang2 levels are elevated in the vitreous of patients with





neovascular AMD and diabetic macular edema (DME). Elevated Ang2 levels displace Ang1, the angiopoietin responsible for maintaining healthy and mature vessels, leading to vessel destabilization and retinal edema. Surface plasmon resonance binding studies established that RG7716 simultaneously neutralizes both VEGF-A and Ang2. Endothelial hyperpermeability models showed that RG7716 completely reverses endothelial barrier breakdown. A phase 1 clinical trial in patients with refractory neovascular AMD with a mean disease duration of 2.9 years demonstrated that monthly doses of 6 mg RG7716 for 3 months resulted in a favorable safety and tolerability profile with evidence of visual and anatomical improvements. At 3 months, the median best-corrected visual improvement was 7.5 letters and the median central subfield thickness reduction on optical coherence tomography was 117  $\mu\text{m}$  in these refractory neovascular AMD eyes.

**Conclusions:** RG7716 simultaneously neutralizes both Ang2 and VEGF with high affinity. RG7716 was well tolerated with an overall favorable safety profile in patients with neovascular AMD. Based on the preclinical data and phase 1 findings, 3 phase 2 studies, AVENUE (NCT02484690), BOULEVARD (NCT02699450), and STAIRWAY (NCT03038880), are currently underway to further assess the efficacy, safety, and durability of RG7716 in patients with both neovascular AMD and DME.

**Dec 08, 2017 (Fri) 08:30 - 10:00**

**Venue: Room 304 & 305**

### **Randomized, Open-Label Study to Evaluate 2 Intravitreal Aflibercept Treat-and-Extend Dosing Regimens in Wet Age-Related Macular Degeneration: 52-Week Outcomes From ALTAIR**

*First Author: Masahito OHJI*

*Co-Author(s): Masato KOBAYASHI, Annabelle A OKADA, Kanji TAKAHASHI, Yasuhiro TERANO*

**Purpose:** To evaluate 2 intravitreal aflibercept

(IVT-AFL) treat-and-extend (T&E) dosing regimens in wet age-related macular degeneration (wAMD).

**Methods:** ALTAIR (NCT02305238) was a 96-week, randomized, open-label, phase 4 study conducted at 40 sites across Japan. Patients received 3 monthly doses of IVT-AFL before randomization (1:1) at week 16 to IVT-AFL with a 2-week (IVT-AFL-2W) or 4-week (IVT-AFL-4W) adjustment. Primary endpoint was mean change in best-corrected visual acuity [BCVA; Early Treatment Diabetic Retinopathy Study (ETDRS) letters] from baseline to week 52. Other endpoints included the proportion of patients losing <15 ETDRS letters, mean change in central retinal thickness (CRT), and treatment-emergent adverse events (TEAEs) at week 52.

**Results:** A total of 254 Japanese patients were included in safety analyses and 246 patients were included in efficacy analyses. Baseline BCVA was 54.8 (IVT-AFL-2W) and 55.3 (IVT-AFL-4W) ETDRS letters. Mean change in BCVA from baseline to week 52 was 9.0 (IVT-AFL-2W) versus 8.4 (IVT-AFL-4W) ETDRS letters. Proportion of patients losing <15 ETDRS letters was 96.7% (IVT-AFL-2W) versus 95.9% (IVT-AFL-4W). Mean change in CRT was -134.4 (IVT-AFL-2W) versus -126.1 (IVT-AFL-4W)  $\mu\text{m}$ . Mean number of injections was 7.2 (IVT-AFL-2W) and 6.9 (IVT-AFL-4W). Mean injection interval (weeks 16–52) was 10.0 (IVT-AFL-2W) and 10.9 (IVT-AFL-4W). The most common ocular TEAEs were conjunctival hemorrhage (2.4%) and retinal pigment epithelial tear (2.4%) (IVT-AFL-2W) and conjunctival hemorrhage (5.7%) (IVT-AFL-4W).

**Conclusions:** Both IVT-AFL T&E regimens improved visual and anatomical outcomes at week 52 with extended dosing intervals in wAMD patients. Ocular TEAEs were consistent with the known safety profile of IVT-AFL.





Dec 08, 2017 (Fri) 14:00 - 15:30

Venue: Room 304 & 305

**Relationship Between Microvascular Abnormalities on Optical Coherence Tomography Angiography and Microstructure in Eyes With Branch Retinal Vein Occlusion**

First Author: Takeshi IWASE

Co-Author(s): Eimei RA, Hiroko TERASAKI, Kentaro YAMAMOTO, Shunsuke YASUDA

**Purpose:** To investigate microvascular changes in the superficial capillary plexus (SCP) and deep capillary plexus (DCP) in eyes with resolved branch retinal vein occlusion (BRVO) and their association with best-corrected visual acuity (BCVA).

**Methods:** Seventy-five eyes ( $64.3 \pm 11.2$  years old) with BRVO after resolution of macular edema were retrospectively evaluated. All patients underwent optical coherence tomography angiography (OCTA) for assessment of microvascular changes and spectral-domain OCT for assessment of structural changes at the fovea. The areas of vascular perfusion and foveal avascular zone (FAZ) in the SCP and DCP were quantitatively evaluated. Best-corrected visual acuity was measured on the same day as OCTA and SD-OCT examination. The correlation between BCVA and OCTA and SD-OCT findings was assessed.

**Results:** The mean FAZ areas of the SCP and DCP were  $0.47 \pm 0.31$  and  $0.59 \pm 0.14$  mm<sup>2</sup> in eyes with BRVO and  $0.33 \pm 0.14$  and  $0.46 \pm 0.13$  mm<sup>2</sup> in the fellow eyes, respectively. Better BCVA was significantly associated with a smaller FAZ area in the SCP ( $P = 0.029$ ) and DCP ( $P = 0.006$ ). Better BCVA was significantly associated with a longer external limiting membrane (ELM)-ellipsoid zone (EZ) thickness ( $P < 0.001$ ) and EZ-retinal pigment epithelium (RPE) thickness ( $P < 0.001$ ). Stepwise multiple regression analysis revealed that EZ-RPE thickness was the most important parameter significantly correlated with BCVA ( $P < 0.001$ ).

**Conclusions:** The foveal microstructure is

more crucial for better visual function than the expansion of FAZ in eyes with BRVO.

Dec 08, 2017 (Fri) 14:00 - 15:30

Venue: Room 304 & 305

**Retinopathy of Prematurity: Incidence, Risk Factors, and Evaluation of Screening Criteria in a Northeast China Population**

First Author: Ma XIANG

Co-Author(s): Shen LING, Xiang NIAN, Fang SIWEN, Diao YUNBO, Cheng XIAN

**Purpose:** To investigate the incidence of retinopathy of prematurity (ROP) and the relationship between risk factors and disease in premature newborns in the southern area of Liaoning Province (Northeast China).

**Methods:** A total of 1219 premature subjects were retrospectively evaluated. Demographic information, clinical data, and risk factors were reviewed.

**Results:** The gestational age (GA) of the infants included was  $\leq 37$  weeks, and the birth weight was  $< 2000$  g. The incidence of ROP was 13.5% (156) in preterm infants: 56 had stage 1 (35.9%), 42 had stage 2 (26.9%), 48 had stage 3 (30.7%), 7 had stage 4 (4.5%), 3 had stage 5 (1.9%), and 11 had plus (+) disease (7.1%). The risk factors recorded associated with ROP included GA, birth weight, gender, ventilation treatment, test-tube baby, oxygen support, natural labor or caesarean section, hypoxic encephalopathy, neonatal hyaline membrane disease, pneumonia, bronchopulmonary dysplasia (BPD), maternal preeclampsia, blood transfusion, septicemia, necrotizing enterocolitis (NEC), patent ductus arteriosus (PDA), respiratory distress syndrome (RDS), and asphyxia.

**Conclusions:** In this study, low birth gestational age, low birth weight, oxygen intake history, multiple births, ventilation treatment, BPD, maternal preeclampsia, blood transfusion history, septicemia, NEC, PDA, RDS, and asphyxia were important risk factors for the development of ROP.



Dec 08, 2017 (Fri) 14:00 - 15:30

Venue: Room 304 & 305

### Rupture of Choriocapillario-Bruch Membrane-Retinal Pigment Epithelium Complex Originating in Lacquer Crack Leads to Simple Subretinal Bleeding in High Myopia

First Author: Lan MI

**Purpose:** To determine whether a rupture of choriocapillario-Bruch membrane-retinal pigment epithelium complex (CBRC) existed underlying subretinal hemorrhage in highly myopic eyes without choroidal neovascularization (CNV) and to analyze the relationship between hemorrhage and lacquer crack.

**Methods:** Fifteen eyes with fresh subretinal hemorrhage within a week in highly myopic patients [refractive error  $\leq -6$  diopters (D) or axial length  $\geq 26$  mm] were included. All patients underwent a complete ocular examination as well as best-corrected visual acuity (BCVA) with Snellen charts, measurement of axial length, dilated fundus examination, fundus photography, fundus fluorescein angiography (FFA), indocyanine green angiography (ICGA), and spectral domain optical coherence tomography (SD-OCT) at initial visit.

**Results:** There were altogether 15 subretinal hemorrhages detected; among them, 11 hemorrhages covered the central fovea. FFA showed persistent blocked fluorescence from subretinal hemorrhage. One or more hypofluorescence of lacquer cracks were observed within the bleeding area and no hyperfluorescence or dye leakage was found during the ICGA imaging process in all eyes. SD-OCT showed subretinal hyperscattering signal with or without invasion of the hemorrhage into the adjacent retinal layer. A focal rupture of CBRC appearing as a volcanic crater shape was observed underlying each bleeding lesion. The mean maximum width of rupture was  $75.60 \pm 23.85 \mu\text{m}$ , ranging from  $39 \mu\text{m}$  to  $104 \mu\text{m}$ . All the ruptures of CBRC captured by SD-OCT were found exactly

located in the hypofluorescence of lacquer cracks on ICGA.

**Conclusions:** Ruptures of CBRC originating in lacquer cracks could be detected by SD-OCT in fresh subretinal hemorrhages in high myopia without CNV, which further demonstrates that lacquer crack is essential for simple bleeding.

Dec 08, 2017 (Fri) 14:00 - 15:30

Venue: Room 304 & 305

### Serum Aldosterone Levels in Central Serous Chorioretinopathy Patients

First Author: Yuying JI

Co-Author(s): Nanying LIAO, Feng WEN, Xiongze ZHANG

**Purpose:** To investigate the serum aldosterone levels in central serous chorioretinopathy (CSC) patients and its relationship with the disease.

**Methods:** Both acute and chronic CSC patients defined by fundus fluorescein angiography (FFA) and optical coherence tomography (OCT) were enrolled from the outpatient department. Age- and sex-matched controls were enrolled from healthy individuals. Serums were collected at 8 o'clock in morning in a seated position. Serum aldosterone levels were quantified using enzyme-linked immunosorbent assays. Central retinal thickness (CRT) and subfoveal choroidal thickness (SCT) were measured using OCT (Spectralis; Heidelberg Engineering, Dossenheim, Germany). Inclusion criterion for acute CSC was focal serous retinal detachment involving the macula with 1 or more leakage on FFA within 6 months. For chronic patients, inclusion criteria were persistent subretinal fluid involving the macula for at least 6 months or serous retinal detachment with diffuse atrophy and decompensation of retinal pigment epithelium (RPE) with/without gradual, indistinct RPE leakage on FFA.

**Results:** A total of 20 acute and 19 chronic CSC patients and 12 normal controls were enrolled. The average age was  $44.3 \pm 6.7$  in acute patients,  $51.8 \pm 11.7$  in chronic patients, and  $43.1 \pm 13.8$  in normal controls. The serum





aldosterone levels were  $90.29 \pm 56.53$  pg/mL in acute patients,  $63.18 \pm 49.93$  pg/mL in chronic patients, and  $61.86 \pm 39.83$  pg/mL in normal controls. There were no significant differences between the 3 groups ( $P = 0.174$ ), nor was there a relationship between serum levels and CRT, SCT, and disease duration.

**Conclusions:** No aldosterone abnormalities were detected in CSC patients.

Dec 09, 2017 (Sat) 11:00 - 12:30

Venue: Room 302 & 303

### A Study of Macular Ganglion Cell Complex Thickness in Type 2 Diabetes in a South Indian Population

First Author: Sangeetha **SEKARAN**

**Purpose:** To evaluate macular ganglion cell complex (GCC) thickness in patients with type 2 diabetes (DM) with or without diabetic retinopathy (DR) by automated detection on spectral domain optical coherence tomography (SD-OCT; Optovue) and to investigate the relationship between GCC thickness and duration of DM, DR status, age, and gender.

**Methods:** This is an observational study performed on 303 eyes of 212 subjects. All type 2 diabetics with or without DR without macular involvement and no previous laser treatment were included. DR grading was done based on Early Treatment Diabetic Retinopathy Study (ETDRS) classification. Macular imaging was performed in each eye with SD-OCT. GCC analysis was done, which provided parameters expressed as average and sectoral thickness. To determine the relationship between layer thickness and duration of DM, DR status, age, and gender, a multiple linear regression analysis was used.

**Results:** Mean GCC thickness at the macula was lower in type 2 DM with no DR ( $87.41 \pm 13.62$   $\mu\text{m}$ ;  $n = 101$ ) compared to healthy controls ( $93.60 \pm 11.45$   $\mu\text{m}$ ,  $n = 101$ ). Mean GCC thickness at the macula was lower in type 2 DM with DR ( $84.23 \pm 10.54$   $\mu\text{m}$ ,  $n = 101$ ) when compared to healthy controls and type 2

DM with no DR.

**Conclusions:** Objective assessment of GCC finds importance in DR as its evaluation will help in detection of inner retinal loss associated with the disease. Hence, it can be used for early detection of damage and for visual prognosis.

Dec 09, 2017 (Sat) 11:00 - 12:30

Venue: Room 302 & 303

### Associations Between Visual Acuity and Retinal Microvascular Parameters Measured With Optical Coherence Tomography Angiography in Patients With Diabetic Macular Edema

First Author: Yi-Ting **HSIEH**

Co-Author(s): Tzyy-Chang **HO**, Chia-Chieh **HSIAO**, Tso-Ting **LAI**, Chang-Hao **YANG**, Chung-May **YANG**

**Purpose:** To evaluate the associations between visual acuity and the retinal microvascular density and morphological characteristics in patients with diabetic macular edema (DME) using optical coherence tomography angiography (OCTA).

**Methods:** Ninety-seven eyes from 54 patients with diabetic macular edema were enrolled in this study. OCTA was performed in each eye, and the central retinal thickness (CRT) and the  $3 \times 3\text{-mm}^2$  en face OCTA images of the superficial and deep retinal layers were obtained for each eye. Microvascular parameters including the number of microaneurysms, area of foveal avascular zone (FAZ), acircularity index of FAZ, vessel density, skeleton density, vessel density index, and fractal dimension were measured accordingly. The presence of inner segment/outer segment (IS/OS) junction disruption at the fovea was also recorded. Linear mixed models were used to evaluate the correlations between best-corrected visual acuity (BCVA) and the microvascular parameters.

**Results:** After adjustment for CRT and IS/OS disruption at the fovea, higher acircularity index of FAZ, lower vascular density, and lower fractal dimension in the deep retinal layers





were all correlated with poorer BCVA ( $P = 0.030, 0.049, \text{ and } 0.039$ , respectively). As for the parameters in the superficial layer, none of them were found to be correlated with BCVA after adjustment for CRT and IS/OS disruption.

**Conclusions:** In eyes with DME, those with higher irregularity of FAZ, lower vessel density, or lower fractal dimension in the deep retinal layers measured with OCTA tended to have poorer vision. Such correlations persisted after adjustment for CRT and IS/OS disruption at the fovea.

Dec 09, 2017 (Sat) 11:00 - 12:30

Venue: Room 302 & 303

### Blood 25-Hydroxyvitamin D Levels and Diabetic Retinopathy in Koreans

First Author: Donghyun **JEE**  
Co-Author(s): Eunchul **KIM**

**Purpose:** To investigate the association between 25-hydroxyvitamin D and diabetic retinopathy (DR).

**Methods:** A population-based cross-sectional study using a nationwide, systemically stratified, multistage, clustered sampling method included a total of 18,363 subjects aged  $\geq 40$  years who participated in the Korean National Health and Nutrition Examination Survey during 2008–2012. All participants participated in standardized interviews, blood 25-hydroxyvitamin D level evaluations, and comprehensive ophthalmic examinations. Seven standard retinal fundus photographs were obtained from both eyes after pupil dilatation. DR was graded according to the modified Airlie House classification system.

**Results:** The blood 25-hydroxyvitamin D levels were 19.2 ng/mL in men and 17.9 ng/mL in women. After adjusting for potential confounders, including age, sex, diabetes duration, hemoglobin A1c levels, and hypertension, the odds ratios (OR) for any DR and proliferative DR among men decreased significantly in the highest blood 25-hydroxyvitamin D level quintile relative to

the lowest quintile [OR, 0.37; 95% confidence interval (CI), 0.18–0.76;  $P$  for trend = 0.004 and OR, 0.15; 95% CI, 0.03–0.83;  $P$  for trend = 0.043].

**Conclusions:** This study provides the first epidemiologic findings of the inverse relationships of blood 25-hydroxyvitamin D levels with any DR and proliferative DR only in men. Considering antiangiogenic and antifibrotic action of vitamin D, further studies including longitudinal and interventional analysis are warranted.

Dec 09, 2017 (Sat) 11:00 - 12:30

Venue: Room 302 & 303

### Clinical Characteristics and Risk Factors of Retinopathy, Macular Edema, and Retinal Neurodegeneration in Type 2 Diabetes Mellitus

First Author: Jong In **YOU**  
Co-Author(s): Kunho **BAE**, Eung Suk **KIM**, Ki Young **KIM**, Seung Young **YU**

**Purpose:** To investigate the association of genetic and environmental factors of diabetic retinopathy (DR), diabetic macular edema (DME), and retinal nerve fiber layer (RNFL) thickness in Korean diabetes patients.

**Methods:** A total of 183 Korean patients with type 2 diabetes mellitus (DM) from Kyung Hee University Hospital, Seoul completed ophthalmic exams using fundus photography and optical coherence topography (Cirrus OCT) for segmented retinal layer thickness. Individuals were categorized according to the DR grade [no DR, nonproliferative DR (NPDR), proliferative DR (PDR)] and presence of DME. Clinical characteristics including blood chemistry, medical, and social history information were collected with standardized questionnaires. Genotype association and logistic regression analyses were done and stepwise regression models to best predict diabetic retinopathy and DME were constructed.

**Results:** Age, microalbumin, BUN, Cr,





dyslipidemia, and daily activity were significantly associated factors with DR (all  $P < 0.05$ ). Age, weight, diastolic pressure, HbA1c, microalbumin, and liver function profile were significantly associated factors with DME (all  $P < 0.05$ ). Specific single nucleotide polymorphisms (SNPs) showed significant association with DR, DME, and RNFL thinning, which needs further confirmation with replication cohort.

**Conclusions:** There were several significant environmental and biological risk factors for Korean DR and DME patients. All of the found genes are possibly involved with DR, DME, and retinal neurodegeneration, respectively. This finding nominates possible novel loci as potential DR susceptibility genes in Koreans that are independent biochemistry factors and may provide further insight into the pathophysiology of DME and retinal neurodegeneration, known as early changes of DR.

Dec 09, 2017 (Sat) 11:00 - 12:30

Venue: Room 302 & 303

### Comparison of Oxidative Stress Marker Levels Among Patients With Type 2 Diabetes Mellitus and Correlation With HbA1c

First Author: Kiu Kwong **HAN**

Co-Author(s): Zunaina **EMBONG**, Hanizasurana **HASHIM**

**Purpose:** To compare the oxidative stress markers in tears in no diabetic retinopathy (DR), nonproliferative DR (NPDR), and proliferative DR (PDR) and also to correlate the oxidative stress markers and HbA1c.

**Methods:** A cross-sectional study was conducted among type 2 diabetes mellitus (DM) patients with no DR, NPDR, and PDR. Tear samples were collected and laboratory analysis was performed to test glutathione peroxidase, catalase, and malondialdehyde (MDA) levels of tears using oxidative stress marker kits.

**Results:** The mean level of MDA and catalase for all the groups showed no significant difference. However, catalase demonstrated the

highest mean level in the PDR group compared to lesser severity groups. The mean level of glutathione peroxidase showed a significant difference among the groups. Based on post hoc results, there was a significant mean difference of glutathione peroxidase between no DR and PDR. There was an asymptotically significant mean difference of glutathione peroxidase between NPDR and PDR. There was no correlation between HbA1c and oxidative stress markers.

**Conclusions:** Glutathione peroxidase level was significantly related to the severity of DR. Although catalase results were not significant, it showed the highest level in the PDR group compared to NPDR and no DR. MDA showed a poor relation with the severity of DR. There was no correlation between HbA1c and all oxidative stress markers in the present study.

Dec 09, 2017 (Sat) 08:30 - 10:00

Venue: Room 304 & 305

### Dark Signals in the Choroidal Vasculature on Optical Coherence Tomography Angiography: An Artefact or Not?

First Author: Rui **HUA**

**Purpose:** Optical coherence tomography angiography (OCTA) based on mathematical processing of sequentially acquired structural OCT has been applied widely in both retinal and choroidal research and may yield advantages over traditional angiography. However, optical phenomena and image processing algorithms may create imaging artifacts. OCTA therefore requires careful interpretation. In this review, the authors try to investigate choroidal vascular abnormal signals in OCTA, with multifactor analysis.

**Methods:** We reviewed 55 cases, including 20 normal eyes, 13 geographic atrophy eyes, 15 age-related macular degeneration eyes, 8 polypoidal choroidal vasculopathy eyes, and 3 Stargardt disease eyes examined by multicolor imaging, swept source OCTA with optical microangiography technique, and





spectral domain OCTA with either full-spectrum amplitude decorrelation algorithm or split-spectrum amplitude-decorrelation angiography technique.

**Results:** The choroidal dark vascular signals in OCTA were related to factors such as the laser light penetration depth and masking effect of retinal pigment epithelium, the orientation of vessels compared with the scanning lasers and the intensity of blood flow, the regional detectable velocity range of blood flow, periphery atrophic tissues, or the absorption of superior vessels on the scanning laser.

**Conclusions:** Multiple factors should be taken into account simultaneously in order to get accurate and comprehensive interpretations of choroidal vasculature.

**Dec 09, 2017 (Sat) 08:30 - 10:00**

**Venue: Room 304 & 305**

### Early Effects of External Beam Radiotherapy on Retina and Other Ocular Structures

*First Author: Michael CHENG*

*Co-Author(s): Tengku Ain KAMALDEN, Mastura MD YUSOF, C. U. THIAGESWARI*

**Purpose:** To assess the relationship of early effects of external beam radiotherapy on the retina and other ocular structures.

**Methods:** This was a prospective observational cohort study on patients in whom radiotherapy was initiated for newly diagnosed head and neck tumors. Spectralis spectral domain optical coherence tomography (SD-OCT) was used to evaluate the thickness of the retina focusing on the parafovea and peripapillary retinal nerve fiber layers (RNFL). Retinal thickness was measured before radiation (pre-RT) and after total radiation at different time points: ranging from <14 days (mean of 9 days) to >270 days (mean 355) of post total radiation (RT). Only eyes which received the higher dose of radiation were included. Subjects were also assessed in their visual acuity, tear film break up time, central corneal thickness, and intraocular pressure.

**Results:** A total of 37 patients were recruited,

out of whom 29 completed 180 days of follow-up. Retinal thinning was observed in all 4 quadrants of the parafoveal retinal layers within the first 180 days. Thinning was not seen in the peripapillary RNFL within the same period of time. Retinal thinning was observed with radiation at more than 2400 cGY (24 GY). Doses of RT less than 2400 cGY had no detectable abnormalities. Thinning of the retina was both dose- as well as time-dependent.

**Conclusions:** Retinal thinning was detectable as early as 180 days following radiotherapy suggesting radiation-induced damage to the retina despite following current protocols to minimize ocular effects.

**Dec 09, 2017 (Sat) 08:30 - 10:00**

**Venue: Room 304 & 305**

### Evaluation of the Progression Rate of Atrophy Lesions in Punctate Inner Choroidopathy Based on Autofluorescence Analysis

*First Author: Rui HUA*

**Purpose:** To investigate the autofluorescence (AF) characteristics of punctate inner choroidopathy (PIC) and to evaluate the progression rate of retinal pigment epithelium (RPE) atrophy lesions in PIC using confocal scanning laser ophthalmoscopy.

**Methods:** Twenty-two eyes of 14 PIC cases and 21 eyes of 21 nonproliferative diabetic retinopathy (NPDR) cases that received retinal coagulation as a control group were enrolled in this study. Enhanced depth imaging optical coherence tomography (EDI-OCT) and AF were recorded from all patients at 18 months' follow-up. The RPE atrophy areas of PIC and laser scars in NPDR were analyzed using the Region Finder software of the Heidelberg Eye Explorer. This software allows direct export of AF images from the database and semiautomated detection of atrophic areas by shadow correction, vessel detection, and selection of seed points.

**Results:** At baseline, both hyperfluorescence and hypofluorescence were observed in the lesions of PIC eyes with a focal elevation of RPE





and corresponding disruption of the ellipsoid region of the inner segment ellipsoid zone (EZ). In contrast, hypo-AF was detected when there was a lack of RPE. The mean progression rate of RPE atrophy in PIC and NPDR were 3.735 mm<sup>2</sup>/year (0.056-0.545) and 0.127 mm<sup>2</sup>/year (0.015-0.466), respectively. Compared with the atrophy area in the last visit, the progression rate in PIC was significantly greater than that in NPDR (Z = 5.615, P < 0.0001).

**Conclusions:** The results of AF reflect the status of PIC and the progression rate of RPE atrophy in PIC, which can be used to predict the progress of PIC noninvasively.

Dec 09, 2017 (Sat) 08:30 - 10:00

Venue: Room 304 & 305

### Intravitreal Dexamethasone Implant Position In Situ and Ocular Hypertension

First Author: Aditya **SUDHALKAR**

**Purpose:** To determine the association between the dexamethasone implant position in the vitreous cavity and ocular hypertension.

**Methods:** Retrospective review of patients with at least 1 intravitreal dexamethasone implant injection from 2012-2016. Patients who had a minimum follow-up for 6 months and documented evidence of the implant position were included in the study. Steroid responders, glaucoma patients, vitrectomized eyes, and eyes with liquefied vitreous were excluded. Relevant data was collected from patient charts. Three positions (P1, P2, P3) were identified: P1 (in contact with the pars plana/ciliary body region), P2 (anterior to vortex veins), and P3 (posterior to vortex veins). Ocular hypertension (OHT) was defined as absolute intraocular pressure (IOP) > 25 mm Hg and/or IOP rise > 10 mm Hg. The relationship between implant position and IOP rise after factoring in other high-risk characteristics was the outcome measure. The odds ratio, Fisher exact test, univariate and multivariate analysis, as well as proportions and descriptive statistics were used for statistical analysis.

**Results:** A total of 377 patients (432 eyes; 257 males; 677 injections) were eligible for analysis. The median age was 57.24 ± 6.32 years. Eighty-eight eyes had OHT. Patients with retinal vein occlusion, uveitis, males, and those with the implant in P1 were most likely to develop OHT. Of these, 54 eyes had the implant in P1. P1 was associated with high IOP spikes (>15 mm Hg; P = 0.004) and early (<15 days) IOP spikes (r = 0.84, P < 0.001). P1 had the highest odds among all for developing OHT.

**Conclusions:** An anteriorly positioned dexamethasone implant in situ appears to be an independent risk factor for ocular hypertension.

Dec 09, 2017 (Sat) 08:30 - 10:00

Venue: Room 304 & 305

### Long-Term Outcome of 36G EBRT in Advanced Retinoblastoma

First Author: Nidhee **JAIN**

Co-Author(s): Parag K **SHAH**, S **PREMA**, V **NARENDRA**

**Purpose:** Retinoblastoma is the most common intraocular tumor in the pediatric age group. It is a radiosensitive tumor and 46G external beam radiotherapy (EBRT) was the standard of care for disease consolidation and globe salvage after chemotherapy. EBRT is associated with the risk of orbital hypoplasia and secondary malignancy. Hence, a lower dose of EBRT (36G) was given to reduce the incidence of these secondary complications.

**Methods:** We aimed to analyze the long-term outcome of lower dose (36G) EBRT in advanced retinoblastoma (RB) cases. This was a retrospective analysis of 25 eyes of 13 patients with advanced RB. All patients underwent 6 cycles of chemotherapy and local consolidative therapy. Three eyes were enucleated after chemotherapy and 22 eyes were subjected to 36G EBRT globe salvage therapy.

**Results:** Patients were followed up for a mean of 5.5 years and recurrence was seen in 9 eyes (40.90%). Time from EBRT to recurrence ranged from 2 months to 22 months. Among





those patients, 5 eyes (55.5%) needed enucleation, and 4 were managed with systemic chemotherapy, transpupillary thermotherapy (TTT), cryotherapy, and laser based on the type and severity of recurrence. Other complications such as PSCC were seen in all patients and keratitis in 2 patients. There was no occurrence of metastatic disease or second neoplasm.

**Conclusions:** 36G EBRT had a globe salvage rate of only 77.27%. Recurrence was seen in 40.9% of eyes, requiring further treatment and emphasizing the need for vigilant follow-up after EBRT.

**Dec 09, 2017 (Sat) 08:30 - 10:00**

**Venue: Room 304 & 305**

### Low Doses of Hydroxychloroquine Are Safe to the Retina

*First Author: Dan SONG*

**Purpose:** To evaluate the damage to retinal function caused by hydroxychloroquine using optical coherence tomography (OCT), perimetry, and microperimetry.

**Methods:** Fifteen patients (30 eyes) with hydroxychloroquine as a test group and 24 patients (48 eyes) before taking hydroxychloroquine treatment as a control group were recruited. The daily dose of hydroxychloroquine was less than 5 mg/kg and the duration was 0.5 to 15 years. The existence of retinal damage was evaluated by OCT. The perimetry and the microperimetry were performed to examine mean sensitivity (MS).

**Results:** No retinal damage was observed by OCT in all patients. In the control group and in the test group, the perimetry showed that the MS values were  $24.94 \pm 2.35$  dB and  $24.79 \pm 2.53$  dB, and microperimetry showed that the MS values were  $26.90 \pm 2.16$  dB and  $26.65 \pm 2.30$  dB. There were no significant differences between the 2 groups ( $P = 0.794$ ,  $t = 0.262$ ;  $P = 0.741$ ,  $t = 0.478$ , respectively).

**Conclusions:** Data of OCT, perimetry, and microperimetry confirmed that hydroxychloroquine was safe to the retina if the

daily dose was less than 5 mg/kg and duration was less than 20 years, which is recommended by the American Academy of Ophthalmology in "Recommendations on Screening for Chloroquine and Hydroxychloroquine Retinopathy."

**Dec 09, 2017 (Sat) 11:00 - 12:30**

**Venue: Room 302 & 303**

### Macular Changes in Diabetic Patients After Phacoemulsification Treated With Monotherapy Sodium Diclofenac 0.1%

*First Author: Sindy SEMBIRING*

**Purpose:** Previous study by Pardianto observed perifoveal edema in nondiabetic patients receiving sodium diclofenac 0.1% and antibiotic after phacoemulsification. Systemic microangiopathy in diabetic patients even without the presence of diabetic retinopathy brings the risk of macular edema after phacoemulsification. In this study we would like to study the macular changes in diabetic patients after cataract surgery receiving sodium diclofenac 0.1% and antibiotic.

**Methods:** Cohort study. Macular changes were studied pre- and 1-month postphacoemulsification using spectral domain optical coherence tomography (OCT). Visual acuity pre- and 1-month postphacoemulsification were also recorded. Postoperatively patients were treated by sodium diclofenac 0.1% eye drops every 3 hours in addition to levofloxacin 0.5% eye drops for 1 month.

**Results:** Forty cataract eyes of diabetic patients were studied. Thirteen patients were found to have mild-moderate nonproliferative diabetic retinopathy preoperatively. Statistically significant macular thickening was observed in all patients but was more severe in the diabetic retinopathy group. Two patients in the diabetic retinopathy group developed macular edema postoperatively.

**Conclusions:** Macular thickening after phacoemulsification was observed in all







diabetic patients receiving sodium diclofenac 0.1% and was higher in the presence of diabetic retinopathy.

**Dec 09, 2017 (Sat) 08:30 - 10:00**

**Venue: Room 304 & 305**

### **Morphometric Analysis of Multimodal Imaging Features After Intravitreal Ziv-Aflibercept in Chorioretinal Disorders**

*First Author: Jay SHETH*

*Co-Author(s): Giridhar ANANTHARAMAN, Shruti CHANDRA*

**Purpose:** The purpose of our study was to evaluate the short-term safety and efficacy, including morphological response to intravitreal ziv-aflibercept (IVZ) based on spectral domain optical coherence tomography (SD-OCT), in chorioretinal disorders.

**Methods:** Prospectively, 10 eyes with varied pathologies such as polypoidal choroidal vasculopathy (PCV; 3 eyes), wet age-related macular degeneration (AMD; 3 eyes), chronic central serous chorioretinopathy (CSCR; 2 eyes), and pachychoroid neovascularopathy (PCN; 2 eyes) underwent IVZ therapy. At baseline, all patients underwent multimodal imaging including SD-OCT, indocyanine green angiography (ICGA), and disc-fovea angle (DFA; Spectralis), while SD-OCT was repeated at 1 month. Changes in best corrected visual acuity (BCVA), intraretinal fluid (IRF), subretinal fluid (SRF), subfoveal choroidal thickness (SFCT), along with dimensions (height, base diameter, area) of pigment epithelial detachment (PED) at maximum extent and shallow irregular PED (double layer sign; DLS) were analyzed at baseline and at 1 month. Detailed analysis of outer retinal layers, disorganization of inner retinal layers (DRIL), and vitreomacular interface abnormalities (VMIA) was also performed.

**Results:** Compared with baseline, significant reductions were seen in height, base diameter, and PED area, respectively ( $P = 0.02$ ,  $P = 0.01$ ,  $P = 0.02$ ) at 1 month. Statistically significant reductions were also noted in SFCT ( $P = 0.0009$ ), DLS height ( $P = 0.01$ ), and SRF height

( $P = 0.01$ ). A total of 40% and 37.5% of eyes had complete resolution of IRF and SRF, respectively. Improvement was noted in BCVA, DLS width, and CMT, although not significantly. At 1 month, retinal pigment epithelium (RPE) rip showed early resolution in 2/7 eyes, external limiting membrane (ELM) disruption improvement in 4/9 eyes, DRIL improved in 1/5 eyes, hyperreflective dots reduced in 7/10 eyes, while ellipsoid disruption did not show any signs of restoration in all 10 eyes. None of the patients experienced any serious ocular or systemic adverse events.

**Conclusions:** A single intravitreal injection of ziv-aflibercept has promising anatomical outcomes on PED, besides achieving a dry macula and maintaining stable visual acuity with an acceptable safety profile.

**Dec 09, 2017 (Sat) 08:30 - 10:00**

**Venue: Room 304 & 305**

### **Novel Autofluorescence Patterns in Stargardt Macular Dystrophy Using Ultra-Widefield Imaging**

*First Author: Vinod KUMAR*

**Purpose:** To characterize autofluorescence in Stargardt macular dystrophy (STGD1) using ultra-widefield (UWF) imaging.

**Methods:** Cross-sectional study of 24 eyes with Stargardt fundus flavimaculatus at a tertiary eye care center. UWF shortwave autofluorescence images were obtained using Optos TX 200.

**Results:** All eyes showed a central area of hypoautofluorescence along with retinal flecks extending centrifugally and to the nasal side of the optic disc. Peripapillary sparing was seen in all eyes. Flecks were hypoautofluorescent in the center and hyperautofluorescent in the periphery in 67.7% and were only hyperautofluorescent in 33.3%. A background-increased fluorescence was visible in 100% of eyes, the outer boundary of which was marked by distribution of flecks in 83.3% of eyes. Characteristic inferonasal vertical line was seen separating temporal hyperautofluorescence





from nasal hypoautofluorescence in all the eyes. Limitations include the cross-sectional and retrospective nature of the study.

**Conclusions:** UWF imaging is a useful tool for the assessment of autofluorescence in STGD1. The retinal changes in STGD1 are not limited to the posterior pole and extend more peripherally. Novel patterns seen in this study provide new insights into Stargardt disease.

**Dec 09, 2017 (Sat) 08:30 - 10:00**

**Venue: Room 304 & 305**

### Optical Coherence Tomography Protocols for Screening of Hydroxychloroquine Retinopathy in Asian Patients

*First Author: Seong Joon **AHN**  
Co-Author(s): Byung Ro **LEE***

**Purpose:** To investigate the distribution of outer retinal changes in hydroxychloroquine (HCQ) retinopathy and explore optical coherence tomography (OCT) protocols to maximize the sensitivity of HCQ retinopathy detection in Asian patients.

**Methods:** Forty-two eyes (21 patients) with HCQ retinopathy underwent 6-mm horizontal and vertical line scans and 6 × 6-mm<sup>2</sup> volume scans using spectral-domain OCT (SD-OCT) and 9-mm line scans and 6 × 6-mm<sup>2</sup> and 12 × 9-mm<sup>2</sup> volume scans using swept-source OCT (SS-OCT). Distances from the fovea to the defective photoreceptors were measured in the temporal, nasal, superior, and inferior directions from line scan OCT images. The sensitivity of retinopathy detection, indicated by photoreceptor defects, was compared among protocols.

**Results:** The average minimum distance from the fovea to an area of photoreceptor defects was 1.83 ± 1.19 mm (mean ± standard deviation). The distances were greater than 3 mm horizontally and vertically in 15 (35.7%) and 13 (31.0%) eyes with HCQ retinopathy, respectively, and only wide-field line or volume scans could detect defects in the eyes. The 9-mm line scans detected HCQ retinopathy significantly better than 6-mm scans ( $P < 0.001$ );

the sensitivity of the wide volume scan was significantly greater than the standard volume scan ( $P = 0.005$ ). The 12 × 9-mm<sup>2</sup> volume scan detected retinopathy with the greatest sensitivity (100%).

**Conclusions:** Our study recommends a wide-field OCT scan to screen Asian patients taking HCQ medications.

**Dec 09, 2017 (Sat) 11:00 - 12:30**

**Venue: Room 302 & 303**

### Prevalence of Dengue-Related Fundus and Macular Optical Coherence Tomography Findings Among Inpatients at a Regional Referral Hospital

*First Author: Mee Ai **LOH***

**Purpose:** To investigate the prevalence of dengue-related fundus and macular optical coherence tomography (OCT) findings and the spectrum of dengue retinopathy among inpatients at a Malaysian tertiary hospital. The associations between platelet count and hematocrit level with dengue-related fundus and macular OCT findings were also investigated.

**Methods:** This was a cross-sectional study conducted from June to August 2015. Participants underwent a comprehensive ocular examination. Examination included best-corrected distance and near visual acuities, standard black-on-white Amsler chart testing, pupillary light reflex, fundus examination, dilated fundus photographs, and OCT of the macula.

**Results:** A total of 134 patients were included in the study. The prevalence of dengue-related fundus findings and macular OCT findings among the patients was 35% (95% CI: 27%, 43%) and 13% (95% CI: 8%, 19%), respectively. Scotoma ( $P < 0.001$ ), near vision disturbance ( $P = 0.04$ ), and abnormal Amsler findings ( $P < 0.001$ ) were significantly associated with the presence of macular OCT abnormalities. Out of a total of 268 eyes, the 2 most common dengue retinopathies were vessel tortuosity [53 (20%)]



and yellow subretinal dot [28 (10%)]. Out of 30 eyes, diffuse retinal thickening was the most frequent OCT abnormality [22 (73%)]. Platelet count and hematocrit were not associated with abnormal fundus or macular OCT manifestation in patients suffering from dengue fever.

**Conclusions:** The prevalence of dengue-related fundus and macular OCT findings among inpatients in our country were higher compared to other countries. Furthermore, the spectrum of dengue-related fundus and macular OCT findings in our population can be varied.

**Dec 09, 2017 (Sat) 08:30 - 10:00**

**Venue: Room 304 & 305**

### Prognostic Factor Analysis of Intraocular Pressure in Neovascular Glaucoma With Different Diseases

*First Author: Ma XIANG*

**Purpose:** To explore the prognostic factor analysis of intraocular pressure (IOP) in neovascular glaucoma (NVG) with proliferative diabetic retinopathy (PDR), retinal vein occlusion (RVO), and ocular ischemic syndrome (OIS).

**Methods:** A retrospective study for  $23.8 \pm 18.8$  months. A total of 160 NVG patients (200 eyes) were observed, including PDR in 150 eyes, RVO in 30, and OIS in 20. NVG staging criteria in this study were as follows: rubeosis group, open-angle NVG group, and angle closure NVG group. A variety of treatments were administered, including panretinal laser photocoagulation (PRP), anti-vascular endothelial growth factor (anti-VEGF) intravitreal injection, cataract surgery, and pars plana vitrectomy (PPV). Trabeculectomy with 0.02% mitomycin C (LEC) was performed after adequate PRP in patients with high IOP. We analyzed age, gender, initial/final logarithm of the minimum angle of resolution (logMAR) visual acuity (VA), initial/final IOP, extent of iris and/or angle neovascularization, and so on.

**Results:** At the final follow-up, 150 (75%) eyes had IOP  $\leq 21$  mm Hg. Initially, NVG with PDR

had better IOP and logMAR VA. NVG patients with RVO had a higher degree of angle closure and higher IOP. NVG patients with OIS had a higher incidence of hyphema. Angle closure was found to have the greatest effect on final IOP (hazard ratio, 3.059; 95% confidence interval, 1.898–4.916), followed by PDR (0.759; 0.391–0.930). More than 90% of patients treated with LEC had persistent declines in IOP ( $\leq 21$  mm Hg). Stand-alone and combination anti-VEGF therapies were not associated with improved long-term prognosis of IOP.

**Conclusions:** Angle closure was found to have the greatest effect on NVG IOP prognosis. When target IOP values are not obtained after adequate PRP with or without anti-VEGF, early LEC may improve the prognosis of IOP.

**Dec 09, 2017 (Sat) 08:30 - 10:00**

**Venue: Room 304 & 305**

### Relationship Between Mean Platelet Volume and Central Retinal Vein Occlusion in Hypertensive Patients

*First Author: Diva MISRA*

*Co-Author(s): Pritam BAWANKAR, Ronel SOIBAM*

**Purpose:** To study the relationship between mean platelet volume and central retinal vein occlusion (CRVO) in hypertensive patients.

**Methods:** One hundred patients with sudden painless loss of vision with a known history of hypertension who were then diagnosed with CRVO on indirect ophthalmoscopy served as the sample group. One hundred age- and sex-matched patients with sole history of hypertension without any other systemic disease and a best corrected visual acuity of 20/20 in both eyes served as the control group. Blood samples were taken at the time of central retinal vein occlusion diagnosis. Blood samples in controls were collected at the visit when matching to the cases was established with proper informed consent. Mean platelet volume, platelet count, hemoglobin, white blood count, and hematocrit parameters were recorded in both the groups on the same visit. Confidence intervals were set at 95% level with



statistical significance at a P value of <0.05.

**Results:** Mean platelet volume, platelet count, hemoglobin, and hematocrit parameters were recorded. Mean platelet volume was significantly higher among hypertensive cases with central retinal vein occlusion when compared with the hypertensive control group ( $8.059 \pm 0.016$  vs  $7.442 \pm 0.15$  fL, respectively;  $P < 0.001$ ).

**Conclusions:** Our study concluded that mean platelet volume was statistically increased in central retinal vein occlusion patients who were hypertensive. Thus, the present study showed that platelet activation plays a crucial role in the pathogenesis of central retinal vein occlusion in hypertensive cases and further studies are mandatory regarding its potential use as a prognostic biomarker in patients with CRVO.

Dec 09, 2017 (Sat) 08:30 - 10:00

Venue: Room 304 & 305

### The Effect on Macular Pigment Optical Density in Breast Cancer Patients on Tamoxifen

First Author: I-Liang LIM

Co-Author(s): Adlinda ALIP, Angela Voon Pei LOO, Nur Aishah Mohd TAIB, Mee Hoong SEE, Visvaraja SUBRAYAN

**Purpose:** To investigate the effect on macular pigment optical density (MPOD) in breast cancer patients on tamoxifen and to investigate the effect on central macular thickness on optical coherence tomography in the same.

**Methods:** This was an observational, cross-sectional study. A total of 73 female breast cancer patients on tamoxifen and 73 control female subjects were enrolled. For the left and the right eyes of each subject, data were collected from 3 ocular variables: MPOD, central macular thickness, and refractive status.

**Results:** The results showed that mean MPOD differed significantly ( $P = 0.02$ ) between the treatment (mean, 0.39) and the control group (mean, 0.47) by about 0.08 for the left eye, similarly so for the right eye (treatment mean,

0.39; control mean, 0.48;  $P = 0.01$ ). Additionally, there appears to be a trend for MPOD to decrease as tamoxifen duration increases in both eyes. This difference is not likely to be accounted for by the difference in mean central macular thickness between the 2 groups, as no statistically significant difference was detected either in the right (treatment mean, 242  $\mu$ m; control mean, 242  $\mu$ m;  $P = 0.89$ ) or the left eyes (treatment mean, 241  $\mu$ m; control mean, 242  $\mu$ m;  $P = 0.62$ ). However, multiple regression analysis revealed that the variations in MPOD were accounted for by central macular thickness and duration of tamoxifen.

**Conclusions:** The measurement of MPOD and central macular thickness may serve as a noninvasive, convenient, and faster tool in screening breast cancer patients on tamoxifen for detection of tamoxifen maculopathy.

Dec 09, 2017 (Sat) 08:30 - 10:00

Venue: Room 304 & 305

### Ultra-Widefield Imaging of Retinal Capillary Hemangioblastomas

First Author: Pradeep KUMAR

Co-Author(s): Sahil AGRAWAL, Vinod KUMAR

**Purpose:** To describe ultra-widefield (UWF) imaging characteristics of capillary hemangioblastomas including fundus fluorescein angiography (FFA).

**Methods:** Retrospective, cross-sectional study. Case records of patients diagnosed with capillary hemangioblastomas, which had undergone UWF imaging including fundus fluorescein angiography (UWF-FFA, Optos Inc), were analyzed. Variables recorded included demographics, visual acuity, and FFA characteristics.

**Results:** There were 12 eyes of 10 patients. Mean age was 23.8 years. Male:female ratio was 7:3. Laterality was OD = 4, OS = 4, and OU = 2. On UWF-FA capillary hemangioblastomas showed typically dilated tortuous feeder vessels. Increasing hyperfluorescence over time without increase in size was noted in clinically stable





lesions. Diffusely spreading hyperfluorescence was noted in actively exudating lesions. In 7 eyes UWF imaging identified lesions not diagnosed on ophthalmoscopy. A unique FFA feature, abnormal capillary network (ACN) around hemangioblastomas, was seen in all eyes (100%). The ACNs showed interspersed capillary nonperfusion (CNP) areas in 10 eyes (83.3%). Five of 12 (41.7%) eyes showed small telangiectasias arising from CAN capillaries. Capillary leakage was seen in 4/12 (33.3%) eyes. ACNs were mostly anterior (12/12) to capillary hemangioblastomas. Lateral ACNs were seen in 10/12 eyes and 4 eyes showed ACNs more than 2 clock hours away from hemangioblastomas.

**Conclusions:** UWF imaging revealed capillary hemangioblastoma characteristics hitherto unknown. ACNs with interspersed CNP areas may be a source of vascular endothelial growth factor. This might indicate a role of laser photocoagulation to ensure early regression. UWF imaging is useful in identifying lesions missed on ophthalmoscopy. The UWF-FFA characteristics predict clinical activity of lesions and are an excellent tool for patient counseling and maintenance of records.

### Retina (Surgical)

Dec 08, 2017 (Fri) 11:00 - 12:30

Venue: Room 304 & 305

#### 3D MRI-Guided Macular Buckle for Myopic Macular Retinoschisis

First Author: Xuemin JIN

**Purpose:** To investigate the effects of 3-dimensional (3D) magnetic resonance imaging (MRI) guided macular buckle for myopic macular retinoschisis.

**Methods:** Nine eyes of myopic macular retinoschisis with macular staphyloma diagnosed by spectral domain optical coherence tomography (SD-OCT) were enrolled. The axial lengths ranged from 28.5-

32.0 mm. The eye shape was reconstructed by 3D MRI and was used to guide macular buckle. Best corrected visual acuity (BCVA), axial length, refractive error, fundus photography, SD-OCT, 3D MRI, and surgical complications were criteria to evaluate the effect. The follow-up time was 6 months.

**Results:** At 1 week and 6 months postoperatively, SD-OCT showed retinoschisis disappeared completely in 2 and 3 eyes, obviously improved in 4 and 4 eyes, improved in 2 and 1 eyes, and was unchanged in 1 and 1 eye, respectively. BCVA improved 3 lines in 1 eye while others remained unchanged. 3D MRI showed the macular buckles were placed accurately except in the eye with no change of retinoschisis. No serious complications were noted.

**Conclusions:** 3D MRI-guided macular buckle is effective for myopic retinoschisis.

Dec 08, 2017 (Fri) 14:00 - 15:30

Venue: Room 304 & 305

#### A Potential Treatment Modality in Central Serous Chorioretinopathy: Transpupillary Thermotherapy

First Author: Durgesh KUMAR

**Purpose:** To assess transpupillary thermotherapy (TTT) in the treatment of fresh and chronic central serous chorioretinopathy (CSCR) with sub- or extrafoveal leaks.

**Methods:** In this study 121 eyes of 109 patients with diagnosed CSCR were considered during a period of 6 years. Seventy-nine eyes had fresh CSCR (<6 weeks duration) and 42 eyes had chronic CSCR (>6 weeks duration with 3 cases of more than 1-year duration). Visual acuity test, fluorescein angiography (FA), and optical coherence tomography (OCT) were performed. Single leak was noticed in 59.5% of cases on FA. Subfoveal leaks were seen in 26.6% of the fresh cases group and in 31% of cases in the chronic group. All leaks were treated by diode 810 nm TTT laser beam in subthreshold dose (ie, 10-15% less laser power needed to





produce faint blanching on the retina). In the majority of patients spot size was 0.6 or 1 mm for 90 seconds and power of 90 to 270 mW was required. All cases were followed up after TTT for at least 6 months.

**Results:** Among fresh cases, in 81% of eyes macular elevation reduced by >75% on OCT with 2 to 4 lines of improvement on Snellen after 1 week and earliest near total resolution (>90% retinal elevation resolved) seen on the 10th day after TTT. Earliest near total resolution was observed at the fifth week in chronic cases. Total resolution of subretinal fluid was achieved in 96.2% of fresh cases and in 90.5% of the chronic group. Cases of more than 1-year duration resolved completely by the fourth month with improvement of 2 to 3 lines.

**Conclusions:** It is evident that TTT is a safe and effective modality for treating both fresh and chronic CSCR even in cases with subfoveal leaks.

Dec 08, 2017 (Fri) 16:00 - 17:30

Venue: Room 304 & 305

### Breaking the Rules in Macular Hole Surgery

First Author: Aneesha **LOBO**

Co-Author(s): Arun **BHARGAVA**

**Purpose:** To evaluate anatomical and functional outcomes of patients undergoing macular hole surgery without prone positioning.

**Methods:** Thirty-eight eyes of 36 consecutive patients treated for macular hole by a single surgeon over 1 year were included. Macular hole of >1 year or unknown duration or those secondary to other causes were excluded. Patients underwent standard 25G vitrectomy, internal limiting membrane (ILM) peel, and C3F8 tamponade. Postoperative prone position was advised only for 1 hour. Macular hole closure was assessed by biomicroscopy as well as optical coherence tomography (OCT) on days 1, 7, 30, 90, and 180.

**Results:** After an average follow-up of 264.9 days, the anatomical closure rate in our study was 76.31%. There was a significant

improvement ( $P = 0.020$ ) in visual acuity at final visit. Various factors like age of the patient, duration of macular hole, presence of subretinal fluid, and hole forming factor were also considered. There was a significant anatomical and functional improvement in all the subgroups.

**Conclusions:** The role of postoperative prone positioning has been debatable. While the common practice is to advise face-down positioning after macular hole surgery, even minimal face-down posturing provides anatomical and functional results comparable to those with prone posturing. Maintaining the prone position can be very cumbersome for patients. By eliminating tedious positioning, we may increase patients' acceptance and compliance with macular hole surgeries.

Dec 08, 2017 (Fri) 16:00 - 17:30

Venue: Room 304 & 305

### Buckle With No Buckle in Retinal Detachment: A New Minimally Invasive 360-Degree Scleral Encircling Sans Segmental Buckling

First Author: Mariam **DOCTOR**

Co-Author(s): Abhishek **DESAI**, Rushikesh **NAIGAONKAR**

**Purpose:** In this paper we present a new 360-degree scleral encircling procedure removing the need for segment buckling, adapting only a 240 number band: buckle with no buckle in retinal detachment (BnBRD). The rationale of employing an encircling approach is that it not only supports the break but also provides 360-degree support to the vitreous base.

**Methods:** A 360-degree conjunctival peritomy is made and the conjunctiva is reflected back. All 4 recti muscles are tagged. Retinal tears are marked on the sclera with localizer and retinopexy is then performed by cryopexy. This is followed by placement of the number 240 belt at the level of the breaks with the help of scleral pockets made in 4 quadrants and the belt is secured with belt tie at the superotemporal quadrant. The temporarily





secured buckle is loosened to allow access and drainage is performed with a sclerotomy under the buckle. Drainage site is then covered with the belt buckle and the buckle height is adjusted. Intravitreal air is injected to counter the hypotony. Finally the conjunctiva is apposed and sutured with 7.0 vicryl.

**Results:** In the 90 operated eyes, a significant drop in best corrected visual acuity (BCVA) (0.5426 to 0.1523) was observed postoperatively. We obtained an anatomical reattachment success rate of 100% with surgical time  $41 \pm 12$  minutes with minimal postoperative inflammation and increased patient comfort.

**Conclusions:** BnBRD is minimally invasive and can be conducted successfully with minimal surgical time and no increase in myopic astigmatism and yields greater patient comfort, placing it in the vanguard as surgery of choice for fresh RDs.

Dec 08, 2017 (Fri) 08:30 - 10:00

Venue: Room 304 & 305

### Changes of Choroidal Thickness in PCV Patients After Combination Therapy of Intravitreal Ranibizumab and PDT

First Author: Bojun **ZHAO**

**Purpose:** To evaluate the changes of subfoveal choroidal thickness in different types of polypoidal choroidal vasculopathy (PCV) after combination therapy of intravitreal ranibizumab (IVR) and photodynamic therapy (PDT) by using enhanced depth imaging optical coherence tomography (OCT).

**Methods:** All patients underwent initial combination therapy followed by pro re nata (PRN) strategy of IVR. The follow-up time was 3 months. Thirty-two eyes with naive PCV in 32 patients were divided into 2 groups based on double layer sign (DLS) positive or negative on OCT examination. The changes of subfoveal choroidal thickness and best corrected visual acuity (BCVA) before and after treatment were analyzed.

**Results:** Seventeen eyes were in the DLS positive group and 15 eyes in the DLS negative group. The injection numbers for the 2 groups were  $1.5 \pm 0.92$  and  $1.82 \pm 0.98$  ( $P = 0.48$ ). Baseline subfoveal choroidal thickness was significantly different between the DLS positive and negative groups. After treatment, subfoveal choroidal thickness decreased significantly in the DLS positive group (from  $333.75 \pm 76.79$   $\mu\text{m}$  to  $266.37 \pm 58.45$   $\mu\text{m}$ ,  $P = 0.006$ ) compared to that in the DLS negative group (from  $243.09 \pm 68.32$   $\mu\text{m}$  to  $229.11 \pm 73.68$   $\mu\text{m}$ ,  $P = 0.156$ ). The logarithm of the minimum angle of resolution (logMAR) BCVA improvement was from  $0.84 \pm 0.42$  to  $0.59 \pm 0.42$  ( $P = 0.031$ ) and from  $1.13 \pm 0.47$  to  $0.75 \pm 0.58$  ( $P = 0.019$ ) in the DLS positive and negative groups, respectively.

**Conclusions:** The choroidal thickness in the patients with DLS was thicker and had a significant decrease after combination therapy. Combination therapy was effective for the improvement of BCVA in both types of PCV.

Dec 08, 2017 (Fri) 11:00 - 12:30

Venue: Room 304 & 305

### Clinical Experience With Tenecteplase in Various Ophthalmic Pathologies

First Author: Wen Yee **LEE**

Co-Author(s): Kiet Phang **LING**, Haslina **MOHD ALI**, Norlina **MOHD RAMLI**, Wee Min **TEH**

**Purpose:** To share our experience and patient outcomes of using tenecteplase (TNKase) in various ocular conditions.

**Methods:** Retrospective analysis of 9 patients treated with intracameral or intravitreal TNKase (50 mcg/0.1 mL) for varying conditions. Outcome measures include resolution of fibrin, lysis of synechiae, resolution of submacular hemorrhage, and change in visual acuity. Adverse events, if any, were noted.

**Results:** Three patients received intracameral TNKase for severe anterior uveitis with fibrinous exudation, after vitrectomy with inflammatory membrane on the intraocular





lens (IOL), and chronic uveitis with posterior synechiae. There was complete resolution of fibrin and synechiolysis in the first case, while the patient with membrane on the IOL had partial resolution. No improvement was seen in the patient with chronic anterior uveitis and longstanding posterior synechiae. Another 6 patients received intravitreal TNKase for submacular hemorrhage of various underlying pathologies, including idiopathic polypoidal choroidal vasculopathy, ruptured macroaneurysm, and trauma. In 5 of the 6 cases, TNKase was given together with perfluoropropane gas for pneumatic displacement. The remaining case received TNKase at the end of vitrectomy. Resolution of blood was achieved in 5 cases. All patients either maintained or improved their final visual acuity, except for 1 case with breakthrough vitreous hemorrhage requiring vitrectomy.

**Conclusions:** Preliminary findings show that intracameral TNKase is effective for rapid resolution of fibrin in the anterior chamber and synechiolysis in the acute setting. Intravitreal TNKase as an adjunct in pneumatic displacement of submacular hemorrhage also proved useful. Further studies are warranted to further determine the safety profile, therapeutic dose range, and other ocular routes of administration for TNKase.

**Dec 08, 2017 (Fri) 14:00 - 15:30**

**Venue: Room 304 & 305**

### **Clinical Outcomes of Reduced-Fluence Photodynamic Therapy for Symptomatic Subfoveal Retinal Pigment Epithelial Detachment in Central Serous Chorioretinopathy**

*First Author: Jun Won JANG*

*Co-Author(s): Sungsoon HWANG, Se Woong KANG, Kyung Tae KIM, Sang Jin KIM*

**Purpose:** To report clinical outcomes of reduced-fluence photodynamic therapy (PDT) for symptomatic subfoveal retinal pigment epithelial detachment (RPED) in central serous chorioretinopathy (CSC) and determine prognostic factors affecting treatment outcome.

**Methods:** This retrospective interventional study included 35 eyes of 35 patients with serous subfoveal RPED with choroidal hyperpermeability. Any cases with evidence of age-related macular degeneration were rigorously excluded from the study. Reduced-fluence PDT was applied to every patient. Best-corrected visual acuity (BCVA), anatomic resolution of RPED, subjective symptom improvement, and complications were analyzed.

**Results:** One month after reduced-fluence PDT, 28 eyes (80.0%) manifested complete resolution of subfoveal RPED. Among them, 19 patients (67.9%) reported subjective improvement of vision. The subjective improvement was significantly associated with the presence of dysmorphopsia at baseline. Logarithm of the minimum angle of resolution (logMAR) visual acuity improved from 0.15 to 0.09 ( $P = 0.008$ ) between baseline and month 3. Mean follow-up period after treatment was  $10.4 \pm 13.6$  months, and none of the cases have shown recurrence of RPED. Younger age, thicker choroidal thickness, and smaller RPED were positively related to the resolution of RPED after PDT. There was a case complicated by secondary CNV, which responded fairly to intravitreal bevacizumab injection.

**Conclusions:** Symptomatic subfoveal RPED in CSC responded well to reduced-fluence PDT, especially in younger patients with small RPED. Dysmorphopsia rather than decreased visual acuity is a fundamental presentation in RPED. As subfoveal RPED present with fair initial BCVA, PDT fluence should be further adjusted to minimize complications.

**Dec 08, 2017 (Fri) 16:00 - 17:30**

**Venue: Room 304 & 305**

### **Comparative Study of the Efficiency of Intravitreal Injection of Conbercept With Macular Photocoagulation for Macular Edema Secondary to Branch Retinal Vein Occlusion**

*First Author: Guangfeng LIU*

**Purpose:** To assess the clinical effects and





safety of intravitreal injection of conbercept (ICI) compared with the standard-of-care grid laser for macular edema secondary to branch retinal vein occlusion (BRVO).

**Methods:** A total of 50 patients (50 eyes) with macular edema following nonischemic BRVO were retrospectively analyzed. Patients were enrolled in 2 groups. The ICI group (26 eyes) received as needed (PRN) intravitreal injection of 0.05 mL (0.5 mg) conbercept. The laser group (24 eyes) received standard-of-care grid laser for macular edema. The best-corrected visual acuity (BCVA) and central macular thickness (CMT) were observed before and 1 week, 1 month, 2 months, and 3 months after treatment. Then, the changes in pretreatment and posttreatment were compared, and the related complications were recorded.

**Results:** The BCVA differences were not significant between the 2 groups before treatment ( $P > 0.05$ ), and the differences were statistically significant between the 2 groups 1 week, 1 month, 2 months, and 3 months after treatment ( $P < 0.05$ ). Eighteen patients (69.23%) in the ICI group and 8 patients (33.33%) in the laser group had 2 lines of improvement in BCVA 3 months after treatment. The CMT differences were not significant between the 2 groups before treatment ( $P > 0.05$ ), and the differences were statistically significant between the 2 groups 1 week, 1 month, 2 months, and 3 months after treatment ( $P < 0.05$ ). Eleven eyes received repeat intravitreal injection in the ICI group, and no severe side effects occurred in the 2 groups.

**Conclusions:** Mean BCVA change and CMT change were significantly greater in the intravitreal injection of conbercept group than the standard-of-care grid laser group for macular edema secondary to nonischemic branch retinal vein occlusion.

Dec 08, 2017 (Fri) 11:00 - 12:30

Venue: Room 304 & 305

### Conbercept-Assisted Vitrectomy for Severe Proliferative Diabetic Retinopathy

First Author: Junjie YE

Co-Author(s): Zhe CHEN, Bing LI

**Purpose:** To investigate the effectiveness of conbercept-assisted pars plana vitrectomy (PPV) for severe proliferative diabetic retinopathy (PDR).

**Methods:** Prospective randomized comparative trial. Thirty eyes of 30 patients diagnosed with severe PDR in the Peking Union Medical College Hospital from February 2016 to February 2017 were enrolled and randomly assigned into 2 groups. One group received 0.5 mg intravitreal injection of conbercept 7-14 days before PPV, and the other group received PPV. We recorded and compared preoperative visual acuity, surgical time, intraoperative bleeding rate, iatrogenic retinal breaks, and visual acuity, rebleeding rate, and inflammatory reaction within 3 months postoperatively of the 2 groups.

**Results:** The surgical time in the group treated with conbercept preoperatively was  $54.3 \pm 12.3$  min and  $83.3 \pm 18.2$  min in the other group ( $P = 0.001$ ). Intraoperative active bleeding occurred in 3 cases (20%) and 7 cases (46.7%) in the groups with or without conbercept ( $P = 0.025$ ). Iatrogenic retinal breaks occurred in 1 case (6.7%) in the conbercept-pretreated group and 7 cases (46.7%) in the other ( $P = 0.014$ ). Three patients (20%) and 8 patients (53.3%) suffered severe anterior segment inflammatory reaction in the groups with or without conbercept, respectively ( $P = 0.006$ ). Relapsing hemorrhage within 3 days postoperatively occurred in 3 cases (20%) in the group treated with conbercept and 7 cases (46.7%) in the group without ( $P = 0.103$ ).

**Conclusions:** Preoperative intravitreal injection of conbercept given prior to PPV for severe PDR can shorten surgical time, reduce the rate of bleeding and iatrogenic retinal breaks, and



lighten anterior segment inflammation.

**Dec 08, 2017 (Fri) 11:00 - 12:30**

**Venue: Room 304 & 305**

### Effect of Macular Displacement on Structural and Functional Outcomes After Epiretinal Membrane Surgery

*First Author: Aylin KARALEZLI*

*Co-Author(s): Sabahattin SÜL*

**Purpose:** To examine the relationship between macular displacement and functional and structural outcomes at month 6 following epiretinal membrane surgery.

**Methods:** Fifty-six eyes of 56 patients who underwent vitrectomy, epiretinal membrane, and internal limiting membrane peeling (ILM) were included in this study. Change of fovea to optic disc (FOD) and vertical distances (VD) (distance between arcuate vessels) at postoperative month 6 were evaluated for the determination of macular displacement. The integrity of the external limiting membrane (ELM), ellipsoid zone (EZ), and cone outer segment tips (COST) and the presence of dissociated optic nerve fiber layer (DONFL) at month 6 were determined with optical coherence tomography.

**Results:** Pre- and postoperative FOD were  $3668 \pm 284 \mu\text{m}$  and  $3555 \pm 268 \mu\text{m}$ . Mean FOD change was  $202 \pm 144 \mu\text{m}$ . Pre- and postoperative VD were  $7303 \pm 529 \mu\text{m}$  and  $7635 \pm 595 \mu\text{m}$ . Mean VD change was  $412 \pm 243 \mu\text{m}$ . ELM was intact in 46 (82%) eyes, EZ in 38 (68%) eyes, and COST in 38 (68%) eyes. DONFL was detected in 40 (71%) eyes. Mean pre- and postoperative corrected distance visual acuity (CDVA) were logarithm of the minimum angle of resolution (logMAR)  $0.63 \pm 0.2$  and  $0.2 \pm 0.18$ . There was no correlation between postoperative CDVA and FOD change (Spearman rho = 0.136) and VD change (Spearman rho = 0.19). DONFL was significantly associated with FOD and VD change ( $P = 0.013$ ,  $P = 0.02$ , respectively). Postoperative ELM-EZ and COST integrity was not associated with FOD and VD change.

**Conclusions:** The macula seems to displace toward the optic disc and expand in a vertical direction following ERM and ILM peeling. There seems to be no correlation between macular displacement and visual outcomes. Presence of DONFL seems to be associated with increased macular displacement.

**Dec 08, 2017 (Fri) 11:00 - 12:30**

**Venue: Room 304 & 305**

### En-Face Spectral-Domain Optical Coherence Tomography Characteristics of the Inner Retinal Surface After Internal Limiting Membrane Peeling for Macular Hole

*First Author: Neha GOEL*

**Purpose:** To describe characteristics of the inner retinal surface using en-face spectral-domain optical coherence tomography (SD-OCT) after internal limiting membrane (ILM) peeling in full-thickness macular holes (FTMH).

**Methods:** Prospective, interventional case series. Forty-four eyes of 42 patients with idiopathic FTMH who underwent 23G pars plana vitrectomy with ILM peeling and C3F8 gas injection were analyzed using en-face SD-OCT before and after surgery. Preoperative and postoperative best-corrected Snellen visual acuity (BCVA), fundus photographs, and B-scan SD-OCT images were also reviewed. Patients were followed up for a minimum of 6 months.

**Results:** Mean age of the patients was 65.9 years, and 18 were women. Anatomic success rate was 94% after a single surgery and 100% after 2 surgeries. The en-face feature of multiple dark dots along the course of retinal nerve fibers in the area of the ILM peeling, termed concentric macular dark spots (CMDs), was observed in 18 eyes at 2 months (40.9%) after surgery and 24 eyes at 6 months postoperatively (54.5%). The foveal-centered pattern was most common. This feature was not visible on fundus photographs. B-scan SD-OCT indicated dimples in the retinal nerve fiber layer corresponding to each stria. The postoperative BCVA and its improvements were not significantly different between eyes with





and without CDMS. Mean follow-up was 10.8 months (range, 6–24 months).

**Conclusions:** Inner retinal defects as detected on en-face SD-OCT frequently occurred after MH surgery when the ILM was peeled. This is a helpful, noninvasive technique to assess complete ILM removal in FTMH surgery if CDMS appearance on the retinal surface is reported. This feature did not preclude good visual recovery.

**Dec 08, 2017 (Fri) 11:00 - 12:30**

**Venue: Room 304 & 305**

### Endoscopy-Guided Vitrectomy in Eyes With Corneal Opacification

*First Author: Mudit TYAGI*

*Co-Author(s): Jay CHHABLANI, Vivek DAVE, Raja NARAYANAN, Rajeev R PAPPURU*

**Purpose:** To report the anatomical and functional outcomes after endoscopy-guided vitrectomy in eyes with corneal opacification.

**Methods:** Prospective, noncomparative, interventional case series of all patients with corneal opacification who underwent endoscopy-guided pars plana vitrectomy (PPV) procedure from March 2014 to May 2016. All patients underwent 20 or 23 G vitrectomy. The etiology, surgical indication, preoperative and postoperative visual acuity, and additional surgery if performed were noted. The main outcome measure was the anatomic status of the retina postoperatively.

**Results:** Forty-four eyes of 44 patients were included in the study. There were 36 male and 8 female patients. The mean age was 30.07 years. Twelve eyes had a preexisting keratoprosthesis. Nine eyes had failed corneal allograft. Fourteen eyes had ocular trauma including 2 eyes with retained intraocular foreign body. Four eyes had endophthalmitis. Twenty eyes had retinal detachment (RD). Vitreous hemorrhage was seen in 7 cases. Five eyes had retroprosthetic membrane (RPM). One eye had a glaucomatous optic atrophy. Silicone oil insertion along with PPV was done in 25 cases. Seven cases also

underwent Boston keratoprosthesis insertion along with PPV and penetrating keratoplasty was done in 3 cases. RPM removal was done in 5 cases. Postoperatively recurrence of RD was seen in 4 eyes. The visual acuity ranged from perception of light (PL+) to 20/125 preoperatively and was between no perception of light (PL) (in 1 eye with endophthalmitis) to 20/30 postoperatively.

**Conclusions:** Endoscopy-guided vitrectomy can aid in management of posterior segment complications in eyes where conventional visualization is not possible. It has good functional outcomes in terms of anatomic success.

**Dec 08, 2017 (Fri) 11:00 - 12:30**

**Venue: Room 304 & 305**

### ILM Peel and Filling the Optic Disc Pit With Homologous Whole Blood for Treatment of Serous Macular Detachment Secondary to Optic Disc Pit

*First Author: Hussain KHAQAN*

*Co-Author(s): Farrukh JAMEEL*

**Purpose:** To determine the role of internal limiting membrane (ILM) peeling and filling the optic disc pit with whole blood in closure of optic disc pit and resolution of serous macular detachment.

**Methods:** Thirteen eyes of 13 patients were included in the study with serous macular detachment secondary to optic disc pit. A 23-gauge pars plana vitrectomy, ILM peeling, filling the pit with homologous whole blood at the end of surgery under air, and endotamponade of air were done in all 13 cases. Patients were followed for 6 months. Optical coherence tomography (OCT) was performed preoperatively and postoperatively.

**Results:** Optic disc pit was found filled with blood and confirmed with OCT in all 13 eyes on the first postoperative day. On the third day postoperatively, a fibrous tissue was observed in the area of the pit in 9 (69.2%) eyes, while in 4 (30.7%) eyes no fibrous tissue was observed in





the area of the pit. Serous macular detachment resolved completely in 8 (61.5%) eyes within 7 days postoperatively but in 1 (7.6%) eye on the 12th day. Visual improvement was found in all 9 (69.2%) eyes. In 4 (30.7%) eyes optic disc pit remained open at 4-week follow-up, with little or no resolution of serous macular detachment and no improvement in vision in these eyes at 6-month follow-up.

**Conclusions:** ILM peeling and filling of the optic disc pit with homologous whole blood and endotamponade of air play a significant role in closure of optic disc pit, resolution of serous macular detachment, and improvement of vision.

**Dec 08, 2017 (Fri) 16:00 - 17:30**

**Venue: Room 304 & 305**

### Intraoperative OCT-Assisted Vitreoretinal Surgery With Fovea-Sparing Internal Limiting Membrane Peeling for Myopic Traction Maculopathy: Our Experience

*First Author: Atul KUMAR*

*Co-Author(s): Prateek KAKKAR, Aditi MEHTA, R KARTHIKEYA, Raghav RAVANI*

**Purpose:** To evaluate outcomes of intraoperative optical coherence tomography (iOCT) guided traction removal and center-sparing internal limiting membrane (cs-ILM) peeling with gas tamponade in myopic traction maculopathy (MTM).

**Methods:** Nine eyes of 9 patients with MTM underwent 23-gauge pars plana vitrectomy with intraoperative OCT-guided cs-ILM peeling and gas tamponade after Brilliant Blue G dye staining. The primary outcome parameters evaluated were central macular thickness (CMT), improvement in best corrected visual acuity (BCVA), and complications, if any.

**Results:** Average follow-up was  $42.96 \pm 4.78$  weeks. Resolution of the macular retinoschisis was seen in all 9 eyes as demonstrated on SD-OCT. Mean time of resolution of macular retinoschisis after surgery was  $6.80 \pm 1.07$  weeks. At 6-month follow-up, there was a

significant improvement in mean BCVA [ $0.76 \pm 0.26$  logarithm of the minimum angle of resolution (logMAR) units] as compared to the preoperative BCVA ( $1.35 \pm 0.35$  logMAR units;  $P = 0.0089$ ). There was a statistically significant reduction in the CMT from a preoperative CMT of  $569.77 \pm 263.19 \mu\text{m}$  to a postoperative CMT of  $165.88 \pm 45.80 \mu\text{m}$  ( $P = 0.0039$ ). None of the eyes showed worsening of BCVA or development of full thickness macular hole in the intraoperative or follow-up period.

**Conclusions:** Pars plana vitrectomy with iOCT-guided cs-ILM peeling helps in complete removal of traction and total resolution of retinoschisis with low intraoperative and postoperative complications. A significant improvement in BCVA and macular thickness was seen in the follow-up period.

**Dec 08, 2017 (Fri) 16:00 - 17:30**

**Venue: Room 304 & 305**

### Japan Retina Vitreous Society Registry System of Retinal Detachment

*First Author: Masahito OHJI*

*Co-Author(s): Akito HIRAKATA, Yuichiro OGURA, Taiji SAKAMOTO, Shuichi YAMAMOTO, Hidetoshi YAMASHITA*

**Purpose:** Although a randomized clinical trial (RCT) is the gold standard to evaluate the effects of intervention, there are many drawbacks to performing RCTs now. They involve high costs, legal issues, are time-consuming, and others. Above all, there is strong criticism that a RCT does not reflect the clinical facts of real world. The registry study is becoming of more interest in many medical research fields to overcome this. In that line, the Japan Retina Vitreous Society (JVRS) started a registry system for retinal detachment from 2015. This system will be shown with some first primary data.

**Methods:** Twenty institutes of JVRS committee members were selected as data collecting hospitals. All cases of retinal detachment treated in these hospitals were registered to the central data center through the online system.





The following issues, such as nature of retinal detachment, surgical method, surgeons' skills, complications, and surgical results are planned to be registered. The results will be followed and registered for 1 year.

**Results:** From February 2016 to May 2017, 3162 cases were registered: 2077 cases were males and 1085 cases were females. Six-month follow-up data were registered in 952 cases. The patient's age ranged from 3 years to 96 years.

**Conclusions:** Real-world data is important to evaluate the treatment efficacy of intervention and the JVRS registry system will become a powerful tool for that purpose.

**Dec 08, 2017 (Fri) 16:00 - 17:30**

**Venue: Room 304 & 305**

### Lamellar Macular Hole Surgery Using Different Techniques: A Comparative Study

*First Author: Kshitiz KUMAR*

**Purpose:** To study outcomes of 2 different techniques of vitrectomy for symptomatic lamellar macular holes (LMH) with coexistent epiretinal membrane (ERM).

**Methods:** Retrospective interventional study. Main outcome measure was foveal contour at 6 months.

**Results:** Inverted ERM flap creation with internal limiting membrane (ILM) peeling was done in 6 cases of LMH with ERM containing macular pigments (group A, modified technique). Double membrane (ERM + ILM) peeling was done in 6 cases of LMH with ERM having no macular pigments (group B, conventional technique). At 6 months postoperatively, mean central foveal thickness (CFT) recovered from  $105.83 \pm 22.27 \mu\text{m}$  before surgery to  $227.33 \pm 42.38 \mu\text{m}$  in group A ( $P < 0.0001$ ) with smooth normal appearing contour. In group B, mean CFT changed from  $91.66 \pm 20.43$  to  $166.83 \pm 12.28 \mu\text{m}$  ( $P = 0.03$ ) at the final visit with variable foveal contour. Best corrected visual acuity (BCVA) at 6 months improved in both groups with significantly better outcomes in

eyes undergoing inverted ERM flap technique surgery ( $P = 0.02$ ).

**Conclusions:** A modified technique of vitrectomy for LMH helps in recovery of smooth foveal profile, whereas the conventional technique helps in stabilization of foveal contour.

**Dec 08, 2017 (Fri) 11:00 - 12:30**

**Venue: Room 304 & 305**

### Modification of Segmental Scleral Buckling Surgery With Minimal In Situ Conjunctival Incision and Translimbal Traction Suture

*First Author: Lei GAO*

**Purpose:** To introduce a modified technique for minimal segmental buckling through a small in situ conjunctival opening without rectus muscle traction for minimally invasive repair of uncomplicated rhegmatogenous retinal detachment.

**Methods:** This technique was performed in 11 eyes of 11 patients with primary retinal detachment. Conventional traction sutures placed beneath rectus muscles were replaced by an absorbable translimbal traction suture at the lesion quadrant. The conjunctival incision was at 9 mm posterior and parallel to the limbus. After cryopexy, a minimal explant was fixed with 1 to 2 sutures through the conjunctival opening, expanded by a pediatric speculum.

**Results:** Retinal reattachments were achieved with correct buckle positions in all 11 cases, with rapid cosmetic recovery.

**Conclusions:** This modified buckling technique simplifies the buckling procedure, minimizes surgical invasion, preserves an intact limbal conjunctiva, and relieves discomfort.





Dec 08, 2017 (Fri) 14:00 - 15:30

Venue: Room 304 & 305

### Multifocal Electroretinography Assisted Evaluation of Conservative Management Versus Subthreshold Laser in Acute Central Serous Chorioretinopathy

First Author: Neha **GOEL**

Co-Author(s): Aanchal **MEHTA**

**Purpose:** To compare anatomical and functional outcomes of conservative management versus subthreshold laser (STL) in acute central serous chorioretinopathy (CSC).

**Methods:** Prospective interventional study. Thirty eyes with acute CSC were randomized equally to group A (conservative management) or group B (STL). All patients underwent complete ophthalmologic examination, measurement of best corrected Snellen visual acuity (BCVA), contrast sensitivity (CS), fundus fluorescein angiography (FFA), spectral domain optical coherence tomography (SD-OCT), and multifocal electroretinography (MF-ERG) at baseline. Subthreshold focal laser to the leakage point was applied in group B. Outcome measures included BCVA, CS, central foveal thickness (CFT), and mean macular thickness (MMT) on SD-OCT and P1 amplitude on MF-ERG. The follow-up period was 6 months.

**Results:** Mean BCVA was comparable between the 2 groups on follow-up. Mean CS was significantly higher in group B at 6 months ( $P = 0.032$ ). CFT and MMT were significantly lower in group B as compared to group A at 1 month ( $P = 0.005$ ) and 3 months ( $P = 0.049$ ); however, this difference was not maintained at 6 months ( $P = 0.265$ ). P1 amplitude in ring 1 and 2 was significantly lower compared to age- and sex-matched controls in both groups at baseline, but values between the 2 groups were matched. On follow-up, P1 amplitude of ring 1 became significantly lower in group A than in group B at 3 months ( $P = 0.036$ ) and 6 months ( $P = 0.022$ ).

**Conclusions:** STL is a viable therapeutic option in acute CSC. It leads to faster resolution

on SD-OCT and better functional outcomes as evidenced by MF-ERG, as compared to observation alone.

Dec 08, 2017 (Fri) 16:00 - 17:30

Venue: Room 304 & 305

### Multilayered Inverted Internal Limiting Membrane Flap in the Surgical Repair of Large Macular Holes

First Author: Shrinivas **JOSHI**

Co-Author(s): Apoorva **AYACHIT**, Guruprasad **AYACHIT**, Shravan **MASURKAR**, V V **SAMEERA**

**Purpose:** To evaluate the outcomes of large macular hole (MH) closure in the multilayered inverted internal limiting membrane (ILM) flap technique.

**Methods:** A prospective interventional study of 32 eyes of 32 patients with large macular hole ( $>400 \mu\text{m}$ , minimum linear diameter) was conducted. All eyes underwent 25-gauge pars plana vitrectomy with induction of posterior vitreous detachment. ILM peeling was done in multilayered fashion; ILM flaps were trimmed and placed one over the other on the macular hole (guided by intraoperative optical coherence tomography). Nonexpansile C3F8 gas was injected after fluid air exchange. Prone position was advised for 1 week and patients were followed up for 3 months. Functional and anatomical outcomes were analyzed.

**Results:** Thirty-two eyes of 32 patients were included. In this study 88% had idiopathic macular hole and 12% traumatic macular hole. Mean minimum linear diameter (MLD) was  $800.03 \pm 361.36 \mu\text{m}$ , with the largest MLD being  $2406 \mu\text{m}$ . The mean basal diameter was  $1407.18 \pm 463.04 \mu\text{m}$  and mean Macular Hole Index (MHI) was  $0.66 \pm 1.00$ . Preoperative mean logarithm of the minimum angle of resolution (logMAR) visual acuity improved from  $1.27 \pm 0.28$  to  $0.79 \pm 0.30$  at 3 months postoperatively. There was significant improvement in visual acuity. Out of 32 patients 27 (85%) achieved type 1 macular hole closure. Five eyes (15%) showed good visual outcome despite having type 2 closure of MH.





**Conclusions:** Multilayered inverted internal limiting membrane flap technique contributes to improved anatomical and visual outcomes in the treatment of large macular holes. As compared to the conventional inverted ILM flap technique, multilayering provides a promising method in preserving the ILM flaps without causing unexpected flap dislodgment.

Dec 08, 2017 (Fri) 16:00 - 17:30

Venue: Room 304 & 305

### Outcomes After Cataract Surgery in Patients With Neovascular Age-Related Macular Degeneration

First Author: Mark **GILLIES**

Co-Author(s): Jennifer **ARNOLD**, Daniel

**BARTHELMES**, Vincent **DAIEN**, Rohan **ESSEX**, Vuong **NGUYEN**

**Purpose:** To evaluate the long-term changes in visual acuity (VA), choroidal neovascular (CNV) lesion activity, and frequency of anti-vascular endothelial growth factor (VEGF) injections after cataract surgery in patients with neovascular age-related macular degeneration (nAMD).

**Methods:** Treatment-naive phakic eyes with nAMD tracked using a prospective registry, commencing anti-VEGF therapy from January 1, 2006, with at least 12 months of follow-up prior to and following cataract surgery were considered. Three controls (phakic treatment-naive nAMD) per case were matched on the following characteristics to assess the effect of cataract surgery on the course of nAMD: treatment duration before cataract surgery, baseline VA and age, and length of follow-up.

**Results:** We included 556 eyes (139 cases and 417 controls). Eyes that underwent cataract surgery gained a mean [95% confidence interval (CI)] of 10.6 letters (95% CI: 7.9, 13.3;  $P < 0.001$ ) 12 months following surgery; 27.5% had gained  $\geq 3$  lines and 2.2% had lost  $\geq 3$  lines of VA. The proportion of visits where the CNV lesion was graded as active in the 12 months following cataract surgery was higher in eyes undergoing cataract surgery than in matched controls (49.4% vs 43.1%;  $P < 0.001$ ). Eyes undergoing

cataract surgery received more injections [mean (SD)] in the 12 months following surgery than their respective controls [5.5 (3.2) vs 4.9 (2.9);  $P = 0.009$ ].

**Conclusions:** Cataract surgery appears to be beneficial for eyes receiving intravitreal therapy for nAMD. Patients may require closer postoperative attention because their CNV lesion may become more active and need more frequent anti-VEGF treatment.

Dec 08, 2017 (Fri) 14:00 - 15:30

Venue: Room 304 & 305

### Outcomes After Intravitreal Bevacizumab Versus Laser Photocoagulation for Retinopathy of Prematurity: A 5-Year Retrospective Analysis

First Author: Tariq **ALI**

**Purpose:** To determine the relative effectiveness, major complications, and refractive errors associated with intravitreal bevacizumab (IVB) versus panretinal photocoagulation (PRP) to treat type 1 retinopathy of prematurity (ROP).

**Methods:** This was a retrospective case series. Consecutive infants with type 1 ROP who received either IVB or PRP and had at least 6 months of follow-up were included. The data from infants treated with either IVB or PRP for type 1 ROP between 2012 and 2016 were recorded from a tertiary hospital in Bangladesh.

**Results:** A total of 86 eyes (43 patients) with type 1 ROP were evaluated: 18 eyes (9 patients) received IVB, and 68 eyes (34 patients) received PRP. Among the 18 eyes treated with IVB, 12 eyes had zone I ROP and 6 eyes had posterior zone II ROP. The number of zone I and II ROP eyes treated with PRP were 10 and 58, respectively. There was no recurrence in any group. Mean spherical equivalent and post gestational age at the last refraction for IVB-treated eyes were -1.5 diopters (D) and 25.6 months, respectively, and for PRP-treated eyes, these were -4.5 D and 35.6 months, respectively. Mean spherical equivalent for





zone I ROP eyes treated with IVB and PRP were -2.8 D and -7.5 D, respectively, and for zone II ROP eyes, these were -1.5 D and -3.5 D, respectively.

**Conclusions:** Both IVB and PRP are effective treatment options for type 1 ROP with low complication rates. IVB was associated with less myopia than PRP, although longer follow-up was available for PRP.

**Dec 08, 2017 (Fri) 16:00 - 17:30**

**Venue: Room 304 & 305**

### Outcomes, Predictive Factors for Redetachment at 6 Months, and Comparison of EuroQol Quality of Life Index at Baseline and 6 Months Following Removal of Silicone Oil in Complex Retinal Detachment Repairs

*First Author: Thushara Katukurunde*

**KALUARACHCHIGE**

*Co-Author(s): Charith FONSEKA, Buddhika MAHESH*

**Purpose:** To assess the outcome and predictive factors for redetachment at 6 months and to compare quality of life (QOL) index at baseline and 6 months after removal of silicone oil (SIO) in complex retinal detachments (CRD).

**Methods:** A prospective study was done among 178 consecutive patients who underwent SIO removal in CRD repairs with SIO endotamponade. Each patient was followed up for 6 months from the day of SIO removal gathering data on retinal attachment, vision, and any complications. Baseline and 6-month QOL was assessed with EuroQol EQ-5D-3L tool. Selected associated factors identified in univariate analysis were subjected to multivariate analysis using logistic regression.

**Results:** The mean age (range) of the study population was 54.51 (16-82) years. Mean (SD) duration of SIO in the eye was 234.87 (177.552) days. The rate of retinal redetachment 6 months after SIO removal was 9.0% (n = 16 out of 177 eyes). A statistically significant difference was noted towards improvement in mean logarithm of the minimum angle of resolution (logMAR) vision, EQ-5D-3L index values, and

EQVAS values between baseline and 6 months (P = 0.001). In multivariate analysis with logistic regression after univariate analysis, the 3 factors detected as independently influencing retinal redetachment after SIO removal were VH within the first week (P = 0.007), GRT (P = 0.032), and SIO emulsification (P = 0.029) in this study.

**Conclusions:** Use of SIO as a tamponading agent in complex retinal detachments helped to preserve vision and keep redetachment rates at a lower level. Prevention of postoperative VH and hypotony following SIO removal would maintain the initial surgical success in complex retinal detachment repairs.

**Dec 08, 2017 (Fri) 08:30 - 10:00**

**Venue: Room 304 & 305**

### Ranibizumab With or Without Verteporfin Photodynamic Therapy for Polypoidal Choroidal Vasculopathy: Anatomical Outcomes Over 12 Months in the EVEREST II Study

*First Author: Timothy LAI*

*Co-Author(s): Tadhg GUERIN, Philippe MARGARON, Colin TAN*

**Purpose:** To report the anatomical outcomes at month 12 from the EVEREST II study.

**Methods:** EVEREST II was a 24-month, multicenter study in which 322 patients diagnosed with symptomatic polypoidal choroidal vasculopathy (PCV) were randomized to receive ranibizumab 0.5 mg plus verteporfin photodynamic therapy (vPDT; n = 168) or ranibizumab 0.5 mg monotherapy (n = 154). Anatomical parameters were assessed using spectral-domain optical coherence tomography at baseline, months 3, 6, and 12. The probability of achieving a fluid-free retina [absence of subretinal fluid (SRF), cysts, and intraretinal fluid] at month 12 was evaluated by logistic regression using 2 separate models at baseline and month 3. Possible predictive factors (demographic, ocular, anatomic, and angiographic parameters) were assessed using first a univariate model before inclusion in a backward selection multiple logistics regression







analysis.

**Results:** At month 12, the combination therapy group showed greater reduction in central subfield thickness (CSFT; least squares mean:  $-164.9 \mu\text{m}$  vs  $-113.4 \mu\text{m}$ ,  $P < 0.001$ ). At month 12, 56.8% and 28.7% of patients achieved fluid-free retina in the combination and monotherapy groups, respectively. Combination therapy [odds ratio (OR), 3.75 (baseline model) and 2.53 (month 3 model)] and absence of SRF at month 3 (OR, 3.90) were associated with a higher probability of achieving a fluid-free retina at month 12. In contrast, higher CSFT at baseline had a lower probability of fluid-free retina at month 12 (OR, 0.76/100  $\mu\text{m}$ ).

**Conclusions:** Combination therapy resulted in more beneficial anatomical outcomes than ranibizumab monotherapy. The results contribute to the understanding of the anatomical response of macular PCV to ranibizumab with or without vPDT.

Dec 08, 2017 (Fri) 08:30 - 10:00

Venue: Room 304 & 305

### Ranibizumab With or Without Verteporfin Photodynamic Therapy for Polypoidal Choroidal Vasculopathy: Predictors of Visual Acuity Gains in the EVEREST II Study

First Author: Gemmy **CHEUNG**

Co-Author(s): Tadhg **GUERIN**, Philippe **MARGARON**

**Purpose:** To assess the predictors of best-corrected visual acuity (BCVA) gains at month 12 in the EVEREST II study.

**Methods:** A 24-month, multicenter study in which 322 patients diagnosed with symptomatic polypoidal choroidal vasculopathy (PCV) were randomized to receive ranibizumab 0.5 mg plus verteporfin photodynamic therapy ( $n = 168$ ) or ranibizumab 0.5 mg monotherapy ( $n = 154$ ). We evaluated potential predictors of BCVA change at month 12, which included demographic, ocular, anatomic, and angiographic parameters at baseline and month 3. Each possible predictive factor was first assessed using a univariate model before inclusion along with

treatment group and the interaction of each factor with treatment group in the backward selection multiple linear regression analysis.

**Results:** At month 12 patients gained +8.3 letters and +5.1 letters in the combination and monotherapy arms, respectively ( $P = 0.013$ ). Younger age and lower BCVA were associated with higher BCVA gains at month 12 ( $-0.317$  letters/year,  $P = 0.0002$  and  $-0.233$  letters/letter at baseline). Combination therapy was associated with higher BCVA gains over monotherapy in patients with larger polyp size at baseline ( $+2.4$  letters/ $\text{mm}^2$  vs  $-6.9$  letters/ $\text{mm}^2$ ). For the model evaluating predictors at month 3, younger age, lower central subfield thickness, lower BCVA, and smaller branching vascular network size were associated with higher BCVA gains at month 12 ( $-0.226$  letters/year,  $P = 0.0002$ ;  $-1.80$  letters/100  $\mu\text{m}$ ,  $P < 0.0001$ ;  $-0.142$  letters/letter,  $P = 0.0001$ ;  $-0.524$  letters/ $\text{mm}^2$ ,  $P = 0.0084$ , respectively).

**Conclusions:** These findings contribute to the further understanding of the role of various demographic, ocular, anatomic, and angiographic parameters in the response of PCV lesions to treatment.

Dec 08, 2017 (Fri) 11:00 - 12:30

Venue: Room 304 & 305

### Small Gauge Vitrectomy for Advanced Diabetic Eye Disease: Outcome and Predictive Factors for Postoperative Poor Vision

First Author: Ainal Adlin **NAFFI**

Co-Author(s): Mae-Lynn **BASTION**, Norshamsiah **MD DIN**, Mushawiahti **MUSTAPHA**

**Purpose:** To evaluate anatomical and visual outcomes of sutureless small gauge vitrectomy for advanced diabetic eye disease (ADED) and to evaluate predictive factors for poor visual outcome.

**Methods:** Retrospective study of small gauge vitrectomy for ADED from 2009 to 2014. Data collected included demographic data, visual and anatomical outcomes, indications





for surgery, systemic associations, and postoperative complications. Poor visual outcome was defined as visual acuity worse than 6/36. Data was analyzed at 3, 6, and 12 months after surgery.

**Results:** A total of 158 eyes were analyzed from 133 patients. Malay ethnicity was 56.3%, Chinese was 31.6%, whereas Indian was 10.1%. Mean age was  $54.01 \pm 11.57$  years and mean duration of follow-up was  $9.9 \pm 3.7$  months. Small gauge system was used including 23G (86.1%) and 25G (13.9%). Indications for vitrectomy were vitreous hemorrhage (VH) (48.7%), tractional retinal detachment (TRD) (47.5%), and others (3.8%). At 1 year postoperation, 59.3% had visual improvement, 23.6% worsened, and 17.1% stabilized. Marked improvement of vision was seen in patients with VH (75.4%) as compared to patients with TRD (48.3%). More than 90% of cases achieved successful anatomical outcome in VH (98.2%) and TRD (96.7%). Predictive factors for poor visual outcome included presence of hypertension ( $P = 0.03$ ), use of heavy liquid intraoperatively ( $P = 0.045$ ), and silicone oil endotamponade ( $P = 0.005$ ). Postoperative complications were high intraocular pressure (44.1%), retinal detachment (17.6%), cystoid macular edema (14.7%), cataract (14.7%), VH (5.9%), and blindness (3.0%).

**Conclusions:** Small gauge vitrectomy provides excellent visual and anatomical outcomes in patients with ADED. Predictive factors for poor visual outcome were usage of heavy liquid, silicone oil endotamponade, and presence of systemic hypertension.

Dec 08, 2017 (Fri) 16:00 - 17:30

Venue: Room 304 & 305

### Spectral Domain OCT Imaging of the Fellow Eye of Idiopathic Full Thickness Macular Holes

First Author: Ramachandran NAIR

**Purpose:** To study the vitreomacular interface alterations (VMIA) and retinal changes in the

fellow eyes of eyes with idiopathic full thickness macular hole (FTMH).

**Methods:** The fellow eyes of 100 eyes with idiopathic FTMH were studied using the Macular Cube and 5 Line Raster program of the Cirrus high-definition (HD) optical coherence tomography (OCT) and compared with age- and sex-matched controls. High-definition analysis was done and features noted included retinal thickness, details of the outer retina, VMIA, surface contour changes, and reflectivity changes.

**Results:** Surface contour changes were seen in 62% of eyes. Inner segment, outer segment (IS-OS) junction was normal in 64% of eyes. Twelve patients had full thickness macular holes in the fellow eye while 15 eyes had lamellar defects. Epiretinal membranes were found in 28 eyes. Vitreous changes were studied and included no obvious posterior vitreous detachment (PVD) noted in 23 eyes, foveal adhesions in 37 eyes, and a complete PVD in 27 eyes. Disruption of the COST line was noticed in 36 eyes and ellipsoid zone damage was noted in 19 eyes.

**Conclusions:** The significant presence of VMIA, outer retinal, and surface contour changes in the fellow eyes of eyes with FTMH may be a result of a tendency of these eyes to have anomalous tractional forces and inherent macular weakness; a combination of these findings may help us predict the propensity of FTMH formation.

Dec 08, 2017 (Fri) 16:00 - 17:30

Venue: Room 304 & 305

### Strategy for the Treatment of Uncomplicated Retinal Detachment: Japan Retina Vitreous Society Registry System

First Author: Koichi NISHITSUKA

Co-Author(s): Akito HIRAKATA, Yuichiro OGURA, Taiji SAKAMOTO, Shuichi YAMAMOTO, Hidetoshi YAMASHITA

**Purpose:** To describe the real-world data of rhegmatogenous retinal detachment (RD) surgery from the Japan Retina Vitreous Society (JRVS) registry system.





**Methods:** Twenty institutes of JRVS committee members were selected as data collecting hospitals. All cases of RD treated in these hospitals were registered with the central data center through the internet system from February 2016 to May 2017. Six months of follow-up data of uncomplicated RD cases defined as grade 0 or grade A proliferative vitreoretinopathy were analyzed in this study.

**Results:** Of 1204 primary operations for uncomplicated RD, 826 (68.6%) were pars plana vitrectomy (PPV), 329 (27.3%) were scleral buckle (SB), and 49 (4.1%) were PPV with SB (PPV-SB). The RD reoperation rate was 8.36%, 6.69%, and 16.33% for PPV, SB, and PPV-SB, respectively. In phakic patients, there was no statistically significant difference in the reoperation rate between the vitrectomy group (PPV and PPV-SB) (n = 658) and the SB group (n = 313) (Fisher exact test: P = 0.89). In pseudophakic patients, there was also no statistically significant difference in the reoperation rate between the vitrectomy group (PPV and PPV-SB) (n = 204) and the SB group (n = 16) (Fisher exact test: P = 0.23).

**Conclusions:** Analysis of real-world data showed that uncomplicated RD cases were appropriately treated at 20 institutions of JRVS committee members. The JRVS registry system will become a powerful tool for clinical study.

Dec 08, 2017 (Fri) 11:00 - 12:30

Venue: Room 304 & 305

### Surgical Outcomes Following Inverted Internal Limiting Membrane Flap Versus Conventional Peeling for Very Large Macular Holes

First Author: Raja **NARAYANAN**  
Co-Author(s): Raj **APTE**, Kyoko **OHNO-MATSUI**, Sumit **SINGH**, Stanford **TAYLOR**

**Purpose:** To evaluate anatomical and visual outcomes of the inverted flap technique for peeling the internal limiting membrane (ILM) versus standard peeling of ILM for macular holes more than 800  $\mu\text{m}$ .

**Methods:** Patients with very large idiopathic or traumatic macular holes more than 800  $\mu\text{m}$  in diameter were included in the study. In group A, in 22 eyes of 22 patients the ILM was peeled using the inverted flap technique. In group B, 28 eyes of 28 patients underwent conventional ILM peeling. The primary endpoint was the rate of hole closure at 1 month following surgery. The secondary outcome measure was the change in baseline best corrected visual acuity (BCVA) following surgery.

**Results:** There were no significant differences in demographic or ocular characteristics of the study groups at baseline. Mean macular hole diameter was  $1262.9 \pm 347.6 \mu\text{m}$  and  $1462.0 \pm 615.1 \mu\text{m}$  in group A and group B, respectively. The hole closure rate was 86.3% (19/22) in group A and 75% (21/28) in group B (P = 0.47). The mean gain in BCVA was higher in group A than in group B (P = 0.004). There were no severe ocular adverse events in either group.

**Conclusions:** In this multicenter series, the inverted ILM flap technique did not lead to significantly higher anatomic closure rates than conventional ILM peeling in large macular holes more than 800  $\mu\text{m}$  in diameter.

Dec 08, 2017 (Fri) 11:00 - 12:30

Venue: Room 304 & 305

### Sustained-Release Dexamethasone (Ozurdex) Intravitreal Implant for Persistent Macular Edema After Epiretinal Membrane Peeling Surgery

First Author: Wen-Chuan **WU**  
Co-Author(s): Yo-Chen **CHANG**

**Purpose:** To investigate the functional and anatomical outcome of 0.7 mg dexamethasone intravitreal implant in eyes with long-term macular edema after macular epiretinal membrane (ERM) removal.

**Methods:** This retrospective consecutive case series presents the results of 0.7 mg dexamethasone (Ozurdex) intravitreal injection (IVD) for the treatment of persistent macular edema secondary to 25-gauge pars plana





vitrectomy with ERM and internal limiting membrane (ILM) peeling for idiopathic ERM.

**Results:** For eyes with Ozurdex injection (IVD group, 20 eyes), the mean best corrected visual acuity (BCVA) improved by 3.45 lines to 0.47 logarithm of the minimum angle of resolution (logMAR) in only 1 month after IVD. However, the mean BCVA improved by only 1.1 lines to 0.71 logMAR at the same time in eyes with persistent macular edema without Ozurdex injection (control group, 20 eyes). Thereafter, the BCVA decreased in slower motion. Six months later, the mean BCVA improved to 0.31 and 0.305 logMAR in the IVD and control groups, respectively. In the IVD group, central foveal thickness (CFT) decreased rapidly by 116.8  $\mu\text{m}$  to 333.9  $\mu\text{m}$  in only 1 month after IVD. Thereafter, the CFT decreased in slower motion. In the control group, CFT decreased gradually during the follow-up period. However, in the IVD group 6 months after IVD, CFT seems to have a tendency to increase.

**Conclusions:** A single IVD could significantly decrease macular edema and improve visual outcome for eyes with long-term macular edema after macular ERM removal and the effect can be sustained as long as 6 months after the initial injection. However, in order to maintain the visual and anatomical outcome, repeat IVD might be considered if macular edema recurred.

**Dec 08, 2017 (Fri) 11:00 - 12:30**

**Venue: Room 304 & 305**

### **Sutureless Intrasceral Posterior Chamber Intraocular Lens Fixation Under 27-Gauge Pars Plana Vitrectomy**

*First Author: Jiannan LIU*

*Co-Author(s): Shaomin PENG*

**Purpose:** To report a new technique for performing sutureless intrasceral fixation of a posterior chamber intraocular lens (PCIOL).

**Methods:** After the lens was extracted under a standard 3-port 27-gauge vitrectomy system, a 2.2-mm sclerocorneal incision and 2 precisely

180-degrees apart bilateral scleral dissections of 2 mm in length and about 0.5 mm thickness were made 1.75 mm from the limbus. At the bottom of the left incision and top of the right incision, 2 scleral punctures were made. After the 3-piece folded PCIOL was implanted, 2 haptics were taken out through the punctures. At the top of the left incision and bottom of the right incision, 2 3-mm counterclockwise scleral tunnels parallel to the limbus were prepared by a 29G  $\times$  1/2" needle bent at right angles. Finally, both haptics were pulled into the scleral tunnels, and the PCIOL position was centered. Thirty-seven aphakic eyes of 37 patients receiving the technique above were studied. The best-corrected visual acuity (BCVA), intraocular pressure (IOP), IOL tilt, and decentration were determined.

**Results:** Mean preoperative BCVA was  $1.66 \pm 1.26$  logarithm of the minimum angle of resolution (logMAR) units, and mean postoperative BCVA was  $0.76 \pm 0.61$  logMAR units at 3 months ( $P = 0.001$ ). Mean preoperative IOP was  $21.8 \pm 12.8$  mm Hg, and mean postoperative IOP was  $17.0 \pm 4.6$  mm Hg at 3 months ( $P = 0.001$ ). Mean PCIOL tilt was  $2.3 \pm 1.9$  degrees and decentration was  $0.4 \pm 0.2$  mm. There was no postoperative retinal detachment, endophthalmitis, PCIOL dislocation, or vitreous hemorrhage detected during the follow-up period.

**Conclusions:** The 27-gauge sutureless intrasceral PCIOL implantation technique with 29G  $\times$  1/2" needle minimizes intraoperative injury, simplifies the procedure, and provides good PCIOL fixation with few postoperative complications.



Dec 08, 2017 (Fri) 16:00 - 17:30

Venue: Room 304 & 305

### The Efficacy of 0.75% Levobupivacaine Versus 0.75% Ropivacaine With Fentanyl for Peribulbar Anesthesia in Vitreoretinal Surgery

First Author: Sushil **PATIL**

Co-Author(s): Sherine Marina **DZOUZA BRAGANZA**,  
M B **THIRUMALES**H, K Bhujang **SHETTY**

**Purpose:** To evaluate the anesthetic efficacy and akinesia in the pre- and postoperative period with 0.75% levobupivacaine versus 0.75% ropivacaine, both with the addition of fentanyl, for peribulbar anesthesia in patients undergoing primary vitreoretinal surgery.

**Methods:** We investigated 40 patients subjected to vitreoretinal surgery under peribulbar anesthesia and randomized into 2 equal groups with ropivacaine and fentanyl in group 1 and levobupivacaine and fentanyl in group 2. The patients were randomized according to the local anesthetic (LA) used: group 1, 0.75% levobupivacaine and group 2, 0.75% ropivacaine, both with the addition of hyaluronidase and fentanyl. Nerve block: 6–8 mL of LA using a single injection of percutaneous peribulbar anesthesia with a 23-gauge needle. Analgesia in the postoperative period was evaluated using the visual analog score (VAS).

**Results:** When compared with 0.75% ropivacaine, 0.75% levobupivacaine provided more successful akinesia at 2 minutes after block, fewer supplementary injections, and with less volume used. Levobupivacaine provided significantly longer motor block duration ( $236 \pm 74.5$  min versus  $172 \pm 59$  min) and longer sensory block duration ( $183 \pm 19$  min versus  $148 \pm 35$  min), when compared with ropivacaine. In the postoperative period from 4 to 12 hours, group 2 achieved lower VAS for pain.

**Conclusions:** Ropivacaine with fentanyl provided good akinesia at 0, 2, and 5 minutes compared to levobupivacaine, which provided significantly longer sensory block duration

(VAS). The number of repeat injections with ropivacaine was less than levobupivacaine. Akinesia with ropivacaine was better and volume of local anesthetic was less in ropivacaine. We conclude that, at equipotent doses and concentrations, 0.75% ropivacaine with fentanyl provided effective postoperative analgesia and immediate akinesia.

Dec 09, 2017 (Sat) 08:30 - 10:00

Venue: Room 304 & 305

### Comparative Study of the Efficiency of Subthreshold Micropulse Photocoagulation Combined With Intravitreal Injection of Conbercept for Macular Edema Secondary to Branch Retinal Vein Occlusion

First Author: Guangfeng **LIU**

**Purpose:** To assess the clinical effects and safety of subthreshold micropulse photocoagulation (SMP) combined with intravitreal injection of conbercept (ICI) for macular edema secondary to branch retinal vein occlusion (BRVO).

**Methods:** A total of 42 patients with vision loss attributed to macular edema following BRVO were retrospectively analyzed. Patients were enrolled in 2 groups. The ICI group (21 eyes) received 1 plus as needed (PRN) intravitreal injections of 0.05 mL (0.5 mg) conbercept. The ICI + SML group (24 eyes) received intravitreal injection of conbercept followed by subthreshold micropulse photocoagulation (SML). The best-corrected visual acuity (BCVA) and central macular thickness (CMT) were observed before and every month after treatment until the sixth month.

**Results:** BCVA was logarithm of the minimum angle of resolution (logMAR)  $0.61 \pm 0.31$  for the ICI group and  $0.62 \pm 0.29$  for the ICI + SML group before treatment;  $0.36 \pm 0.32$  for the ICI group and  $0.34 \pm 0.25$  for the ICI + SML group 6 months after treatment. The difference was not statistically significant between the 2 groups ( $t = 0.43$ ,  $P > 0.05$ ). CMT was  $501.38 \pm 102.80$   $\mu$ m for the ICI group and  $488 \pm 92.69$   $\mu$ m for the ICI + SML group before treatment;  $236.01 \pm 43.47$   $\mu$ m



for the ICI group and  $222.29 \pm 46.37 \mu\text{m}$  for the ICI + SML group 6 months after treatment. The difference was not statistically significant between the 2 groups ( $t = 0.51, P > 0.05$ ). The average number of intravitreal treatments was  $1.85 \pm 0.93$  in the ICI group and  $1.41 \pm 0.81$  in the ICI + SML group; the difference was statistically significant between the 2 groups ( $t = 0.68, P < 0.05$ ).

**Conclusions:** At the 6-month follow-up, both ICI and ICI + SML provided significant functional and anatomical improvement; combination with SML can reduce the frequency of ICI treatment. SML might be a useful approach in the treatment of ME secondary to BRVO.



## POSTERS

### Intraocular Inflammation, Uveitis & Scleritis

Poster No.: EX1-001

#### **Klebsiella Endogenous Endophthalmitis: A Review of Cases**

First Author: Jane **FOO**

Co-Author(s): Jay **CHANDRA**, Adrian **T FUNG**

**Purpose:** To describe cases of *Klebsiella* endogenous endophthalmitis from a large tertiary referral hospital in western Sydney.

**Methods:** Retrospective chart review. Cases of endophthalmitis with systemic *Klebsiella pneumoniae* infection were identified at Westmead Hospital, Sydney, Australia between 2000 and 2017.

**Results:** Three cases of presumed *Klebsiella* endogenous endophthalmitis were identified, ranging in age from 58 years to 81 years. All had *Klebsiella pneumoniae* liver abscesses requiring drainage. In 2 cases the pathogen was resistant to ampicillin. Presenting vision ranged from hand movements to light perception, and symptoms included ocular pain, redness, fever, rigors, syncope, and abdominal pain. Two patients had diabetes mellitus, and none described recent travel. All patients underwent vitreous tap and intravitreal antibiotics with vancomycin 1 mg/0.1 mL and ceftazidime 2.25 mg/0.1 mL. All cases had negative vitreous biopsies. Two patients underwent early small-gauge pars plana vitrectomy, but despite this 1 progressed to inoperable total retinal detachment after 1 month and the other to no light perception within 4 days. The third patient had extramacular retinitis and vitritis. After 3 intravitreal injections of vancomycin and ceftazidime, the infection was controlled without the need for vitrectomy and vision recovered to 6/18 after 2 months.

**Conclusions:** *Klebsiella* endogenous endophthalmitis is an aggressive disease that is becoming increasingly prevalent in Australia.

The yield from vitreous biopsies can be low, with the diagnosis being made on microbial culture of systemic disease that often involves the liver. Although early vitrectomy is often required, some cases may respond to repeated intravitreal antibiotics alone.

Poster No.: EX1-002

#### **A Case of Ampiginous Choroiditis**

First Author: Seunghee **LEE**

Co-Author(s): Hyungu **KANG**

**Purpose:** Ampiginous choroiditis is a primary inflammatory choriocapillaropathy with characteristics of both acute posterior multifocal placoid pigment epitheliopathy (APMPPE) and serpiginous choroiditis. We describe a case of unilateral ampiginous choroiditis in a young male.

**Methods:** A 15-year-old boy was referred to our clinic for complaints of decreased visual acuity and visual field defect. He had a visual acuity of 20/20 in the affected eye and intraocular pressure was normal. Slit-lamp examination showed mild anterior chamber inflammation. The fundus examination revealed unilateral scattered whitish chorioretinal lesions. Fluorescein angiography demonstrated these lesions to be early hypofluorescent with late hyperfluorescent staining of the borders. An optical coherence tomography scan through these lesions displayed outer retinal atrophy. Ophthalmologic examination of the left eye was unremarkable. Laboratory work-up and chest radiography showed no abnormality.

**Results:** The acute retinal lesions were similar to those of APMPPE at first. However, 1 month after tapering medication, we found older healed pigmented lesions accompanied by new lesions and enlargement of previous lesions. Subsequently, the multifocal pattern of the lesions, angiographic features, and progression of the disease led to the diagnosis of ampiginous choroiditis. We started cyclosporine



with prednisone to control activity and prevent recurrence of inflammation.

**Conclusions:** Ampiginous choroiditis has overlapping clinical features that make it difficult to characterize, having atypical clinical appearance and course of both APMPE and serpinginous choroiditis. Some lesions had initial features of APMPE but showed progression towards serpinginous choroiditis during follow-up. Therefore, to prevent misdiagnosis, thorough workup and close follow-up is essential.

---

**Poster No.:** EX1-003  
**Akurit 4 Related Toxic Neuropathy**  
*First Author: Nur Aliah HASSAN*

**Purpose:** To report a case of rapid onset of bilateral toxic neuropathy related to Akurit 4.

**Methods:** A case report.

**Results:** A 15-year-old Malay girl with a known case of pulmonary tuberculosis (TB) presented with a history of sudden onset blurring of vision of both eyes for 1-week duration following 2 months of anti-TB treatment. It was associated with occasional headache. Visual acuity in both eyes was counting fingers with no relative afferent pupillary defect. The optic discs were pink, with cup-disc ratio of 0.3. Intraretinal flame-shaped hemorrhages were seen in both eyes. Computed tomography of the brain/orbits were normal. She was seen again by the respiratory team and ethambutol was withheld. She had no other risk factors. Her visual acuity slightly improved (right eye 6/18 PH 6/18, left eye 6/36 PH 6/36) 4 months after discontinuation of ethambutol.

**Conclusions:** Ethambutol is a common drug prescribed in patients with tuberculosis, which causes rare yet significant ocular toxicity. However, the mechanism of toxicity is still under investigation. The visual outcome is variable.

---

**Poster No.:** EX1-004  
**Disc Neovascularization in Vogt-Koyanagi-Harada Disease: A Case Report**

*First Author: Jennifer Joy SANTOS-RAYOS*

**Purpose:** To report a case of Vogt-Koyanagi-Harada (VKH) disease with neovascularization at the disc.

**Methods:** This is a retrospective and descriptive case report based on data from clinical records, patient evaluation, and diagnostics tests.

**Results:** A 22-year-old female presented with decreased vision for 8 weeks. Vision in both eyes was counting fingers at 5 ft. Pupillary function and intraocular pressure were unremarkable. Anterior segment examination showed granulomatous keratic precipitates, +4 cells, and posterior synechiae. The fundus appearance demonstrated bilateral disc edema and bilateral exudative retinal detachment. She was treated with topical and oral steroids. After 7 weeks, anterior chamber inflammation and exudative retinal detachment resolved, but there was new onset optic disc neovascularization. The patient was treated with multiple intravitreal bevacizumab injections, which resulted in resolution of the disc neovascularizations.

**Conclusions:** Combined treatment of systemic steroids and intravitreal bevacizumab are effective for optic disc neovascularization associated with VKH.

---

**Poster No.:** EX1-005  
**Ocular Meliodosis: The Diagnostic Dilemma**  
*First Author: Nur Nadia AHMAD TARMIZI*  
*Co-Author(s): Rosiah MUDA, Nor Anita CHE OMAR, Zuraidah MUSTARI*

**Purpose:** To report a case of presumed bilateral ocular meliodosis in an immunocompetent patient.

**Methods:** Case study.

**Results:** A 55-year-old Malay man with underlying hypertension presented with left eye sudden, painless, nonprogressive blurring





of vision for 2 days that was preceded by fever. Visual acuity was 6/6 and 6/12 in the right and left eyes, respectively. Examination of both eyes revealed normal anterior segment with no sign of anterior uveitis. There were multiple small choroiditis with splinter hemorrhage and exudates at the macula with surrounding macular edema in the left eye. This was confirmed by optical coherence tomography (OCT) of the macula showing presence of subretinal fluid and cystoid macular edema. Fundus examination of the right eye on initial presentation was unremarkable. Unfortunately, similar chorioretinal lesion was seen in the right eye 3 weeks later. There was no systemic involvement and all infective screening did not show any positive result except melioidosis serology, which came back as positive with a titer of 1:640. The patient was treated as ocular melioidosis and given 2 weeks of intravenous ceftazidime 2 g 3 times per day followed by oral trimethoprim and sulphamethoxazole (Bactrim) 960 mg 2 times per day. He responded well to treatment and had significant good visual recovery.

**Conclusions:** Ocular melioidosis is a rare and emerging cause of uveitis in Malaysia. However, the presentation may not be revealed systemically despite extensive work-up, hence the dilemma in forming an accurate diagnosis and giving appropriate treatment. A high index of suspicion is very important in managing this kind of case.

---

**Poster No.: EX1-006**

**Prognostic Factors for Successful Treatment in Patients With Ocular Tuberculosis**

*First Author: Puttiya KAEWKORN*

*Co-Author(s): Somsiri SUKAVATCHARIN*

**Purpose:** To determine prognostic factors associated with successful treatment in ocular tuberculosis patients.

**Methods:** A 5-year retrospective cross-sectional study. Patients with presumed or definite ocular tuberculosis were reviewed and evaluated regarding demographics, host status, history of tuberculosis exposure, extraocular

tuberculosis, erythrocyte sedimentation rate (ESR), C-reactive protein (CRP), tuberculin skin test (TST), QuantiFERON (QFT), chest radiology abnormalities, initial visual acuity (VA), ocular findings, optical coherence tomography (OCT), fluorescein angiography (FFA) findings, time from diagnosis to treatment, duration of treatment, and treatment options.

**Results:** There were a total of 51 patients (77 eyes) with presumed or definite ocular tuberculosis who had successful outcome in 74 eyes (96.1%). Patients with successful treatment had initial VA  $\geq$  20/200 (53 eyes, 71.6%), ESR  $<$  60 mm/hr (73 eyes, 98.65%), no complication from uveitis (51 eyes, 68.92%), and no extraocular tuberculosis (73 eyes, 98.65%). Any ocular findings including retinal vasculitis, choroiditis, retinitis, papillitis, and choroidal granuloma were not significantly associated with treatment outcome.

**Conclusions:** Patients with initial VA  $\geq$  20/200 and ESR  $<$  60 mm/hr were associated with successful treatment in cases of ocular tuberculosis, whereas patients with extraocular tuberculosis and complications were associated with treatment failure.

---

**Poster No.: EX1-007**

**The Prognostic Factors of Infectious Endophthalmitis Over the Past Decade**

*First Author: Eunyong CHOI*

*Co-Author(s): Min KIM*

**Purpose:** To investigate the prognostic factors of infectious endophthalmitis (IE) in Korea over the past 10 years (2007-2016).

**Methods:** Medical records from 2 large tertiary medical institutions were analyzed for etiology, treatment types, and visual outcomes.

**Results:** Among 171 total cases of IE, 70.8% occurred after intraocular surgery, 21.6% endogenously, and 5.3% after trauma. *Staphylococcus aureus* was the major pathogen in both endogenous and postoperative cases, and 71.8% showed multidrug resistance. Higher resistance was associated with worse final visual acuity ( $P = 0.027$ ). Gram-negative bacterial



cases had the poorest outcomes compared to other culture-positive cases ( $P = 0.011$ ). Higher visual outcomes were reported when treatment was started within 2 days after the onset ( $P = 0.049$ ). Eyes treated with vitrectomy primarily showed better visual prognosis than eyes that received injections before vitrectomy ( $P = 0.037$ ).

**Conclusions:** Early vitrectomy would help in successful treatment of IE that is expected to have poor visual prognosis.

---

**Poster No.: EX1-069**

**A Case of Primary Central Nervous System Lymphoma With Ciliary Body Involvement**

*First Author: Mengda LI*

**Purpose:** Ciliary body lymphoma is extremely rare with few reports published previously. We report a case of primary central nervous system lymphoma (PCNSL) with ciliary body involvement in a young Chinese man.

**Methods:** A 25-year-old male presented with projectile vomiting in March 2010. Brain magnetic resonance imaging (MRI) revealed multiple hyperintensive lesions on T1-weighted imaging. He was diagnosed as primary central nervous system lymphoma (diffuse large B-cell) by brain biopsy. He had blurred vision in the left eye 2 years later with mild anterior inflammation and diffuse vitreous opacification. Ultrasound biomicroscopy (UBM) revealed lesions of the ciliary body.

**Results:** The diagnosis of ciliary body lymphoma was made by vitreous cytology and flow cytometry. The patient showed a good response to systemic chemotherapy, brain, and ocular radiotherapy and is still alive at 8 years of follow-up.

**Conclusions:** We encountered a case of PCNSL with ciliary body involvement in a young male successfully treated with a combined therapeutic strategy. This case reiterates the fact that prompt diagnosis along with combined treatments may ultimately improve survival time.

---

**Poster No.: EX1-070**

**Multimodal Correlation With Adaptive Optics Imaging in Choroiditis**

*First Author: Rajeev PAPPURU*

*Co-Author(s): Ruchi CHOUDHARY, Utkarsha DASAMANTARAO, Sanjay KUMAR, Mudit TYAGI, Kiran VUPPARABOINA*

**Purpose:** To correlate adaptive optics images with various imaging modalities in choroiditis.

**Methods:** Adaptive optics scanning light ophthalmoscopy (AOSLO), swept-source optical coherence tomography (SS-OCT), and fundus autofluorescence (FAF) were performed in a patient with active and healed multifocal choroiditis. AOSLO system was used to simultaneously collect confocal and split-detector images. Montaged AOSLO images were analyzed after coregistration with FAF and SS-OCT images.

**Results:** Areas of defects in photoreceptors on AOSLO were correlated with outer retinal damage on SS-OCT and hypoautofluorescence on FAF. Areas of increased AOSLO signal corresponded to hyper-FAF signal. Multiple clumps of disorganized photoreceptors were noted in correlation with small hyperreflective spots on SS-OCT in photoreceptor layers. In addition, multiple high signal strength dots were noted on AOSLO at the photoreceptor level.

**Conclusions:** Multimodal correlation with AOSLO images helped to reveal many features which were previously not reported. Greater understanding of the dynamic changes in AOSLO signals in various stages of the disease will help to further explore the pathogenesis of choroiditis.

---

**Poster No.: EX1-073**

**Successfully Treated Concomitant Worm and Bartonella spp Infection of the Eye: A Case Report**

*First Author: Siti Khadijah ABDUL RAHMAN*

*Co-Author(s): Nor Azita AHMAD TARMIDZI, Norwazilah MOHD ANSUL, Azhany YAAKUB*

**Purpose:** To report a case that was initially





treated as diffuse unilateral subacute neuroretinitis but turned out to be concomitant infection with cat scratch disease.

**Methods:** Retrospective case report.

**Results:** A 35-year-old Malay woman who was apparently healthy presented with left eye pain, redness, and reduced vision since 1 week prior. Initially she was treated for conjunctivitis by a general practitioner before seeing an ophthalmologist. At presentation, her left eye vision was 5/60 with granulomatous anterior uveitis and high intraocular pressure (IOP) of 32 mm Hg. There was disc swelling, mild vitritis, and a small subretinal nodule near the macula. She was started on IV acetazolamide 500 mg and converted to T acetazolamide 250 mg 4 times per day, gutt latanoprost ON, and gutt timolol BD to control her IOP. She was also started on gutt dexamethasone 2 hourly and later in tapering dose. Her serial fundus photo showed migratory tract and she was clinically diagnosed as diffuse unilateral subacute neuroretinitis. Focal laser was done on migratory tract and T albendazole 400 mg OD given for 6 weeks. Besides that, uveitis work-up came back as positive serological test for *Bartonella* spp and she was diagnosed as cat scratch disease. She was treated with T doxycycline (100 mg twice a day) for 6 weeks. Upon completion of the antibiotics, her vision improved back to 6/9, steroid was tapered off, and her IOP controlled at 20 mm Hg with gutt Xalatan and gutt timolol.

**Conclusions:** Concomitant eye infections may complicate the clinical presentation but with prompt management, sight-threatening conditions can be avoided.

Poster No.: EX1-074

### Serology-Negative *Toxoplasma* Granuloma: Are They Really Rare Today?

First Author: Mayuresh **NAIK**

Co-Author(s): Brahmprakash **GULIANI**, Sandeep **KUMAR**, Anurag **NARULA**

**Purpose:** To highlight the role of clinical suspicion in a case of serology-negative

*Toxoplasma* granuloma.

**Methods:** A 25-year-old male presented with gradually progressive painless diminution of vision in the right eye. Best corrected visual acuity (BCVA) was 6/60 Snellen. Indirect ophthalmology showed an elevated lesion, about 2 DD diameter, along the inferotemporal arcade, inferotemporal to the macula with some evidence of perivasculitis along the arcade and overlying vitritis as well as resultant macular edema. Macular optical coherence tomography (OCT) showed a retinochoroidal lesion suggestive of a unilateral posterior pole granuloma. Serum IgM and IgG *Toxoplasma* were negative. Mantoux test was 30 x 30 mm, ESR was 32 mm at 1 hour, but chest X-ray and high-resolution computed tomography (HRCT) of the chest were unremarkable. Serum BACTEC results were negative. Additionally, serum ACE and calcium levels were within normal limits. The patient did not consent for vitreous tap for serological investigations. Hence, on the basis of strong clinical suspicion, a diagnosis of *Toxoplasma* posterior pole granuloma was made. The patient was given a combination of cotrimoxazole-pyrimethamine supplemented with a posterior subtenon injection of triamcinolone after a week.

**Results:** The patient was monitored for improvement in visual acuity and resolution of retinochoroidal thickening. Macular OCT showed dramatic improvement in retinochoroidal thickening at each weekly follow-up. Treatment was continued for 10 weeks and there has been no recurrence after 6 months of follow-up.

**Conclusions:** A high index of clinical suspicion is required to arrive at a diagnosis of *Toxoplasma* in cases of unilateral painless progressive diminution of vision, with a clinically evident retinal elevated lesion showing a granuloma on imaging modalities, especially in serology-negative cases.





Poster No.: EX1-076

### Tuberous Sclerosis and the Ophthalmological Work-Up: Can a Peripapillary Astrocytoma Masquerade as Myelinated Nerve Fibers?

First Author: Sandeep **KUMAR**

Co-Author(s): Brahmprakash **GULIANI**, Mayuresh **NAIK**, Anurag **NARULA**

**Purpose:** To highlight the role of optical coherence tomography (OCT) and ultrasound biomicroscopy (UBM) in the ophthalmological work-up of tuberous sclerosis.

**Methods:** A 5-year-old male, a diagnosed case of tuberous sclerosis, was referred from the department of pediatrics for an ophthalmological work-up. Unaided visual acuity (UCVA) was 6/6 Snellen. Indirect ophthalmoscopy showed a peripapillary lesion, about 2 DD diameter, involving the superior arcade that led to a preliminary assumption of myelinated nerve fibers. Peripheral retinal scan was negative. However, macular OCT showed a retinochoroidal lesion suggestive of a retinal astrocytoma. Macular OCT with enhanced depth imaging (EDI) showed the lesion to be a well-defined solitary mass lesion without distortion of the surrounding retinochoroid complex without any edema or any activity. Further, UBM showed that the lesion involved only the retinochoroidal complex without extending or involving the sclera and no evidence of calcification.

**Results:** A diagnosis of retinal astrocytoma concurrent with the systemic diagnosis of tuberous sclerosis was made and the patient has now been kept on follow-up.

**Conclusions:** A high index of clinical suspicion is not only required but also imperative in phacomatoses with ophthalmic involvement so that our armamentarium of newer imaging modalities can be put to good use to rule out masquerading lesions and arrive at a correct diagnosis, irrespective of the systemic or ophthalmic management and prognosis.

Poster No.: EX1-077

### A Case Report on Reactivation of Ocular Tuberculosis

First Author: Nurul Shima **ISMAIL**

Co-Author(s): Kiet Phang **LING**, Haslina **MOHD ALI**, Nik Nurfarhana **NIK MOHD NOOR**, Wee Min **TEH**

**Purpose:** To report a rare case of ocular tuberculosis (TB) reactivation in a young, healthy man.

**Methods:** Case report.

**Results:** A 23-year-old man with no underlying medical illness had a history of right ocular TB. That time, he presented with right eye progressive painless blurring of vision associated with cough and low-grade fever. Examination revealed hand movement vision, moderate anterior chamber reaction, and vitritis. Fundus showed granulomatous lesion over superotemporal retinal vessels with surrounding subretinal fluid and tortuous vessels. He had completed 1 year of anti-TB treatment in 2011 with residual quiescent granulomatous lesion over the superotemporal vessels. It was also complicated with localized retinal detachment due to inferior break. Barricade laser and scleral buckle was done in 2012. Subsequently he defaulted follow-up and presented again in April 2017 with right eye discomfort and tearing. Examination revealed vision of 1/60, which was about the same since his last follow-up. Anterior segment was quiet but fundus showed increasing size of previous granulomatous lesion with new dilated, tortuous vascularization over it. Investigations done were suggestive of reactivation of ocular TB; hence, he was restarted on anti-TB treatment.

**Conclusions:** Reactivation of ocular TB itself is very rare but the rise in pulmonary TB recurrence raises the possibility of an increasing number of ocular complications as secondary spread. The diagnosis of ocular TB reactivation is made with a high index of suspicion with the aid of several investigations. The regimen for ocular TB reactivation is still not well established; hence, comanagement with the chest physician is necessary.



Poster No.: EX1-078

### Case Report: Two Patients With Multiple Evanescent White Dot Syndrome

First Author: Arya **PRADIPTA**

Co-Author(s): Angela Nurini **AGNI**, Muhammad Bayu **SASONGKO**, Nisita **SURYANTO**, Tri Wahyu **WIDAYANTI**

**Purpose:** Multiple evanescent white dot syndrome (MEWDS) is a rare disease that commonly presents as grey-white dots at the posterior pole of the retina and unusual transient foveal granularity. Visual signs mostly present unilaterally with predisposition for females in the second to fifth decade. The aim of this study is to report 2 patients with MEWDS presenting with classic pathology on the retina.

**Methods:** A case report.

**Results:** The first patient was a 54-year-old female with sudden onset of blurred vision, photopsia, and a "grey area" in her central vision. There was no history of ocular trauma or previous ocular surgery. Initial examination found white dots scattered around the 4 quadrants within the midperipheral retina. Amsler grid exam revealed a central scotoma and optical coherence tomography (OCT) of the macula was normal. We prescribed oral steroids. On follow-up, the symptoms and signs improved. The second patient, a 47-year-old female, presented with sudden blurred vision in her right eye. On examination we found grey-white dots on the posterior pole. Laboratory exams were normal. Visual field test showed a general visual depression. After a week of observation, the fundus appearance improved.

**Conclusions:** The uncommon syndrome known as MEWDS must be considered when the common symptoms of scotoma and decreased vision, combined with the typical presentation of white spots in the fundus, appear in a healthy female patient.

Poster No.: EX1-079

### Intraocular Lymphoma

First Author: Mohd Anash **PATHAN**

Co-Author(s): Roshan **COLACO**, Sundaram **NATARAJAN**, Chaitali **BHAVSAR**, Gauri **KHARE**

**Purpose:** To confirm the diagnosis of dense vitritis secondary to intraocular lymphoma.

**Methods:** An 81-year-old female patient presented with a history of diminution of vision (DOV) in both eyes for 3 months. She was diagnosed with active choroiditis elsewhere following which she was started on topical steroids and vision improved to 6/6 in the left eye (LE). She again had DOV in the LE when she was diagnosed with vitritis with multiple elevated white cheesy clumps in the same eye. On the day of presentation her vision was 6/18P in the right eye (RE) and counting fingers at 2 m in the LE. Intraocular pressure (IOP) was 17 mm Hg in both eyes. On examination the patient was pseudophakic in both eyes. On posterior segment examination there was vitritis in both eyes with raised choroiditis in the left eye (OS). B-scan in both eyes (OU) was suggestive of vitritis with complete posterior vitreous detachment (PVD) and retina, choroid, and sclera (RCS) thickening in the right eye (OD), 2.33 and OS, 2.55. Fundus fluorescein angiography (FFA) revealed hyperfluorescence increasing in later phases temporal to the macula; multiple leakage points noted OD with hazy media and late leakage. LE vitreous aspirate was taken. Histopathological examination was suggestive of intraocular lymphoma but did not reveal any malignant cells. Right eye vitreous biopsy was suggestive but not conclusive of lymphoma. Then LE 27G vitreous biopsy and fluid-gas exchange were done.

**Results:** After surgery vitreous was clear in both eyes and choroidal lesions started regressing elsewhere except at the macula. The patient was continued on topical steroids following which even the macular lesions regressed.

**Conclusions:** Intraocular lymphoma as cause of dense vitritis in this patient was proved and was



successfully managed.

Poster No.: EX1-080

### Ocular Syphilis: Resurgence of an Old Disease in Modern Malaysian Society

First Author: Zakaria **ABDOLLAH**

Co-Author(s): Amin **AHEM**, Mae-Lynn **BASTION**, Hazlita **MOHD ISA**, Mushawiahti **MUSTAPHA**

**Purpose:** To present a case series of 4 young otherwise healthy adult males who presented with a spectrum of ophthalmic complaints and were subsequently diagnosed with ocular syphilis and HIV infection. Upon further history taking, high-risk behavior in the form of men who have sex with men (MSM) was elicited from each patient.

**Methods:** Retrospective case series.

**Results:** We summarize the course of 4 healthy young adult males ranging in age from 22 to 30 from various Malaysian ethnic backgrounds who recently presented to us with various nonspecific eye complaints including itchiness, blurring of vision, central scotoma, and floaters. Ocular examination revealed panuveitis in 3 patients and retinal detachment in 1 case. All cases showed a raised erythrocyte sedimentation rate, positive VDRL/RPR for syphilis, and positive HIV serology. All patients gave history of MSM. This case series highlights this particular high-risk sexual behavior and the wide range of nonspecific presenting ocular complaints that may be encountered. Three patients received neurosyphilis treatment regimen of intravenous benzylpenicillin with immunosuppressive steroid therapy. All 3 responded well to conventional treatment with improvement of vision and symptoms. One case was referred to another hospital for further management. All cases were co-managed with the infectious disease physician and included counseling and contact-tracing.

**Conclusions:** This case series alerts ocular practitioners to the reemergence of ocular syphilis seen in a small but significant group of Malaysian patients with common risky sexual behavior. A high degree of clinical suspicion is

required for early detection of this disease and to prevent its spread.

Poster No.: EX1-081

### Rapid Resolution of Occlusio Pupillae Using Intracameral Tenecteplase in a Patient With Severe Anterior Uveitis: A Case Report

First Author: Wen Yee **LEE**

Co-Author(s): Kiet Phang **LING**, Haslina **MOHD ALI**, Norlina **MOHD RAMLI**, Wee Min **TEH**

**Purpose:** To report on the successful use of intracameral tenecteplase for rapid dissolution of intraocular fibrin in severe acute anterior uveitis.

**Methods:** Case report.

**Results:** A 28-year-old Malay man presented with right eye sudden decrease in vision, associated with pain, redness, and photophobia. He had also experienced on and off right-sided lower backache in the past 2-3 years. Examination revealed poor vision (hand movements) in the right eye, while left eye vision was 6/9. There was severe fibrinous exudation obscuring the pupil and multiple clumps of fibrin inferiorly, with near 360-degree posterior synechiae as well. Fundus examination was not possible, but a B-scan showed clear vitreous without scleral thickening or retinal detachment. Musculoskeletal examination revealed a positive FABER test of the right hip. A clinical diagnosis of severe acute anterior uveitis likely associated with HLA-B27 was made. He was initially treated with frequent topical steroid eye drops as well as subconjunctival injection of mydracaine, without much improvement. He then received 1 dose of intracameral tenecteplase (50 mcg/0.1 mL), which resulted in complete fibrin resolution as well as synechiolysis within 3 days. Right eye vision improved to 6/9. No adverse events occurred after the injection.

**Conclusions:** Tenecteplase was effective and safe as a fibrinolytic agent for rapid resolution of intraocular fibrin in severe acute anterior uveitis. There was also an added effect of posterior synechiolysis as well in this case,





likely because of the acute presentation and treatment.

Poster No.: EX1-133

### A Rare Case of Iatrogenic Broken Intralenticular Ozurdex Implant

First Author: Yong Zheng **WAI**

Co-Author(s): Jun Fai **YAP**, Lik Thai **LIM**, Qi Xiong **NG**

**Purpose:** To report a case of iatrogenic broken intralenticular Ozurdex implant in a uveitis patient.

**Methods:** An ophthalmic trainee performed Ozurdex intravitreal injection under aseptic conditions. The patient was then followed up for further management.

**Results:** On day 7 after the procedure, slit lamp examination revealed the injected implant was actually injected into the intralenticular structure and had broken in 2 pieces and breached the posterior capsule, with one half stuck at the entry and the other half stuck at the exit wound of the posterior capsule. This patient underwent cataract extraction and removal of the fractured implant and made an uneventful recovery.

**Conclusions:** Clinicians should be aware of the potential risk of injecting the implant into an anatomical structure other than the vitreous cavity. Adequate training and careful administration of the Ozurdex implant are necessary to avoid such complications, which fortunately are rare.

## Retina (Medical)

Poster No.: EX1-008

### Adaptive Optics Imaging in Central Serous Chorioretinopathy: A Multimodal Analysis

First Author: Jay **CHHABLANI**

Co-Author(s): Hitesh **AGRAWAL**, Vivek **DAVE**, Sanjay **KUMAR**, Raja **NARAYANAN**, Ashutosh **RICHARIYA**

**Purpose:** To correlate adaptive optics findings with various imaging modalities in central serous chorioretinopathy (CSCR).

**Methods:** Adaptive optics scanning light

ophthalmoscopy (AOSLO), swept-source optical coherence tomography (SS-OCT), and fundus autofluorescence (FAF) were performed in a patient with resolved CSCR. AOSLO system was used to simultaneously collect confocal and split-detector images. Montaged AOSLO images were analyzed after coregistration with FAF and SS-OCT images.

**Results:** AOSLO images showed hyperreflective clumps in correspondence with small hyperreflective dots in SS-OCT. Large hyperreflective areas with photoreceptors were noted in correspondence with the small pigment epithelial detachment on SS-OCT. Patches of photoreceptor loss were noted in correlation with en-face images of SS-OCT. Increased spacing between the photoreceptors was noted along with hyperreflective spots at the level of inner nuclear layers on AOSLO images.

**Conclusions:** Multimodal correlation with AOSLO images showed a variety of features correlating with multimodal imaging along with inner retinal layer changes in CSCR. Further exploration of various layers on AOSLO images may expand the understanding of CSCR.

Poster No.: EX1-009

### An Unusual Presentation of Retinal Sheen: Muller Cell Sheen Dystrophy

First Author: Dr **HAEMOGLOBIN**

Co-Author(s): Naresh **BABU**, Sr **RATHINAM**

**Purpose:** To report a rare case of sheen retinal dystrophy called Muller cell sheen dystrophy and to describe its clinical and diagnostic aspects.

**Methods:** A 42-year-old woman presented with diminished vision and unusual bilateral fundus reflexes. Routine evaluation and investigations were performed.

**Results:** A 42-year-old woman presented with unilateral diminution in vision. Best corrected visual acuity was 6/12 in the right eye and 6/6 in the left. Fundus evaluation revealed bilateral glistening retinal reflexes throughout the posterior pole with a wrinkled





appearance in the right. She underwent routine work-up. Spectral domain optical coherence tomography (OCT) in the right showed abnormal internal limiting membrane, schitic spaces between internal limiting membrane and nerve fiber layer, and intraretinal schisis with serous detachment at the macula.

Angiography revealed staining along small vessels. Ultrasonography demonstrated mild retinochoroidal thickening. Electroretinogram in the affected eye was negative. Left eye was normal except for glistening reflexes. Systemic investigations demonstrated no inflammatory cause. A course of oral steroids showed no improvement. At 4 months of follow-up, vision dropped to 6/36. Intraretinal schisis increased with a new area of serous detachment temporally. Family screening was negative.

**Conclusions:** Here we report a rare case of sheen retinal dystrophy described as Muller cell sheen dystrophy, otherwise known as familial internal limiting membrane dystrophy. A primary defect in Muller cells is the most probable cause. Very few case reports exist in the literature. Visual loss is predominantly due to macular schisis with serous detachment. Although the clinical diagnosis is certain, an effective treatment still remains a dilemma.

---

**Poster No.: EX1-010**

**Analysis of Correlative Factors of Visual Acuity With Intravitreal Conbercept Injection in Macular Edema Associated With Branch Retinal Vein Occlusion**

*First Author: Wenjuan LUO*

**Purpose:** To evaluate the correlative factors of best-corrected visual acuity (BCVA) with intravitreal conbercept injection in macular edema secondary to branch retinal vein occlusion (BRVO).

**Methods:** This was a self-controlled retrospective study. Thirty eyes of 30 patients with macular edema secondary to BRVO were enrolled. After an initial intravitreal injection of conbercept (0.5 mg/0.05 mL) monthly up to 3 months, a pro re nata (PRN) strategy was

adopted based on increase in central foveal thickness (CFT). Data collected at various time points included BCVA, CFT, photoreceptor layer thickness (PLT), and outer nuclear layer thickness (ONLT) on optical coherence tomography. The correlation between CRT, PLT, ONLT, and BCVA before and after injections was analyzed.

**Results:** Compared with baseline, in months 1, 3, and 6 after injection, the improvement of BCVA was 20.08, 22.33, and 20.50 Early Treatment Diabetic Retinopathy Study (ETDRS) letters and the decrease of CFT was 209.75  $\mu$ m, 216.81  $\mu$ m, and 216.67  $\mu$ m, respectively. The PLT in months 1, 3, and 6 after therapy significantly improved by 10.83  $\mu$ m, 12.75  $\mu$ m, and 13.14  $\mu$ m ( $P < 0.001$ ) while the ONLT significantly decreased by 217.44  $\mu$ m, 229.61  $\mu$ m, and 231.33  $\mu$ m, respectively ( $P < 0.001$ ). The mean number of injections was  $3.25 \pm 0.50$  from baseline to month 6.

**Conclusions:** Intravitreal injection of conbercept provides an effective treatment for macular edema due to BRVO. With 6 months of treatment, there was a positive correlation between BCVA and PLT ( $r = 0.486$ ,  $P = 0.003$ ), a negative correlation between BCVA and ONLT ( $r = -0.402$ ,  $P = 0.015$ ), and no correlation between BCVA and CRT ( $r = -0.228$ ,  $P = 0.180$ ).

---

**Poster No.: EX1-011**

**Analysis of Foveal Avascular Zone and Macular Vasculature Using Optical Coherence Tomography Angiography in Type 2 Diabetic Eyes Without Diabetic Retinopathy**

*First Author: Eunyoung CHOI*

*Co-Author(s): Hyun Seung KANG, Min KIM*

**Purpose:** To analyze the changes of foveal avascular zone (FAZ) and macular vasculature in type 2 diabetic patients without diabetic retinopathy using optical coherence tomography angiography (OCT-A).

**Methods:** This prospective observational study was designed including 21 diabetic eyes (21 subjects) and 20 age- and sex-matched control eyes (20 subjects). In the 6 x 6 mm





OCT-A images of the macula, we used imageJ software to measure the area/circularity of FAZ and vascular density (VD)/perfusion index (PI) in the superficial and deep capillary plexus (SCP and DCP) separately.

**Results:** The area of FAZ revealed no significant difference between the diabetic and control eyes (SCP: 0.35 vs 0.40,  $P = 0.31$  and DCP: 0.69 vs 0.69,  $P = 0.92$ ). There was also no significant difference in the circularity of FAZ in both SCP (0.82 vs 0.78;  $P = 0.16$ ) and DCP (0.79 vs 0.80;  $P = 0.76$ ). Diabetic eyes showed significantly decreased VD (18.99 vs 21.05;  $P = 0.031$ ) and PI (0.30 vs 0.33;  $P = 0.019$ ) compared with control in SCP. In DCP, VD was significantly lower in diabetic eyes than control (24.06 vs 24.85;  $P = 0.025$ ); however, PI showed no meaningful difference (0.38 vs 0.41;  $P = 0.198$ ).

**Conclusions:** Even in the stage without diabetic retinopathy, the type 2 diabetic eye shows a decrease in macular vasculature compared to the normal eye.

---

**Poster No.: EX1-012**

**Biosimilar Intravitreal Ranibizumab (Razumab) in Macular Pathology**

*First Author: Umesh BHAMMARKAR*  
*Co-Author(s): A NISAR, Deepti MEHTA, V Sahiti PRIYA, S ARUNA, V SWETHA*

**Purpose:** To study the clinical safety and efficacy of biosimilar intravitreal ranibizumab (Razumab) for the treatment of macular disorders such as diabetic macular edema (DME), neovascular age-related macular degeneration (nAMD), and macular edema secondary to retinal vein occlusions (RVOs).

**Methods:** Retrospective analysis of 51 eyes with macular pathology treated with biosimilar ranibizumab (Razumab) with at least 3 months' follow-up time. Macular edema was diagnosed by clinical examination, fundus photo and Cirrus optical coherence tomography (OCT). Patients' data were collected and included best corrected visual acuity (BCVA) by Snellen chart and OCT at baseline and on each visit during follow-up. Number of injections and potential

complications were recorded. Outcome measures were safety parameters that included signs of clinical ocular toxicity and changes in BCVA and central macular thickness (CMT) on OCT, respectively.

**Results:** Fifty-one eyes of 36 patients received biosimilar intravitreal ranibizumab injection for DME, nAMD, and macular edema secondary to RVO between June 2016 and July 2017. Mean pretreatment BCVA was 2/60 to 6/24, and postinjection BCVA at day 30 was 6/60 to 6/6 with reducing CMT on OCT. No serious drug-related ocular or systemic adverse events were identified.

**Conclusions:** The biosimilar ranibizumab for DME, nAMD, and macular edema secondary to RVO was well tolerated with improvements in BCVA and CFT without any detectable ocular and systemic toxicity. While the long-term safety and efficacy remain unknown, these short-term results suggest that biosimilar Razumab could become a safe, low-cost therapy for macular diseases. Further studies are needed to determine safety, efficacy, and side effects.

---

**Poster No.: EX1-013**

**Characteristic Appearances of Fundus Autofluorescence in Treatment-Naive and Active Polypoidal Choroidal Vasculopathy: A Retrospective Study of 170 Patients**

*First Author: Xinyu ZHAO*  
*Co-Author(s): Youxin CHEN*

**Purpose:** To investigate the characteristic appearances of fundus autofluorescence (FAF) in patients with treatment-naive and active polypoidal choroidal vasculopathy (PCV).

**Methods:** Cases with the diagnosis of treatment-naive and active PCV from November 2012 to May 2017 at Peking Union Medical College Hospital were retrospectively reviewed. All patients underwent comprehensive ophthalmologic examination. FAF findings were described at the retinal sites of the corresponding lesions identified and diagnosed using indocyanine green angiography and





spectral domain optical coherence tomography.

**Results:** A total of 170 patients with 192 affected eyes were included. The mean logarithm of the minimum angle of resolution (logMAR) best corrected visual acuity (BCVA) of the patients was  $0.53 \pm 0.28$ . The six FAF patterns of 243 polypoidal lesions were confluent hypo-autofluorescence (AF) with hyper-AF ring (49.8%), confluent hypo-AF (22.6%), hyper-AF with hypo-AF ring (3.7%), granular hypo-AF (7.0%), blocked hypo-AF due to hemorrhage (8.6%), and polyps without apparent AF changes (8.2%). For 146 branching vascular networks (BVNs), 97.3% were granular hypo-AF, and others were blocked hypo-AF due to hemorrhage. Another 2 special signs, hyper-hypo-hyper-AF circles and normal-hypo-AF circles, were also observed.

**Conclusions:** In eyes with treatment-naive and active PCV, the polypoidal lesions and BVNs induce characteristic FAF changes. FAF images provide reliable adjunct references for the diagnosis of PCV.

---

**Poster No.: EX1-014**  
**Choroidal Neovascularization Complicated With Adult-Onset Vitelliform Macular Dystrophy**

*First Author: Young Joon JO*

**Purpose:** To report 3 cases of choroidal neovascularization complicated with adult-onset vitelliform macular dystrophy (AOVMD).

**Methods:** Retrospective chart review of 25 cases of AOVMD.

**Results:** Among 25 cases, 3 cases of choroidal neovascularization complicated with AOVMD were confirmed by multimodal imaging including autofluorescence (AF), fluorescein angiography (FA), indocyanine green angiography (ICGA), and optical coherence tomography (OCT). In some cases that were considered as CNV due to leakage of fluorescein, there was no response to anti-VEGF treatment. Intraretinal cystic space on OCT decreased with anti-VEGF treatment.

**Conclusions:** Because leakage of FA might be not a definite finding of CNV complicated with AOVMD, multimodal imaging should be recommended. Anti-VEGF treatment did not reduce fluorescein leakage from lesion but did reduce intraretinal cystic space on OCT.

---

**Poster No.: EX1-015**  
**Choroidal Thicknesses Measurements in Diseased and Normal Eyes Using Swept Source and Spectral Domain Optical Coherence Tomography**

*First Author: Colin TAN*

*Co-Author(s): Louis LIM, Wei Kiong NGO*

**Purpose:** This study aimed to assess the comparability of choroidal thickness measurements using swept source (SS-OCT) and spectral domain optical coherence tomography (SD-OCT) devices among patients with retinal diseases and normal participants.

**Methods:** In a prospective cohort study of 100 subjects, comprising patients with retinal disease and normal volunteers, OCT scans were performed sequentially with the DRI OCT-1 and Spectralis OCT. Subfoveal choroidal thicknesses were independently measured and compared between the DRI OCT-1 and Spectralis OCT. For normal subjects only, a third scan with an additional SD-OCT device (Zeiss Cirrus HD-OCT) was performed for secondary comparison. Paired t tests and intraclass correlation coefficients (ICCs) were used to compare the measurements.

**Results:** Among all 100 participants, mean subfoveal choroidal thickness was  $264.3 \mu\text{m}$  and  $272.4 \mu\text{m}$  for DRI OCT-1 and Spectralis OCT, respectively ( $P = 0.001$ ), with ICC of 0.989. The mean difference in choroidal thickness between OCT devices was larger among eyes with retinal diseases compared to normal eyes ( $8.4 \mu\text{m}$  vs  $7.3 \mu\text{m}$ ). Eyes with choroidal thickness  $\leq 200 \mu\text{m}$  had smaller differences between OCT devices compared to those with thicker choroids (mean,  $3.6 \mu\text{m}$  vs  $10.0 \mu\text{m}$ ,  $P = 0.021$ ). For normal participants (36 eyes), mean choroidal thicknesses were  $289.6 \mu\text{m}$  for the DRI OCT-1,  $297.0 \mu\text{m}$  for the Spectralis OCT,





and 304.3  $\mu\text{m}$  for the Cirrus OCT [repeated measures analysis of variance (ANOVA),  $P < 0.001$ ].

**Conclusions:** Subfoveal choroidal thickness measurements are comparable between DRI OCT-1 and Spectralis OCT. The presence of retinal disease increases the variability of choroidal thickness measurements between OCT devices.

---

**Poster No.: EX1-016**  
**Curious Case of IOL Opacification After Avastin Injection**

*First Author: Anuj SONI*

**Purpose:** To report a case of intraocular lens (IOL) opacification after Avastin injection.

**Methods:** A case report.

**Results:** A 67-year-old female presented with diabetic macular edema in the left eye. She had undergone cataract surgery 3 years previously. She was given 3 monthly injections of Avastin and lost to follow-up. The patient presented 5 months later and this time she had total IOL opacity with a best corrected visual acuity (BCVA) of hand movements and no view of fundus. Hence an IOL exchange was planned. During surgery the haptic was found adherent to the capsule and the IOL was removed with the bag. On examination the whole IOL was milky white. This is the first instance where IOL opacification has been noted after Avastin injection.

**Conclusions:** IOL opacification is a rare complication and can occur after Avastin injection.

---

**Poster No.: EX1-017**  
**Demographic Characteristics of AMD Among Malay Patients in Hospital Universiti Sains Malaysia From 2016 to 2017**

*First Author: Azhan AZMAN*

*Co-Author(s): Mohamad Darwish ABDUL AZIZ, Liza Sharmini AHMAD TAJUDIN, Zunaina EMBONG, Koh NI*

**Purpose:** To analyze the demographic

characteristics of patients with age-related macular degeneration (AMD) who attended the Retina Clinic at Hospital Universiti Sains Malaysia (USM), Kelantan from 2016 to 2017.

**Methods:** This was a retrospective study of Malay AMD patients who attended the Retina Clinic at Hospital USM from June 2016 until June 2017. Patients with AMD in at least 1 eye were selected. Demographic characteristics and clinical data were collected and analyzed.

**Results:** A total of 94 Malay AMD patients were studied. There was an equal number of male and female patients. Based on classification or subtype of AMD, 57.4% of patients presented with late AMD (64.8% wet AMD and 35.2% dry AMD) and 21.3% with early AMD. Another 21.3%, or 20 patients, were diagnosed with polypoidal choroidal vasculopathy (PCV). Mean age at presentation for all patients was 68.4 years. Mean age of patients with late AMD was 70.3 years and mean age of patients with PCV was 60.9 years. Overall, sight-threatening AMD and PCV account for 78.7% of total patients. All patients with wet AMD and PCV had either completed or are still undergoing treatment with anti-VEGF (ranibizumab or aflibercept).

**Conclusions:** Generally, sight-threatening AMD and PCV are the main reasons for referral to our center. Among all, wet AMD is the commonest type of presentation among Malays.

---

**Poster No.: EX1-018**  
**Does Functional Assessment Predict Everyday Visual Functioning? Visual Function and Vision-Related Quality of Life in Age-Related Macular Degeneration**

*First Author: Geoffrey BROADHEAD*

*Co-Author(s): Andrew CHANG, Thomas HONG, Tim SCHLUB*

**Purpose:** To prospectively assess correlations between participant reported vision-related quality of life (VR-QoL) and clinical functional assessments in various stages of age-related macular degeneration (AMD).

**Methods:** Cross-sectional analysis of 106 participants with mild/moderate AMD affecting





at least 1 eye. Microperimetry (MP), flicker perimetry (FP), multifocal electroretinogram (mfERG) findings, best-corrected visual acuity (BCVA), and the Visual Function Questionnaire 25 (VFQ-25) were assessed for correlation between clinical testing results and VFQ-25 findings.

**Results:** Participants showed correlations between MP findings in the better eye and VFQ subscales for general, near, and distance vision ( $P < 0.05$  for all), and between FP findings in the worse eye and VFQ subscales for general vision, role difficulties, driving, and dependency ( $P < 0.05$  for all). Of these, the strongest correlations were between MP findings and near and distance vision in the better eye ( $R$  between 0.17-0.24).

**Conclusions:** There were no correlations between mfERG latency or peak density and VFQ subscores for driving or general vision, and only weak correlations for mfERG and VFQ subscores for distance activities in both better and worse eyes ( $P < 0.05$ ).

---

**Poster No.: EX1-019**

**Effect of Honey on Retinal Thickness in Postmenopausal Women**

*First Author: Premala Devi **SIVAGURUNATHAN**  
Co-Author(s): Noorlaila **BAHARUDDIN**, Zunaina **EMBONG**, Raja Norliza **RAJA OMAR***

**Purpose:** To evaluate the effect of honey supplementation on macular thickness and retinal nerve fiber layer (RNFL) thickness in postmenopausal women.

**Methods:** This was a prospective randomized controlled trial whereby 60 postmenopausal women were selected and randomized into 2 groups: honey and no honey supplementation. Participants in the honey group received honey supplement in the form of honey cocktail containing 20 g per sachet. Participants were instructed to ingest 1 sachet of honey cocktail per day for a total of 3 months. Baseline macular thickness and RNFL thickness were measured using Cirrus HD-OCT (optical coherence tomography) and these parameters

were repeated 3 months after intervention.

**Results:** The mean global macular thickness was significantly thicker in postmenopausal women with honey supplement 3 months postsupplement therapy ( $P = 0.002$ ). There was also a significant difference in the mean change of global macular thickness at 3 months postsupplement therapy between the 2 groups ( $P < 0.001$ ). The mean global RNFL thickness was significantly higher in postmenopausal women with honey supplement 3 months postintervention ( $P = 0.033$ ). There was also a significant difference in the mean change of global RNFL thickness at 3 months postsupplement therapy between the 2 groups ( $P < 0.001$ ).

**Conclusions:** There exists a co-relation between honey cocktail supplement and retinal thickness in postmenopausal women.

---

**Poster No.: EX1-020**

**Effect of Indocyanine Green on Tight Junction Structural Proteins in Human Retinal Pigment Epithelium ARPE-19 Cells**

*First Author: Yo-Chen **CHANG***

*Co-Author(s): Ying-Hsien **KAO**, Wen-Chuan **WU***

**Purpose:** It is generally believed that diabetic macular edema is a microvascular disease, but there is more evidence that retinal pigment epithelium close to the functional abnormalities can also cause the development of this disease. The close connection of the epithelium is composed of many specific proteins, including occludin, zonula occludens (such as ZO-1, ZO-2). This study was done to investigate the effect of indocyanine green (ICG) on the growth of human retinal pigment epithelial ARPE-19 cells in a high glucose environment and to observe the effect of ICG on cell growth and tight junction (TJ) regulation of structural protein expression.

**Methods:** Human retinal pigment epithelium ARPE-19 cell line was used. The cells were cultured in low glucose (low glucose; LG; containing 5.5 mM D-glucose) and high glucose (high glucose; HG; containing 25



mM D-glucose) and then treated with ICG. The treated ARPE-19 cells were used for cell proliferation assay, Western blot, and immunofluorescence staining.

**Results:** Western blotting confirmed that ICG inhibited the normal distribution of ZO-1, ZO-2, and occludin proteins in ARPE-19 cells. Fluorescence immunostaining results showed that ICG reduced the distribution of ZO-1 protein on the cell membrane.

**Conclusions:** ICG significantly inhibited the cell viability of ARPE-19 cells and even inhibited the expression of ZO-1, ZO-2, and occludin protein in ARPE-19 cells in a high glucose environment and reduced the activity of ZO-1 protein cell membrane distribution. These results suggest that the application of ICG in the retina of diabetic patients may worsen the integrity of the retina in diabetics.

**Poster No.: EX1-021**  
**Evaluation of Macula Disturbance After Posterior Continuous Capsulorrhexis**

*First Author: Gokhan KAYA*

**Purpose:** To investigate the occurrence of vitreoretinal complications after posterior continuous capsulorrhexis (PCC).

**Methods:** Twenty cataract patients who received PCC after phacoemulsification were evaluated with slit lamp exam, funduscopy, and Fourier domain optical coherence tomography for macular pathologies. Best corrected visual acuity (BCVA) was obtained 2 weeks after the surgical procedure.

**Results:** Disruption of vitreous face during PCC was noted in 5%. No case of cystoid macula edema was observed. Seventeen eyes (85%) had in-the-bag IOL implantation, and in 3 eyes (15%) sulcus implantation of the IOL was performed. Mean BCVA was 20/25.

**Conclusions:** PCC is a safe surgical procedure. Minimal vitreous loss and no macular disturbances were observed in this study.

**Poster No.: EX1-022**  
**Evaluation of Optic Nerve Head Microcirculation After Living Renal Transplantation**

*First Author: Tetsushi ARIMURA*  
*Co-Author(s): Yuichi HORI, Shun KUMASHIRO, Hironori OSAMURA, Tomoaki SHIBA*

**Purpose:** To evaluate short-term variations in the optic nerve head (ONH) circulation obtained by laser speckle flowgraphy (LSFG) after living renal transplantation.

**Methods:** We studied 15 patients who had end-stage kidney disease. LSFG analyzed the mean blur rates (MBR) throughout the ONH (MBR-A), in the tissue (MBR-T), and in vessels (MBR-V) at the points before, 2, and 4 weeks after renal transplantation.

**Results:** Serum creatinine was significantly improved from 8.8 to 1.3 (mg/dL,  $P < 0.0001$ ) after 1 month. The MBR-T and A showed significant variation (MBR-T:  $10.3 \pm 2.2$  and MBR-A:  $19.4 \pm 5.4$  preoperation;  $11.2 \pm 1.8$  and  $21.9 \pm 5.6$  after 2 weeks;  $10.6 \pm 2.0$  and  $20.1 \pm 5.0$  after 4 weeks;  $P = 0.03$  and  $0.02$ , respectively, ANOVA).

**Conclusions:** Our results confirmed that ONH microcirculation increases in the short term after renal transplantation and is adjusted at 1 month after.

**Poster No.: EX1-023**  
**Factors Related to Effectiveness of Intravitreal Bevacizumab Injections in Macular Edema Secondary to Branch Retinal Vein Occlusion**

*First Author: Jae Yong JANG*  
*Co-Author(s): Yong-Sok JI*

**Purpose:** To investigate factors associated with the efficacy of intravitreal bevacizumab (IVB) injection for macular edema (ME) in branch retinal vein occlusion (BRVO).

**Methods:** The medical records of 16 eyes of 16 patients who underwent IVB injection for ME secondary to BRVO with at least 12 months of follow-up were reviewed. Initial best





corrected visual acuity, duration between the onset of visual symptoms and first injection, type of BRVO according to the involved vein branch (major BRVO vs macular BRVO), size of nonperfusion area, central and mean retinal thickness, and the average interval between multiple injections were analyzed.

**Results:** After the initial IVB, there was no recurrence of ME in 50% of patients whose initial best corrected visual acuity was lower than logarithm of the minimum angle of resolution (logMAR) 0.5 or in 33.3% of patients whose best corrected visual acuity was higher than logMAR 0.5 ( $P < 0.01$ ). Major BRVO and macular BRVO patients had 50% and 33.3% recurrence rates of ME, respectively ( $P < 0.01$ ). In patients who underwent 2 or more IVB injections, the rate of average interval between injections longer than 90 days was 50% in major BRVO and 80% in macular BRVO ( $P < 0.01$ ). The number of injections was not significantly affected depending on duration between the onset of visual symptoms and first injection ( $P = 0.80$ ), size of nonperfusion area ( $P = 0.40$ ), central ( $P = 0.40$ ), and mean ( $P = 0.31$ ) retinal thickness.

**Conclusions:** Patients with BRVO may have fewer injections of intravitreal bevacizumab for macular edema when initial best corrected visual acuity is lower than logMAR 0.5 and macular branch is involved at the initial diagnosis. The interval between intravitreal injections is longer in macular BRVO.

---

**Poster No.:** EX1-024

### **Intravitreal Injections: A Patient's Perspective**

*First Author:* Aneesa **LOBO**

*Co-Author(s):* Arun **BHARGAV**

**Purpose:** To assess the impact of intravitreal injections on patients' lives, as seen from a patient's perspective. While data is available on the scientific aspect of intravitreal injections, very few studies analyze how a patient perceives intravitreal injections and their demanding repetitive schedule.

**Methods:** One hundred twenty patients from

different socioeconomic strata, who had received at least 1 intravitreal injection for varying etiologies, at a single center were randomly selected and assessed using an objective questionnaire. We also conducted a subjective grading of the burden of the eye disease on their quality of life. Patients who did not complete the questionnaire were excluded from the study.

**Results:** A total of 104 patients completed the survey. Of these, 42.3% of patients had received 1-3 injections, 30.7% 4-6 injections, 11.5% had received 7-10 injections, and 15.3% had received >10. The most common reaction of patients when they were told they required an injection was fear (54.8%). While 49% of patients were anxious prior to the first injection, only 13.4% were anxious before their subsequent injections. A majority of them (38.4%) were anxious on the day of the injection. When asked to rate the burden of disease on the quality of their life, the average grade for chronic systemic diseases was 1.98/10 while that for ocular disease was 3.58/10.

**Conclusions:** The regular need for injections combined with morbidity of the disease and cost of treatment poses a significant burden to the patient and plays a major role in patient adherence to treatment. Understanding the patient's perspective will help us to make the experience for the patient a more pleasant one, thus ensuring compliance.

---

**Poster No.:** EX1-025

### **Macular Pigment Optical Density in Filipinos With Age-Related Macular Degeneration After Lutein and Zeaxanthin Supplementation: A Nonrandomized Comparative Study**

*First Author:* Jennifer Joy **SANTOS-RAYOS**

**Purpose:** This study determined the baseline macular pigment optical density (MPOD) among Filipinos aged 50-80 years old, for those without retinal disease and those with age-related macular degeneration (AMD). The effect of lutein-zeaxanthin supplementation among





these groups was also determined.

**Methods:** A total of 120 participants separated into 3 groups (n = 40 each for no AMD, nonneovascular AMD, and neovascular AMD) completed the baseline MPOD measurement and supplementation of lutein (12 mg/day) and zeaxanthin (1 mg/day) for 90 days.

**Results:** The mean baseline MPOD for the no AMD group was 0.382 DU ( $\pm 0.10$ ), which was found to be statistically higher than baseline MPOD of the nonneovascular AMD [0.333 DU ( $\pm 0.07$ ),  $P = 0.021$ ] and neovascular AMD groups [0.283 DU ( $\pm 0.07$ ),  $P = 0.001$ ]. For the no AMD group, the MPOD levels increased significantly every month of supplementation, except at the third month when it did not reach statistical significance ( $P = 0.001$ ,  $P = 0.003$ , and  $P = 1.00$ , respectively). For both AMD groups, MPOD increased every month during supplementation.

**Conclusions:** Patients without retinal disease have higher MPOD than patients with nonneovascular AMD and an even higher MPOD than patients with neovascular AMD. Supplementation increased the MPOD for 3 months.

Poster No.: EX1-026

### Morphology of Type 1 Choroidal Neovascularization in Age-Related Macular Degeneration Detected by Optical Coherence Tomography Angiography

First Author: Teck Boon TEW

Co-Author(s): Tzyy-Chang HO, Yi-Ting HSIEH, Tso-Ting LAI, Chang-Hao YANG, Chung-May YANG

**Purpose:** To describe the morphological features of type 1 choroidal neovascular membrane (CNV) in age-related macular degeneration (AMD) using optical coherence tomography angiography (OCTA) and to correlate these characteristics with other OCT biomarkers and outcomes after anti-vascular endothelial growth factor (VEGF) therapy.

**Methods:** Retrospective case series. Patients with wet AMD and CNV were examined with the OCTA (RTVue XR Avanti) before, 3, 6, and

12 months after anti-VEGF therapy.

**Results:** Of the 33 eyes enrolled, a highly organized type 1 CNV was identified in 26 eyes (78.8%). In these 26 eyes, 2 types of CNV could be identified by OCTA. A neovascular complex with vessels radiating to all directions ("medusa" pattern) was recognized in 12 eyes. CNV with "seafan" pattern was recognized in 14 eyes. The baseline characteristics including gender, age, visual acuity, and other OCT biomarkers, such as central subfield thickness (CST), intraretinal cysts (IRC), subretinal fluid (SRF), and pigment epithelium detachment (PED), were not significantly different between these 2 patterns. One year after anti-VEGF therapy, the visual improvement was significantly better in eyes with the medusa pattern than the seafan pattern ( $P = 0.011$ ). The large vessels and the radiating pattern of the CNV remained unchanged after treatment.

**Conclusions:** Using OCTA, distinct morphology of type 1 CNV in wet AMD could be identified, and these different patterns might be a new biomarker for evaluating the prognosis of AMD after anti-VEGF therapy.

Poster No.: EX1-027


### Multiple Sub-Internal Limiting Membrane Hemorrhages With Double-Ring Sign in Eyes With Valsalva Retinopathy

First Author: Kensuke GOTO

Co-Author(s): Yasuki ITO, Takeshi IWASE, Eimei RA, Hiroko TERASAKI

**Purpose:** Valsalva retinopathy presents with sudden onset visual deterioration due to a sub-internal limiting membrane (ILM) hemorrhage on the macula as a result of increased venous pressure secondary to Valsalva maneuver. Previous reports showed that the hemorrhage represents a double-ring sign with the inner ring caused by the sub-ILM hemorrhage and the outer ring caused by the subhyaloid hemorrhage. We experienced a case of Valsalva retinopathy providing new insights into the double-ring sign.

**Methods:** A 42-year-old woman presented with sudden visual degradation in the left eye.





Ophthalmoscopic examination revealed 3 localized, dome-shaped sub-ILM hemorrhages with the double-ring sign without vitreous hemorrhage. As the systemic examination showed no abnormalities excluding the history of coughing by asthma, we diagnosed her with Valsalva retinopathy.

**Results:** The inner ring of the double-ring sign showed sub-ILM hemorrhage on optical coherence tomography (OCT) images. The outer ring represented flame-shaped hemorrhage in the fundus and intraretinal hemorrhage in the OCT image, indicating that the outer ring represents a nerve fiber layer of retinal hemorrhage. The ILM over the macula developed a tear 2 days later causing subhyaloid and vitreous hemorrhages. An intraretinal hemorrhage as flame-shaped hemorrhage was observed in the outer ring more than 1 month after the first visit.

**Conclusions:** Our findings indicate that severe pressure exerted on the ILM should cause a detachment of the ILM leading to the inner ring of sub-ILM hemorrhage and would invade into the nerve fiber layer space leading to the outer ring of the double-ring sign.

---

**Poster No.:** EX1-028

**Optical Coherence Tomography Angiography Patterns of Choroidal Neovascular Membrane in Central Serous Chorioretinopathy**

*First Author:* Vishal **GOVINDHARI**

*Co-Author(s):* Jay **CHHABLANI**, Abhilash **GOUD**

**Purpose:** To describe the various patterns of choroidal neovascular membrane (CNVM) secondary to central serous chorioretinopathy (CSCR) on optical coherence tomography angiography (OCTA) and to compare the diagnostic accuracy of OCTA with conventional imaging [swept-source OCT (SS-OCT), fundus fluorescein angiography (FFA), and indocyanine green angiography (ICG)].

**Methods:** All patients clinically diagnosed as CNVM secondary to CSCR underwent comprehensive ophthalmic examination along with SS-OCT and OCTA using DRI Triton plus

(Topcon), while FFA and ICG were performed on HRA 2 (Heidelberg Engineering). Treatment-naive as well as previously treated eyes were included in the study.

**Results:** Seventeen eyes of 16 patients were included in the study. All patients were male. The mean age was 52.37 years. The mean logarithm of the minimum angle of resolution (logMAR) visual acuity at presentation was 0.476 (Snellen equivalent 20/60). Conventional imaging as well as OCTA detected CNVM in 15 out of 17 eyes. On OCTA 4 different CNVM patterns were noted at the choriocapillaris scans including tangled irregular (5 eyes), tangled ball of worms (7 eyes), pruned tree (3 eyes), and indeterminate pattern (2 eyes).

**Conclusions:** OCTA detects the presence of vascular network in most cases of CSCR CNVM proven by conventional imaging and hence offers a noninvasive technique of detecting CNVM. OCTA demonstrates various patterns on CNVM as noted, which needs further evaluation.

---

**Poster No.:** EX1-029

**Outcomes of Central Serous Chorioretinopathy With Cystoid Degeneration**

*First Author:* Sankeert **GANGAKHEDKAR**

*Co-Author(s):* Jay **CHHABLANI**

**Purpose:** To evaluate treatment outcomes in eyes with central serous chorioretinopathy with cystoid degeneration (CSC-CD).

**Methods:** This retrospective case series evaluated ocular findings, optical coherence tomography features, and treatment outcomes at 1 year in eyes with CSC-CD.

**Results:** Twenty-one eyes of 18 eligible patients (mean age,  $52.61 \pm 7.78$  years) were included. Mean duration of symptoms was  $22 \pm 36$  months. Treatment modalities included focal laser (2 eyes), micropulse laser (11 eyes), photodynamic therapy (3 eyes), intravitreal anti-vascular endothelial growth factor therapy (3 eyes), multimodal treatment (2 eyes), and no treatment (3 eyes). Mean visual acuity changed







from  $0.62 \pm 0.36$  to  $0.61 \pm 0.38$  logarithm of the minimum angle of resolution (logMAR;  $P = 0.89$ ) at 1 year with subretinal fluid reduction from  $134.90 \pm 133$  to  $79 \pm 91 \mu\text{m}$  ( $P = 0.12$ ). There was no significant difference in mean subfoveal choroidal thickness, cyst height, cyst location, and outer retinal structures.

**Conclusions:** Eyes with CSC-CD tend to be refractory with minimal visual benefits with available therapies.

**Poster No.: EX1-030**

**Permeability and Anti-VEGF Effects of Bevacizumab, Ranibizumab, and Aflibercept in Polarized Retinal Pigment Epithelial Cells**

*First Author: Hiroto TERASAKI*

*Co-Author(s): Taiji SAKAMOTO, Shozo SONODA, Naoya YOSHIHARA*

**Purpose:** To determine the effects of bevacizumab, ranibizumab, and aflibercept on the permeability and the effects of anti-vascular endothelial growth factor (VEGF) on polarized retinal pigment epithelial cells (RPECs) in vitro.

**Methods:** Polarized RPECs were cultured in the upper chamber of a Transwell system. Anti-VEGF drugs were added to the upper chamber, and the concentrations of the drugs in the lower chambers were measured. The permeability rates of the 3 anti-VEGF drugs through the RPE cell layer and the concentration of VEGF in each chamber were determined.

**Results:** The permeability of aflibercept was significantly lower by about 40% than that of bevacizumab through the RPE cell layer ( $P < 0.05$ ). Ranibizumab was significantly more permeable through the RPE cells than bevacizumab (180% of bevacizumab,  $P < 0.05$ ). Although VEGF was almost totally absent in the upper chamber after exposure to the 3 antibodies, it was decreased more significantly with aflibercept than with bevacizumab in the lower chamber (2.8% vs 65.8% of control;  $P < 0.01$ ). Ranibizumab also decreased the VEGF level compared to bevacizumab (31.7% vs 65.8% of control;  $P < 0.01$ ).

**Conclusions:** The greater reduction of the

amount of VEGF in the lower chamber by aflibercept and ranibizumab than bevacizumab may explain why aflibercept and ranibizumab are more effective than bevacizumab against type 1 choroidal neovascularization.

**Poster No.: EX1-031**

**Prevalence and Risk Factors for Neovascularization in Eyes With Neurosensory Detachments**


*First Author: Yu Qiang SOH*

*Co-Author(s): Chui Ming Gemmy CHEUNG, Val PHUA, Kelvin Yi Chong TEO*

**Purpose:** Central serous chorioretinopathy (CSCR) may occasionally be associated with choroidal neovascularization (CNV). Optical coherence tomography angiography (OCT-A) allows clinical detection of CNVs in a noninvasive manner, with relative precision. In this study, we evaluated clinical and optical coherence tomography (OCT) characteristics which may possibly predict the presence of CNVs in patients diagnosed with CSCR.

**Methods:** OCT-A (Swept-Source OCT-A, Topcon Corp, Japan) and OCT (Spectralis, Heidelberg Engineering, Germany) scans were performed for patients diagnosed with CSCR. A detailed clinical history was obtained, including the chronicity of the subretinal fluid (SRF) and duration of SRF. En-face OCT-A images were used to determine the presence of CNVs. OCT B-scan images were graded for presence of pigment epithelial detachments (PED) and central choroidal thickness (CT).

**Results:** Twenty-five patients with CSCR were recruited, of which 6 (24%) were diagnosed with CNVs based on OCT-A imaging. Mean patient age was 52.9 years old (range, 34-77); 72% ( $n = 18$ ) were males and 88% ( $n = 22$ ) were Chinese. PEDs were present in 64% ( $n = 16$ ) of patients, mean CT was  $342 \pm 62 \mu\text{m}$ , and mean duration of SRF was  $9.2 \pm 10.2$  weeks. Binary logistic regression revealed that increasing age ( $P = 0.046$ ) and duration of SRF ( $P = 0.047$ ) were associated with significantly greater risks of CNV. Presence of PED ( $P = 0.643$ ) and choroidal thickness ( $P = 0.423$ ) were





not statistically significant predictors for CNV.

**Conclusions:** Increasing age and duration of SRF are predictors for the presence of CNV in patients with CSCR.

Poster No.: EX1-032

### Pro Re Nata Treatment After a Single Intravitreal Anti-Vascular Endothelial Growth Factor Drug Injection for Macular Edema With Branch Retinal Vein Occlusion

First Author: Hironori **OSAMURA**

Co-Author(s): Yuichi **HORI**, Tadashi **MATSUMOTO**, Tomoaki **SHIBA**, Arimura **TETSUSHI**, Shun **KUMASHIRO**

**Purpose:** We evaluated the effectiveness of pro re nata (PRN; "as necessary") treatment with a single injection of an intravitreal anti-vascular endothelial growth factor (anti-VEGF) drug (ranibizumab or aflibercept) for treatment-naive macular edema (ME) secondary to branch retinal vein occlusion (BRVO).

**Methods:** We retrospectively evaluated the cases of 28 consecutive patients with ME secondary to BRVO who were treated on a PRN basis after a single intravitreal injection of ranibizumab (IVR; 15 patients) or aflibercept (IVA; 13 patients). The main outcome measures were changes in visual acuity (VA); central retinal thickness (CRT) as measured by optical coherence tomography at 1, 3, 6, and 12 months after injection; and the total number of anti-VEGF injections.

**Results:** The mean number of intravitreal injections of either anti-VEGF drug was  $2.8 \pm 1.0$ ; the total number of IVRs was  $2.9 \pm 1.0$ , and that of IVAs was  $2.6 \pm 1.0$  ( $P = 0.44$ ). There was a significant improvement in visual acuity from 1 month to 12 months after injection in the IVR, IVA, and total groups ( $P < 0.0001$ , respectively). VA changes at all time points from baseline were not significantly different between the IVR and IVA groups. There were significant decreases in CRT from 1 to 12 months after injection in the IVR, IVA, and total groups ( $P < 0.0001$ , respectively). The CRT reductions at all time points from baseline were not significantly different between the IVR and IVA groups.

**Conclusions:** PRN treatment after a single intravitreal injection of any anti-VEGF drug may be effective for treatment-naive ME secondary to BRVO.

Poster No.: EX1-033

### RPE Rip After Intravitreal Eylea Injection in PCV

First Author: Nallamasa **ROHIT**

Co-Author(s): Raja **NARAYANAN**

**Purpose:** To report a case of retinal pigment epithelium (RPE) rip in a pigment epithelial detachment (PED) patient following intravitreal aflibercept (Eylea) injection.

**Methods:** A 63-year-old male patient who was diagnosed with polypoidal choroidal vasculopathy (PCV) in the left eye underwent fluorescein angiography (FA), indocyanine green angiography (ICG), autofluorescence, and swept source optical coherence tomography (OCT). He was then advised intravitreal Eylea injection for the left eye.

**Results:** A PCV patient had PED in the left eye with PED height of approximately 300  $\mu\text{m}$ , with visual acuity at baseline of 20/50. A single dose of intravitreal Eylea injection 2 mg in 0.05 mL in the left eye was injected. On his 1-month follow-up vision improved to 20/40, but RPE rip was noted superonasal and superotemporal to the fovea.

**Conclusions:** RPE rip can occur in moderate-sized PED after intravitreal Eylea injection. This may be due to rapid decrease in PED with intravitreal Eylea injection. Caution may be required with Eylea injection in case of moderate PED.

Poster No.: EX1-034

### Randomized Clinical Trial Evaluating Reflux, IOP, and Pain Following Intravitreal Anti-Vascular Endothelial Growth Factor Injections Using 30G and 32G Needles

First Author: Saeed **ALSHAHRANI**

Co-Author(s): Tom **GONDER**, Vasudha **GUPTA**, Ahmed **MOUSA**, Uriel **RUBIN**, Sanjay **SHARMA**

**Purpose:** To compare the postinjection reflux,





immediate postinjection intraocular elevation, and pain perception after 30-gauge versus 32-gauge needles in eyes injected with anti-vascular endothelial growth factor agents.

**Methods:** Prospective, randomized interventional case series of 122 eyes of 61 consecutive patients who received intravitreal anti-vascular endothelial growth factor therapy. All eyes were evaluated for preinjection intraocular pressure (IOP), postinjection IOP, postinjection reflux, and pain score using a visual analog scale (VAS).

**Results:** Our planned sample size calculation called for 168 eyes in order to detect statistical differences at an alpha of 0.5 and a power of 80%. Of the 168 subjects required, 122 eyes have been recruited to date. Postinjection reflux was 39% in 30G, higher than 26% in the 32G group. The mean postinjection IOP elevation after 5 minutes was 25% from baseline (0-106%) in 30G and 31% (0-120%) in 32G eyes. The pain score was no pain (23% vs 31%), mild pain (62% vs 60%), moderate pain (10% vs 7%), and severe pain (5% vs 3%) in 30G and 32G eyes, respectively.

**Conclusions:** In this study we noticed that the 32G needle was associated with less postinjection reflux, less pain, and increased transient postinjection IOP. It was appreciated by the patients and they preferred it.

---

**Poster No.: EX1-035**

**Real-Life Clinical Experience With Intravitreal Razumab (Biosimilar Ranibizumab) in Indian Patients: Retrospective Observational Data From a Single Tertiary Ophthalmology Center in North India**

*First Author: Sangita JAIN*

**Purpose:** RE-ENACT was a nationwide, retrospective, multicenter, observational study to assess the safety and effectiveness of Razumab (biosimilar ranibizumab; Intas Pharmaceuticals Ltd) in Indian patients. This paper reports the observations from a single tertiary care ophthalmology center in North India.

**Methods:** Retrospective data of 33 patients with neovascular age-related macular degeneration (nAMD), diabetic macular edema (DME), retinal vein occlusion (RVO), or myopic choroidal neovascularization (mCNV) from northern India injected intravitreally with Razumab 0.5 mg 4 weekly for 12 weeks was collated and analyzed. All subjects were followed up with parameters like best corrected visual acuity (BCVA), intraocular pressure (IOP), central macular thickness (CMT), need for repeated injections 4 weeks, 8 weeks, and 12 weeks following treatment to determine the safety and effectiveness of the drug administered.

**Results:** BCVA and CMT data were analyzed using 2-tailed paired t test. Mean pretreatment BCVA was  $1.26 \pm 0.685$  logarithm of the minimum angle of resolution (logMAR). After the first, second, and third ranibizumab injections, the mean BCVA observed at week 4 was  $1.22 \pm 0.720$  logMAR, at week 8 was  $0.97 \pm 0.698$  logMAR, and at week 12 was  $0.57 \pm 0.329$  logMAR, indicating statistically significant improvement in visual acuity ( $P = 0.3604$ ,  $P = 0.0079$ , and  $P < 0.0001$ , respectively). Mean pretreatment CMT also reduced significantly ( $P = 0.9929$ ,  $P = 0.0002$ ,  $P < 0.0001$ , respectively at 4, 8, and 12 weeks). No adverse event, especially intraocular inflammation, was observed related to drug usage during the 12-week follow-up period.

**Conclusions:** Razumab demonstrated well-controlled efficacy with no additional safety concerns.

---

**Poster No.: EX1-036**

**Refining Anti-Vascular Endothelial Growth Factor Practices in Neovascular Age-Related Macular Degeneration: Review**

*First Author: Jennifer Joy SANTOS-RAYOS*

**Purpose:** Intravitreal anti-vascular endothelial growth factor (anti-VEGF) injection is the first line of treatment in neovascular age-related macular degeneration (nAMD). However, 50% of patients will still be categorized as poor





responders. At present, there are no defined clinical parameters for poor response. This article reviewed the recent evidence identifying problems with anti-VEGF injection in nAMD and ways to achieve better efficacy.

**Methods:** Trials, systematic reviews, and meta-analysis were included.

**Results:** The level of response to anti-VEGF injection for nAMD patients should be evaluated using both visual acuity and retina morphology from optical coherence tomography. Five levels of response were suggested by a consensus of experts, with limited response to anti-VEGF fulfilling the clinical parameter of less than 25% change in central retinal thickness (CRT) via OCT, or exacerbation of CRT, and/or less than 5-letter improvement or worsening of vision. Factors of limited response are misdiagnosis, tachyphylaxis, genetic predisposition, and anatomical confounders. Chronic anti-VEGF injections pose long-term problems like injection fatigue, cost, poor quality of life, poor final visual acuity due to geographic atrophy, increase in intraocular pressure, and systemic side effects. Considering these findings, aspects of refinement are close monitoring at the initiation phase, change of anti-VEGF drug, change of treatment regimen, and use of combination therapy.

**Conclusions:** Poor responders to intravitreal anti-VEGF could be identified early in the treatment course through close monitoring of clinical parameters. Once poor responders were identified, several refining approaches could be instituted to maximize efficacy of anti-VEGF and long-term visual gains.

**Poster No.: EX1-037**  
**Risk Factors for Rapid Progression to Proliferative Diabetic Retinopathy in Type 2 Diabetic Patients**

*First Author: Jeong Hun BAE*  
*Co-Author(s): Ko Un SHIN*

**Purpose:** To evaluate the risk factors associated with rapid progression to proliferative diabetic retinopathy (PDR) in patients with type 2

diabetes.

**Methods:** The study included 163 patients with moderately severe nonproliferative diabetic retinopathy (NPDR) divided into 2 groups based on the rate of retinopathy progression: a rapidly progressive group (progression to PDR within 12 months; n = 60); a control group (no progression; n = 103). All patients underwent detailed ophthalmic and systemic examinations. Data on medical history and health behaviors were collected.

**Results:** Patients in the rapidly progressive group were younger than those in the control group ( $49.0 \pm 10.4$  vs  $63.0 \pm 11.5$  years,  $P < 0.001$ ). A shorter duration of diabetes and an increase in the blood levels of HbA1c, fasting and 2-hour postprandial blood glucose, basal C-peptide, total cholesterol, and low-density lipoprotein cholesterol (LDL-C) were associated with rapid progression to PDR. Multivariate analyses showed that age [adjusted odds ratio (aOR) 0.896, 95% CI 0.85–0.95,  $P < 0.001$ ] and a high LDL-C level ( $>100$  mg/dL) (aOR 3.960, 95% CI 1.27–12.34,  $P = 0.018$ ) were independently related to rapid progression after adjustment for confounding factors.

**Conclusions:** Our study suggests that age and a high LDL-C level may affect rapid progression to PDR in type 2 diabetic patients.

**Poster No.: EX1-038**  
**Successfully Treated Submacular Hemorrhage and Macular Edema Secondary to Hemiretinal Vein Occlusion With Intravitreal Bevacizumab**

*First Author: Maftuhim ADDENAN*  
*Co-Author(s): Mariam JAMALUDDIN, Tengku Ain KAMALDEEN*

**Purpose:** To describe a rare case of submacular hemorrhage and macular edema secondary to hemiretinal vein occlusion successfully treated with intravitreal bevacizumab.

**Methods:** Case report.

**Results:** A 64-year-old Indian male, with underlying diabetes and hypertension, presented with right eye decreased visual



acuity and submacular hemorrhage and edema secondary to inferior hemiretinal vein occlusion. He underwent pneumatic retinopexy and was treated with multiple intravitreal bevacizumab injections. Treatment outcomes were assessed by best corrected visual acuity and Cirrus spectral domain optical coherence tomography. At 5 months after intravitreal bevacizumab injection, his visual acuity improved to 6/9 and maintained.

**Conclusions:** Submacular hemorrhage is a rare presentation in hemiretinal vein occlusion and is associated with poor presenting visual acuity. Treatment resulted in ongoing anatomic and visual improvement with resolution of hemorrhage and maintained acuity at the last visit.

---

Poster No.: EX1-039

**The Bilaterality of Polypoidal Choroidal Vasculopathy: Multimodality Imaging**

First Author: Rui HUA

**Purpose:** To investigate the bilaterality of polypoidal choroidal vasculopathy (PCV) in an Asian population using multimodal imaging techniques.

**Methods:** Retrospective case series. Diagnostic indocyanine green angiography (ICGA) and spectral domain optical coherence tomography (SD-OCT) were performed to enroll the eligible PCV eye as a study eye and its contralateral eye as the fellow eye correspondingly.

**Results:** Among 57 patients at baseline, 17.5% of PCV polyps were detected by OCT directly. Concerning the subfoveal choroidal thickness, the study eyes [269 (141-704)  $\mu\text{m}$ ] were comparable to the fellow eyes [263 (161-688)  $\mu\text{m}$ ] statistically ( $P = 0.091$ ). Moreover, no significant difference was observed in hyperfluorescent spots on ICGA between study eyes (84.2%) and fellow eyes (77.2%,  $P = 0.342$ ). On the contrary, the proportion of branching vascular network (BVN) and choroidal hyperpermeability on ICGA and retinal pigment epithelium detachment and double-layer sign on OCT in study eyes was 89.5%,

68.4%, 94.7%, and 94.7%, thus significantly greater than in fellow eyes. In particular, 2 silent BVNs without any leakage on both fluorescein angiography and ICGA were found in the fellow eyes.

**Conclusions:** The results indicate that the early signs of PCV in the fellow eyes were found with similar choroidal thickness on SD-OCT and hyperfluorescent dots during ICGA compared with the PCV eyes. Furthermore, silent BVN may be secondary to pachychoroid spectrum disorders. However, whether PCV is a binocular disease or not still needs further follow-up and investigation.

---

Poster No.: EX1-040

**The Change of Axial Length in Highly Myopic Adults Using Partial Coherence Interferometry**

First Author: Jae Jung LEE

Co-Author(s): Ik Soo BYON, So Hee KIM, Jieun LEE, Kang Yeun PAK, Sung Who PARK

**Purpose:** To investigate the change of axial length (AL) in highly myopic adults using partial coherence interferometry and to find the factors associated with increase of AL.

**Methods:** The medical records of highly myopic adults (myopia  $\geq -6$  diopters or AL  $\geq 26.0$  mm) were reviewed retrospectively. In each patient AL was measured using partial coherence interferometry at least 3 times for 2 years. Rate of AL change was calculated per year. Associations between age, AL, choroidal thickness, and the AL change rate were evaluated using multiple regression analysis.

**Results:** Twenty-three (3 males, 18 females) patients and 43 eyes were included in this study. The mean age was  $48.3 \pm 12.6$  years old. Initial AL was  $29.181 \pm 1.985$  mm and choroidal thickness was  $61.8 \pm 36.6$   $\mu\text{m}$ . Average spherical equivalent was  $-10.38 \pm 2.52$  diopters ( $-6.0$  to  $-16.25$  diopters). Mean follow-up period was  $2.3 \pm 0.3$  years. Significant increase in AL of 0.05 mm or more was observed in 34 eyes (79%) at 2 years. Mean axial length was significantly increased  $29.258 \pm 1.980$  mm ( $P < 0.001$ ) at the



first year and  $29.334 \pm 1.994$  mm ( $P < 0.001$ ) at the second year. The average AL change rate was  $0.070 \pm 0.050$  mm (0.01 to 0.24 mm) per year. No factors related to the AL change rate were found in multiple regression analysis.

**Conclusions:** Increase of AL in highly myopic adults is more frequent than previous reports using A-scan. Continual observations are recommended for early detection of complications.

---

**Poster No.: EX1-041**  
**The I and the Eye**

*First Author: YC Venu Gopal REDDY*  
*Co-Author(s): Syed MOHIDEEN, Anuj SHARMA, Adheesh SHETTY*

**Purpose:** To report a case of acute iodine intoxication on the retina noted in a 34-year-old male patient who had consumed a toxic dose of potassium iodate 10 years prior to presentation.

**Methods:** Single case report. The patient underwent a complete slit-lamp evaluation and indirect ophthalmoscopy. Optical coherence tomography (OCT) and OCT-angiography of the patient was done. The patient also underwent a visual field analysis followed by an electroretinogram (ERG).

**Results:** The case was noted to have a diminished best corrected visual acuity (BCVA) of 6/36 in the right eye (OD) and counting fingers close to face in the left eye (OS). Widespread outer retinal necrosis with subretinal fibrosis was noted, which was confirmed with the presence of foveal atrophy on OCT scan. The visual field was constricted with a diminished amplitude on ERG with scotopic and photopic stimuli.

**Conclusions:** Very few case reports exhibiting acute iodate toxicity on the retina are noted; this case presents the first instance wherein a long-term effect of acute iodine intoxication is reported. A marked reduction in the visual acuity with no long-term improvement is noted which, along with atrophy of the outer retina and a diminished ERG amplitude, points toward

a grave prognosis.

---

**Poster No.: EX1-042**  
**Therapeutic Effect of Sleep Apnea on Atherosclerosis Depended on Ocular Microcirculation Shown by Laser Speckle Flowgraphy**

*First Author: Mao TAKAHASHI*  
*Co-Author(s): Yuuichi HORI, Mahito NORO, Tomoaki SHIBA, Kazuhiro SHIMIZU, Kohji SHIRAI*

**Purpose:** Recently, obstructive sleep apnea (OSA) has been reported as a risk factor for atherosclerosis. However, it is difficult to predict responders to sleep apnea treatment for atherosclerosis. We examined whether there are differences in the effect of OSA treatment on atherosclerosis by ocular microcirculation.

**Methods:** Subjects were 60 patients with sleep apnea diagnosed with polysomnography in Japan from 2008 to 2014. Subjects were treated with continuous positive airway pressure (CPAP) for 1 year. All subjects had eye examination of ocular microcirculation using laser speckle flowgraphy before CPAP treatment. Ocular microcirculation was estimated by mean blow rate (MBR) and blow out time (BOT). Influence of CPAP treatment on atherosclerosis was defined by change of intima-media thickness (IMT) using carotid ultrasonography.

**Results:** Mean IMT was not correlated with age, body mass index, or severity of OSA on first health check data. IMT decreased significantly after 1 year of CPAP treatment ( $0.84 \pm 0.6$  to  $0.82 \pm 0.7$ ;  $P < 0.05$ ). There was no relationship between change of mean IMT with age, blood pressure, or estimated glomerular filtration rate (eGFR) at first health check. Correlated factors for change of mean IMT were high IMT, body mass index, HbA1c, BOT, and severity of OSA ( $r = -0.38$ ,  $r = 0.25$ ,  $r = 0.43$ ,  $r = 0.37$ ,  $r = 0.29$ ,  $P < 0.05$ , respectively) at first health check. Maximum IMT had not changed after 1 year of CPAP treatment. Correlated factors for change of maximum IMT were age, HbA1c, eGFR, and MBR at first health check.

**Conclusions:** Change of IMT correlated with



microcirculation before CPAP treatment for OSA. These results suggest that responders to OSA treatment for atherosclerosis could be predicted by measuring ocular microcirculation as shown by laser speckle flowgraphy.

Poster No.: EX1-082

### Retinal Vascular Calibers and Obesity in Children

First Author: Evelyn **TAI**

Co-Author(s): Shatriah **ISMAIL**, Yee Cheng **KUEH**, Wan Hazabbah **WAN HITAM**, Tien Yin **WONG**

**Purpose:** Microvasculature abnormalities are central to the pathogenesis of cardiometabolic disease. Retinal vessel analysis allows objective assessment of the retinal microcirculation, which reflects the systemic microvasculature. Microcirculatory alterations have been implicated in the pathogenesis of obesity. Our study thus aimed to evaluate the effect of retinal vascular parameters on obesity in children aged 6 to 12 years old.

**Methods:** This was a cross-sectional study in a tertiary eye center. A comprehensive eye examination, retinal photography, and measurement of axial length, blood pressure, and body mass index (BMI) were performed. Retinal vascular parameters were measured using validated software. Obesity was classified as BMI of  $> 2$  SD (standard deviation) above the mean, based on World Health Organization age- and sex-specific growth charts. Binary logistic regression was used to examine the effect of retinal vascular parameters on obesity.

**Results:** Of the 166 children in this study, approximately 51.2% were obese and 51.8% were female. The mean age was 9.58 years. We observed that children who had wider retinal arterioles had a 6.5% lower odds of being obese compared to children with narrower retinal arterioles (95% CI: 0.90, 0.97;  $P < 0.001$ ). However, children with wider retinal venules had an odds ratio of 1.04 for obesity compared to children with narrower retinal venules (95% CI: 1.01, 1.06;  $P = 0.004$ ).

**Conclusions:** The risk of obesity is increased in

primary school children with narrower retinal arterioles and wider retinal venules. Further prospective studies are required to identify the temporal nature of these associations.

Poster No.: EX1-083

### Intraocular Pressure in Patients With Retinal Vein Occlusion Treated With Dexamethasone Intravitreal Implant: 3 Years of Follow-Up

First Author: Dong Hyun **WANG**

Co-Author(s): Juno **KIM**, Sung Jin **LEE**

**Purpose:** To investigate the occurrence and time course of increases in intraocular pressure (IOP) in patients with retinal vein occlusion treated with dexamethasone intravitreal implant.

**Methods:** Thirty-two patients (32 eyes) who received sequential dexamethasone intravitreal implants for retinal vein occlusion based on retreatment eligibility criteria were followed for 36 months. Mean changes in IOP, best-corrected visual acuity (BCVA), and central retinal thickness (CRT) were noted.

**Results:** The mean number of dexamethasone intravitreal implants during the 36 months was  $5.3 \pm 2.7$  (range, 1-10). Increases in IOP  $\geq 5$  mm Hg and  $\geq 10$  mm Hg from baseline occurred in 37.5% and 25.0% of the patients, and the percentage decreased with repeated injections. IOP lowering medication was used by 25.0% of patients. In 1 patient who had repeated IOP elevation, the dexamethasone implant was no longer used and the injection drug was switched to an anti-vascular endothelial growth factor (VEGF) agent. No patients required incisional glaucoma surgery during the study period. The dexamethasone intravitreal implant significantly improved the BCVA [mean logarithm of the minimum angle of resolution (logMAR) improvement of 0.13 units; 95% confidence interval (CI), 0.03-0.22;  $P = 0.012$ ] and the CRT (mean change in CRT of  $-183.66$   $\mu\text{m}$ ; 95% CI, 107.70-259.61;  $P < 0.001$ ) at month 36.

**Conclusions:** Sequential treatment with dexamethasone intravitreal implant showed



significant benefits in both BCVA and CRT. Although dexamethasone intravitreal implant caused elevated IOP in a considerable number of patients, IOP could be managed without major complications and cumulative effect of repeated treatment on IOP was not observed.

**Poster No.: EX1-084**

**Follow-Up Trend for Eye Check-Up in Emigrant Population of Kerala, India: A Hospital Study**

*First Author: Anuj SONI*

**Purpose:** To find out the follow-up patterns of diabetic patients for diabetic retinopathy screening in an emigrant population.

**Methods:** We retrospectively analyzed the duration of last ophthalmic follow-up for emigrants and their families visiting our diabetic clinic from October 2016 to April 2017. All the patients who were diagnosed with diabetes were enrolled and through history their last eye check-up was noted. We also analyzed their duration of diabetes, extent of retinopathy, and their HbA1c values.

**Results:** A total of 171 patients were evaluated, out of which 55 had diabetic retinopathy. Patients in the diabetic retinopathy group (n = 55) had a mean duration between last follow-up of 16.9 months and mean HbA1c of 10.7%. Patients without diabetic retinopathy had a mean duration between last check-up of 25.5 months and mean HbA1c of 8.8%. There was a statistically significant difference between the 2 groups. However, both the groups had poor follow-up and poor diabetes control.

**Conclusions:** Emigrants and their families avoid healthcare facilities abroad because of the high cost. They have poorer follow-up and hence should be given special consideration when evaluating and treating.

**Poster No.: EX1-085**

**1-Year Outcomes of Conbercept Therapy for Diabetic Macular Edema**

*First Author: Tong QIAN*

**Purpose:** To evaluate the 1-year outcomes of treatment of diabetic macular edema (DME) with intravitreal conbercept.

**Methods:** The clinical data of 33 DME patients (40 eyes) were retrospectively reviewed. The patients were treated with intravitreal conbercept (IVC) for 1 month. Additional IVC was given at subsequent monthly visits, if needed (1 + PRN). The patients were followed-up for 12 months.

**Results:** The best-corrected visual acuity (BCVA) at 12 months was significantly increased ( $66.7 \pm 15.3$  letters) in comparison with baseline ( $54.4 \pm 15.4$  letters,  $P < 0.0001$ ). The mean improvement in BCVA was  $11.0 \pm 8.9$  letters. At 12 months, 44.1% of the eyes gained  $\geq 15$  letters, 52.9% of the eyes gained  $\geq 10$  letters, and 70.6% of the eyes gained  $\geq 5$  letters. No vision loss was noticed in 96.8% of the eyes. A total of 5.9% of the eyes lost  $\geq 5$  letters. No patients lost  $\geq 10$  or  $\geq 15$  letters. The central retinal thickness (CRT) at 12 months was significantly reduced ( $277.1 \pm 122.9 \mu\text{m}$ ) in comparison with baseline ( $510.9 \pm 186.1 \mu\text{m}$ ,  $P < 0.0001$ ). At 12 months, 43.3% of the patients had a CRT  $\leq 250 \mu\text{m}$ . The mean number of injections was  $5.8 \pm 1.7$  over 12 months. No severe ocular or systemic adverse events were noticed, either related to the drug or injection.

**Conclusions:** Intravitreal injection of conbercept is safe and effective in the treatment of DME.

**Poster No.: EX1-086**

**A Rare Case of Optic Nerve Head Drusen**

*First Author: Lokesh JAIN*

**Purpose:** Optic disc drusen are condensations of hyaline-like material within the substance of the optic nerve head. Optic nerve head drusen (ONHD) is encountered in approximately 0.3% of the population and is often bilateral.





**Methods:** A 27-year-old male patient presented to us with difficulty in peripheral vision. Appropriate ocular workup including visual fields, B-scan ultrasonography, fundus fluorescein angiography, fundus photographs, and Heidelberg Tomograph imaging and systemic examination was also done.

**Results:** Fundus examination showed waxy pearl-like lesions on the disc. Visual field showed inferior arcuate defects in both the eyes. Red-free photograph showed autofluorescence. B-scan ultrasonography showed high reflective echo in optic nerve head shadow. Diagnosis of bilateral optic nerve head drusen was made.

**Conclusions:** There is no existing treatment for optic nerve head drusen. Proper follow-up and patient education is the best available modality of care.

Poster No.: EX1-087

### A Study of Choroidal Thickness in Type 2 Diabetes Mellitus Patients With Spectral Domain Optical Coherence Tomography

First Author: Yen Harn **YEW**

Co-Author(s): Angela **LOO**, Visvaraja **SUBRAYAN**

**Purpose:** To examine the choroidal thickness in patients with type 2 diabetes mellitus using the Cirrus-HD imaging system.

**Methods:** One hundred fifty patients were recruited into 3 groups with 50 patients each: 1) controls, 2) diabetics with no retinopathy (no DR), and 3) diabetics with moderate nonproliferative retinopathy (NPDR). The measurements were taken at the fovea and 4 parafoveal locations in the temporal, nasal, superior, and inferior quadrants located 1500  $\mu\text{m}$  away from the fovea. One-way analysis of variance (Anova) test was used to compare the measurements among the 3 groups while post-hoc Tukey test was used for pairwise comparison. Multiple linear regression analysis was used to assess the relationship between choroidal thickness and axial length, age, HbA1c level, and the duration of diabetes mellitus.

**Results:** Bland-Altman plots showed good agreement between the 2 independent observers. The choroid was thinner in the NPDR group compared to diabetics without retinopathy, although this difference was not statistically significant. Controls had the thickest choroid when compared to NPDR at all points ( $P < 0.05$ ) but the differences were insignificant when compared to diabetics without retinopathy. Subfoveal choroidal thickness measured  $289.66 \pm 82.37 \mu\text{m}$  in controls,  $280.10 \pm 61.46 \mu\text{m}$  in no DR, and  $247.36 \pm 72.56 \mu\text{m}$  in NPDR. Axial length and age were significantly inversely correlated with choroidal thickness. However, HbA1c level and the duration of diabetes were not related to choroidal thickness.

**Conclusions:** Type 2 diabetic patients with moderate nonproliferative diabetic retinopathy had thinner choroid compared to nondiabetics and diabetics without retinopathy.

Poster No.: EX1-088

### Assessment of Fluorescein Angiographic Pattern and Its Prognostic Value in Idiopathic Epiretinal Membrane

First Author: Hanjo **KWON**

Co-Author(s): Ik Soo **BYON**, Ji Eun **LEE**, Sung Who **PARK**

**Purpose:** To investigate a fluorescein angiographic pattern and its association with visual outcome in idiopathic epiretinal membrane (ERM) removal.

**Methods:** Nonrandomized, retrospective, comparative, interventional case series at a tertiary care university hospital. Study population included idiopathic ERM patients with visual acuity of 20/200 to 20/30, intact ellipsoid zone (EZ), and postoperative follow-up of 6 months. Fluorescein angiography (FA) was conducted at baseline and followed by ERM removal. Optical coherence tomography (OCT) was assessed at baseline and follow-up visits. Main outcome measures were FA pattern in macula and changes in visual acuity (VA) and OCT findings.

**Results:** Of the total 46 eyes, 22 eyes (47.8





%) showed hyperfluorescence of the macula in mid-phase FA (leak group). Their baseline parameters including VA and central macular thickness (CMT) were not different from eyes without leakage (nonleak group,  $n = 24$ ), except for inner retinal layers over the fovea (11 vs 19,  $P = 0.004$ ). The leak group showed the worse VA (logarithm of the minimum angle of resolution, logMAR) (0.23 vs 0.12,  $P = 0.038$ ) and thicker CMT (376.52 vs 316.39  $\mu\text{m}$ ,  $P = 0.007$ ) at 6 months. Logistic regression analysis showed that the baseline FA pattern and VA were associated with final VA  $\geq 20/25$  ( $P = 0.028$  and  $P = 0.019$ , respectively).

**Conclusions:** Approximately half of idiopathic ERM patients showed leakage of the macula on FA. This FA pattern indicated the advanced damage in the inner retinal layers and provided a predictive value for visual prognosis after ERM removal.

---

**Poster No.: EX1-089**

**Atypical Pathological Changes Detected on Multimodal Imaging in Patients on Long-Term Hydroxychloroquine Therapy**

*First Author: Carlo LADORES*

*Co-Author(s): Chui Ming Gemmy CHEUNG, Cheng Sim Anna TAN, Tien Yin WONG, Yew San Ian YEO*

**Purpose:** To describe atypical pathological changes detected on multimodal imaging in patients on long-term hydroxychloroquine (HCQ) therapy.

**Methods:** This retrospective case series reports findings on multimodal imaging with fundus autofluorescence (FAF), optical coherence tomography (OCT), Humphrey visual field (HVF), multifocal electroretinography (mfERG), and microperimetry.

**Results:** Four patients on long-term (range, 10-30 years; mean, 18.5 years) HCQ therapy with dosage of 200-300 mg/day for either rheumatoid arthritis or systemic lupus erythematosus were included. In all eyes, visual acuity was better than 6/9 with a normal clinical exam. Case 1: FAF and OCT were normal, however bilateral central scotomas

were noted on microperimetry and HVF with mild reduction in the central mfERG right eye responses. Case 2: Right eye FAF showed areas of hypoautofluorescence surrounded by areas of hyperautofluorescence while OCT showed drusen and thick choroid. No abnormalities were noted on microperimetry or HVF. Case 3: FAF showed bilateral perifoveal focal hypoautofluorescent areas extending to the arcades with corresponding photoreceptor layer thinning on OCT. Case 4: FAF showed increased bilateral foveal hypoautofluorescence with no bull's eye pattern while OCT showed thinned areas of the perifoveal photoreceptor layer.

**Conclusions:** Early pathological retinal changes, atypical of bull's eye maculopathy, can be detected by multimodal imaging in patients on long-term HCQ therapy with good vision and a normal clinical exam. Apart from HCQ toxicity, differential diagnoses like pachychoroid disease from concomitant steroid use or comorbidities like age-related macular degeneration should be considered. However, HCQ cessation should be a primary consideration in high-risk patients.

---

**Poster No.: EX1-090**

**Bilateral Acute Retinal Pigment Epitheliitis: A Case Report With Microperimetry, Autofluorescence, Retinal Angiography, and Spectral-Domain Optical Coherence Tomography Findings**

*First Author: Yen YEW*

*Co-Author(s): Nicholas ANDREW, Alexander NEWMAN, Niladri SAHA*

**Purpose:** To describe the multimodal imaging characteristics of a case of bilateral acute retinal pigment epitheliitis (ARPE, also known as Krill disease).

**Methods:** This observational case report describes the presentation and retinal imaging findings of a case of bilateral ARPE.

**Results:** An 11-year-old Caucasian adolescent male presented with a 5-week history of bilateral paracentral visual scotomas. There was no significant medical or ocular





history; however, the visual disturbance was preceded by a mild flu-like illness, which had resolved by the time of presentation. Visual acuity at presentation was 6/4.8 in the right eye and 6/6 in the left. Posterior segment examination revealed multifocal parafoveal hyperpigmented lesions with surrounding hypopigmented haloes. Spectral-domain optical coherence tomography (SD-OCT) with enhanced depth imaging showed focal disruption of the inner segment ellipsoid band with thickening and hyperreflectivity of the retinal pigment epithelial interdigitation zone. The choroid was of normal thickness. The lesions were hypoautofluorescent. On both fluorescein angiography and indocyanine green angiography, the pigmented lesions were hypofluorescent with surrounding annular transmission hyperfluorescence. At 6-month review, his vision had stabilized at 6/6 in the right eye and 6/9.5 in the left. The appearance of the maculae was unchanged. Microperimetry demonstrated small paracentral scotomas corresponding to the retinal lesions.

**Conclusions:** This presentation was consistent with bilateral acute retinal pigment epitheliitis. We report the features on multimodal imaging and describe the first utilization of microperimetry in a patient with ARPE.

**Poster No.: EX1-091**  
**Clinical Features of Macular Serous Detachment According to Age Groups in Koreans**

*First Author: Kunho BAE*  
*Co-Author(s): Eung Suk KIM, Seung Young YU*

**Purpose:** To investigate the causes of macular serous retinal detachment without hemorrhage at the macula in patients 40 years and older.

**Methods:** A total of 394 eyes of 363 consecutive Korean patients aged 40 years and older with macular serous retinal detachment were examined using spectral domain optical coherence tomography, fluorescein, and indocyanine green angiographies.

**Results:** Of 394 eyes, 178 eyes (45.2%) had

central serous chorioretinopathy (CSC), 171 eyes (43.4%) had polypoidal choroidal vasculopathy (PCV), 32 eyes (8.1%) had occult choroidal neovascularization (CNV) secondary to age-related macular degeneration, 8 eyes (2.0%) had pure retinal pigment epithelial detachment, 1 had macular telangiectasia, and another had retinal macroaneurysm. A total of 162 of 237 (68.4%) eyes of patients in the sixth decade of life and older had PCV.

**Conclusions:** PCV is a primary cause of macular serous retinal detachment without hemorrhage in Korean patients over 50 years of age. Since clinical and fluorescein angiographic findings are indistinguishable among CSC, PCV, and occult CNV, indocyanine green angiography might help to establish a more definitive diagnosis.

**Poster No.: EX1-092**  
**Clinical Profile of Retinal Vein Occlusion in Hospital Universiti Sains Malaysia: 7-Year Review**

*First Author: Abdul Hadi ROSLI*  
*Co-Author(s): Zunaina EMBONG, Khairul Anwar IBRAHIM*

**Purpose:** To review the clinical profile of retinal vein occlusion (RVO) in Hospital Universiti Sains Malaysia (USM).

**Methods:** A case series.

**Results:** A total of 31 patients with a diagnosis of RVO in Hospital USM between 2011 and 2017 were reviewed. All of our patients were aged more than 40 years old and were predominantly male (20 male and 11 female). Out of 31 patients, 28 patients were Malay and another 3 patients were Chinese. A total of 16 patients were diagnosed with central RVO (ischemic: 6 and nonischemic: 10), while 15 patients had branch RVO. The majority of the patients (29) had associated medical illnesses such as hypertension, diabetes mellitus, and hyperlipidemia. Only 2 of the patients had no associated medical illness. All patients had received treatment, of which 23 patients received intravitreal anti-vascular endothelial





growth factors (VEGF) only while another 8 patients received a combination of anti-VEGF and panretinal photocoagulation therapy. After treatment, 15 patients showed visual improvement of about  $\geq 2$  lines. The remainder of the patients either had no improvement or worsening of visual acuity.

**Conclusions:** RVO is most likely associated with underlying medical conditions such as hypertension, diabetes mellitus, and hyperlipidemia. About 50% of the patients who received treatment showed visual improvement.

---

Poster No.: EX1-093

### Comparison Among Four Different Optical Coherence Tomography Angiography Systems for Retinal Vascular Imaging

First Author: Jingyuan **YANG**

Co-Author(s): Youxin **CHEN**, Guoru **LAN**, Song **XIA**, Chenxi **ZHANG**, Xiao **ZHANG**

**Purpose:** To compare the imaging performance of 4 optical coherence tomography angiography (OCTA) systems with different algorithms quantitatively.

**Methods:** Macular OCTA imaging ( $3 \times 3 \text{ mm}^2$ ) was performed on 16 eyes from 8 healthy volunteers using AngioVue OCTA, AngioPlex OCTA, swept-source OCTA (SS OCTA), and Spectralis OCTA. After image registration, vascular connectivity, vascular density, image contrast, image signal-to-noise ratio (SNR), and vascular specificity were calculated, and grayscale distribution curves were drawn.

**Results:** The vascular connectivity, image contrast, and image SNR of Spectralis OCTA were significantly greater than AngioVue OCTA, AngioPlex OCTA, and SS OCTA, while there was no significant difference among AngioVue OCTA, AngioPlex OCTA, and SS OCTA. The vascular density of Spectralis OCTA was significantly greater than the other 3 OCTA systems, while the vascular specificity of Spectralis OCTA was significantly lower than the others. There was no significant difference in vascular density or vascular specificity between SS OCTA and AngioVue OCTA or between SS

OCTA and AngioPlex OCTA. The grayscale distribution curve of Spectralis OCTA showed a higher proportion of white pixels than the other OCTA systems.

**Conclusions:** All of the systems were able to generate high-quality images with distinct and fine retinal capillary networks. AngioVue OCTA, AngioPlex OCTA, and SS OCTA showed similar performance, and it seems possible to compare or use their images simultaneously. Spectralis OCTA with high image contrast and SNR is hard to analyze further due to possible multiple thresholds in an OCTA image.

---

Poster No.: EX1-094

### Correlation of Optical Coherence Tomography Angiography Features of Idiopathic Polypoidal Choroidal Vasculopathy With Indocyanine Green Angiography

First Author: Rakesh **JUNEJA**

Co-Author(s): Navneet **MEHROTRA**, Manish **NAGPAL**

**Purpose:** To correlate angiographic findings of idiopathic polypoidal choroidal vasculopathy (IPCV) on indocyanine green angiography (ICGA) with morphological features on optical coherence tomography angiography (OCTA) before and after treatment.

**Methods:** Prospective, interventional study in 20 eyes of 20 patients treated with focal laser and anti-vascular endothelial growth factor (VEGF), who underwent baseline OCTA and ICGA. All cases were followed up at 1, 3, and 6 months.

**Results:** ICGA detected polyps in 20 and branching vascular networks (BVNs) in 17 eyes. OCTA detected each in 14 eyes. Before treatment, BVN appeared as a hyperflow lesion and polyp as a hyperflow round structure surrounded by a hypointense halo corresponding to the hyperfluorescent area, surrounded by a hypofluorescent halo and a hyperfluorescent hot spot on ICGA. After treatment, there was a decrease in size and number that corresponded to reduced hypofluorescent halo and hyperfluorescent hot spot on ICGA.



**Conclusions:** OCTA as a noninvasive tool correlates accurately with ICGA findings for assessing the polyps and BVNs in IPCV. It can be used as an alternative diagnostic test.

**Poster No.: EX1-095**  
**Etiology and Prognostic Significance of Hyperreflective Outer Retinal Track Lines on SD-OCT in Central Retinal Vein Occlusion Macular Edema**

*First Author: Mohab ELDEEB*  
*Co-Author(s): Errol CHAN, John CHEN, Vincent SUN*

**Purpose:** Outer retinal hyperreflective track lines develop after resolution of macular edema (ME) in central retinal vein occlusion (CRVO). We aimed to identify factors associated with their development and to analyze their impact on structural and functional outcomes.

**Methods:** Retrospective case-control study of 45 eyes with CRVO-associated ME on anti-vascular endothelial growth factor (VEGF) treatment for 1 year. Eyes were categorized by presence or absence of track lines on SD-OCT into track line (+) and (-) groups, respectively. The 2 groups were compared in terms of baseline SD-OCT parameters and interval change in these parameters from baseline to first achievement of dry macula. Associations between track lines with outer retinal structural changes and visual acuity (VA) at 1 year were analyzed.

**Results:** Sixteen (35.6%) eyes had track lines after ME resolution. At baseline, track line (+) eyes had higher central subfield thickness (CST) than track line (-) eyes ( $711 \pm 185$  vs  $590 \pm 147$ ;  $P = 0.035$ ), larger reduction in CST ( $-428 \pm 174$  vs  $-279 \pm 179$ ;  $P = 0.01$ ), and greater increase in external limiting membrane (ELM) disruption from baseline to the visit when dry macula was first achieved ( $206 \pm 462$  vs  $-82 \pm 213$ ;  $P = 0.029$ ). At 1 year, eyes with track lines had worse VA ( $1.31 \pm 0.83$  vs  $0.38 \pm 0.25$ ;  $P < 0.001$ ) and greater ellipsoid zone (EZ) disruption ( $588 \pm 599$  vs  $232 \pm 267$ ;  $P = 0.036$ ).

**Conclusions:** Track lines develop in eyes with more extensive ME and could represent

disrupted ELM. They appear to prognosticate greater EZ loss and poorer visual outcomes despite successful anti-VEGF treatment.

**Poster No.: EX1-096**  
**Granular Cell Tumor With Intraocular Involvement**

*First Author: Jingyuan YANG*  
*Co-Author(s): Youxin CHEN*

**Purpose:** To report the first case of granular cell tumor (GCT) with intraocular involvement.

**Methods:** A 5-year-old Chinese girl who had exhibited exotropia in her right eye for 2 years and had been losing her vision for 6 months was referred to our department. The visual acuity in the right eye revealed no light perception, with an intraocular pressure of 7 mm Hg. Fundus examination showed a large, yellowish-white, elevated, subretinal mass lesion in front of the disc, with hemi-inferior quadrant retinal detachment. Examination of the left eye showed no abnormalities. A general examination of the child revealed no other abnormalities. B-scan ultrasonography of the right eye revealed a solid intraocular mass located in front of the disc, with moderate-to-high internal reflectivity, a distinctive border, and no calcification. Computed tomography and magnetic resonance imaging showed no involvement of the extraocular muscles, optic nerve, or intraorbital tissues.

**Results:** A vitreous biopsy for tumor cells was performed, and the result was negative. After 9 months, a vitrectomy with lensectomy and neoplasm resection was performed for histopathological examination. Histopathologic and immunohistochemical examination of the intraocular mass revealed a granular cell tumor, and pustulo-ovoid bodies of Milian were found. The Ki-67 index was 1%.

**Conclusions:** To the best of our knowledge, this is the first report of an intraocular GCT. The origin of GCTs remains unknown. Because GCTs can be multiple and occur throughout the body, a careful fundus examination is recommended and critical to perform in all patients with GCTs.



Poster No.: EX1-097

### ICGA-Based Classification of Wet AMD in Korean Patients

First Author: Kunho **BAE**

Co-Author(s): Eung Suk **KIM**, Seung Young **YU**

**Purpose:** To propose a novel classification of neovascular age-related macular degeneration (AMD) based on indocyanine green angiography (ICGA) and to compare the optical coherence tomography (OCT) findings and visual outcomes.

**Methods:** This study involved 187 consecutive patients who were diagnosed as treatment-naive exudative AMD. Eyes were divided into 5 groups according to the ICGA findings as follows: 1) classic choroidal neovascularization (CNV), 2) occult CNV, 3) interconnecting channel/microaneurysm (ICM), 4) polypoidal choroidal vasculopathy (PCV), and 5) retinal angiomatous proliferation (RAP). Best-corrected visual acuity (BCVA) and OCT findings were compared between the groups at baseline and 12 months after the initial visit. In addition, spectral-domain OCT angiography was performed in the latest consecutive cases.

**Results:** Among the patients, 10 eyes (5.3%) were classic CNV, 30 eyes (16.0%) were occult CNV, 71 eyes (38.0%) were ICM, 62 eyes (33.2%) were PCV, and 14 eyes (7.5%) eyes were RAP. Mean logarithm of the minimum angle of resolution (logMAR) BCVA improved most in the PCV group and least in the RAP group but was not significant (0.22 vs -0.09,  $P = 0.187$ ). Subfoveal choroidal thickness was 259.6  $\mu\text{m}$  in ICM, 247.7  $\mu\text{m}$  in PCV, and 108.0  $\mu\text{m}$  in RAP, and the difference was significant ( $P = 0.012$ ).

**Conclusions:** The classification system of this study consisted of classic CNV, occult CNV, interconnecting channel/microaneurysm, PCV, and RAP based on ICGA findings. The response to treatment and OCT findings varied depending on the subtypes.

Poster No.: EX1-098

### Irregular Pigment Epithelial Detachment in Chronic Central Serous Chorioretinopathy: SD-OCT and OCTA Findings

First Author: Seul Ki **BANG**

Co-Author(s): Eung Suk **KIM**, Seung Young **YU**

**Purpose:** To evaluate the prevalence of irregular pigment epithelial detachment (PED) in chronic central serous retinopathy (CSC) and to identify the incidence of neovascular change in patients with CSC during follow-up.

**Methods:** A review of medical records of 142 eyes with chronic CSC which were examined in the Ophthalmology Department of Kyunghee University Hospital retrospectively. Analysis of spectral domain optical coherence tomography (SD-OCT), fluorescein angiography (FA), indocyanine green angiography (ICGA), and optical coherence tomography angiography (OCTA) findings was done.

**Results:** Forty-seven eyes of 142 eyes (33.1%) showed irregular PED on macular OCT findings. The mean age was 53.45 years in the irregular PED group and 49.73 years in the nonirregular PED group. In 12 eyes of 47 eyes (25.5%) neovascular change occurred during the follow-up, especially 9 eyes with choroidal neovascularization (CNV) and 3 eyes with polypoidal choroidal vasculopathy (PCV). Mean duration at onset of neovascular change was  $41.83 \pm 46.28$  months. To compare eyes with and without neovascular change in patients with irregular PED, follow-up duration of the neovascular change group was 45.25 months and of the control group was 21.46 months. There was a significant difference between the groups ( $P = 0.009$ ). The presence of optically filled sub-retinal pigment epithelium (sub-RPE) space was 11 eyes (91.7%) in the neovascular change group and 14 eyes (40.0%) in the control group. There was a significant difference between the groups ( $P = 0.011$ ). Type 1 neovascular networks were detected in 5 out of 8 eyes (67.5%) on OCTA.

**Conclusions:** The presence of irregular PED was significantly correlated with neovascular





change. The opacity of the sub-RPE space was significantly correlated with progression of neovascular change.

Poster No.: EX1-099

### OCT Angiography Compared to Dye Angiography for Distinguishing Vascularized Pigment Epithelial Detachment

First Author: Danny **NG**

Co-Author(s): Malini **BAKTHAVATSALAM**, Marten **BRELEN**, Timothy **LAI**, Chi Wai **TSANG**

**Purpose:** To determine the reliability of optical coherence tomography angiography (OCTA) compared to fluorescein (FA) and indocyanine green angiography (ICGA) to distinguish a vascularized pigment epithelial detachment (PED).

**Methods:** A total of 105 consecutive eyes of 75 patients with PED underwent FA, ICGA, and OCTA. Masked graders evaluated the images.

**Results:** Fifty had polypoidal choroidal vasculopathy, 25 had age-related macular degeneration, 9 had central serous chorioretinopathy (CSC), and the rest were asymptomatic. The sensitivity of OCTA was 79.7% and specificity was 74.2%. The false negative group was significantly older, had worse visual acuity, more extrafoveal neovascularization, greater maximum PED height, and lower OCTA image quality score. Four CSC eyes had nonexudative neovascularization graded on OCTA that were not detected on dye angiography.

**Conclusions:** Multimodal imaging enhanced the assessment for vascularized PED. Recognition of factors associated with reliability of OCTA helps improve clinical decision making.

Poster No.: EX1-100

### Optical Coherence Tomography Angiography Findings in Retinal Vein Occlusion Treated With Anti-Vascular Endothelial Growth Factor

First Author: Eung Suk **KIM**

Co-Author(s): Kunho **BAE**, Seul Ki **BANG**, Seung Young **YU**

**Purpose:** To study correlations in patients

with retinal vein occlusion between the vascular densities in the superficial and deep capillary plexus (SCP and DCP) obtained using wide-field optical coherence tomography angiography (OCTA) and the data from conventional examination, particularly visual acuity and frequency of intravitreal anti-vascular endothelial growth factor (VEGF) injections.

**Methods:** Retrospective, observational study of patients with retinal vein occlusion who underwent a comprehensive ophthalmic examination including OCT and wide-field (12 x 12 mm) swept source OCTA using the AngioPLEXTM ELITE 9000 (Carl Zeiss Meditec, Germany). Vascular densities in the SCP and DCP, as well as the area of the foveal avascular zone and nonperfusion, were measured using ImageJ software.

**Results:** Among 29 eyes of 28 patients (12 men; mean age, 63.5 years), 20 eyes had branch retinal vein occlusion (BRVO) and 9 eyes had central retinal vein occlusion (CRVO). In BRVO, significant negative correlation was shown between vascular density in DCP and logarithm of the minimum angle of resolution (logMAR) visual acuity at baseline and final visit ( $P = 0.019$ ,  $P = 0.005$ , respectively). In CRVO, we also found a significant negative correlation between vascular density in DCP and logMAR visual acuity at the final visit ( $P = 0.023$ ). The number of intravitreal anti-VEGF injections per month was positively correlated with the area of nonperfusion in SCP ( $P = 0.034$ ) and in DCP ( $P = 0.031$ ).

**Conclusions:** Using wide-field swept source OCTA, we may do qualitative and quantitative analysis of macular and peripheral area by layers in RVO. OCTA may be considered as a clinical utility tool for the diagnosis and follow-up of RVO patients.

Poster No.: EX1-101

### Outcome of Pneumatic Displacement in Submacular Hemorrhage Without Using Tissue Plasminogen Activator

First Author: Roshija **RIJAL**

Co-Author(s): Deepesh **MOURYA**

**Purpose:** To evaluate the outcome of





pneumatic displacement in submacular hemorrhage (SBM) without using tissue plasminogen activator (tPA).

**Methods:** This was a retrospective, nonrandomized, and interventional study. All patients had received 0.3 cc C3F8 gas with or without anti-vascular endothelial growth factor (VEGF) [in patients with choroidal neovascular membrane (CNVM)] after paracentesis followed by head down positioning for at least 2 weeks. The main outcome measure was anatomically cleared SBM at least 1 disc diameter from the foveal center at the end of 1 month. Secondary outcome included best corrected visual acuity (BCVA) at 3 months.

**Results:** There were a total of 22 patients, 11 males and 11 females, with a mean age of 50.09 years. The mean duration of presentation was 19.5 days (range, 3 to 60 days). The cause for SBM was CNVM in 14 and trauma in 8. Anatomical clearing of SBM was achieved in all but 1 patient. The mean pre- and postprocedural BCVA were  $1.62 \pm 0.39$  and  $0.98 \pm 0.5$ . The improvement in vision was statistically significant. The cause for poor visual outcome was disciform scar and choroidal rupture under the fovea.

**Conclusions:** Pneumatic displacement without tPA can be an effective modality of treatment for SRH. Its benefits can outweigh the risks of intravitreal tPA at a lower cost.

**Poster No.: EX1-102**  
**Ozurdex Induced Fulminant Toxoplasma Retinochoroiditis in a Patient Treated for Neuroretinitis**

*First Author: Arif Hayat KHAN PATHAN*  
*Co-Author(s): Mohammad Ibn ABDUL MALEK, Tanvir AHMED, Brooke NESMITH, Mostafizur RAHMAN, Nazmun NAHAR*

**Purpose:** To report a case of fulminant toxoplasma chorioretinitis with retinal detachment that developed after intravitreal injection of Ozurdex.

**Methods:** Case report.

**Results:** A 27-year-old female, previously

treated with intravenous steroids for neuroretinitis in her right eye thought to be secondary to sphenoidal sinusitis, presented with sudden pain, redness, and dimness of vision in the same eye. She had received Ozurdex and Avastin injections in her right eye several months prior. An aqueous and vitreous tap was performed and polymerase chain reaction (PCR) was positive for toxoplasma. She was managed with pars plana vitrectomy, removal of the Ozurdex implant, and administration of intravitreal injection of clindamycin. Subsequently she developed a retinal detachment with posterior subcapsular cataract that was managed with phacoemulsification and intraocular lens (IOL) implant, scleral buckle, pars plana vitrectomy, and injection of silicone oil. Vision improved and inflammation was resolved with antitoxoplasmosis therapy.

**Conclusions:** Inadvertent use of corticosteroid therapy may induce the fulminant form of ocular toxoplasmosis.

**Poster No.: EX1-103**  
**Perspective on the Role of Corticosteroid Treatment for Bilateral Diabetic Macular Edema in Pregnancy: A Case Report**

*First Author: Ing Hong LIM*  
*Co-Author(s): Nor Azita AHMAD TARMIDZI, Hamisah ISHAK, Amir SAMSUDIN*

**Purpose:** A case report to prove the efficacy and safety of intravitreal corticosteroid 0.7 mg as an adjunct in the treatment of diabetic macular edema causing visual impairment in a pregnant woman.

**Methods:** Case report.

**Results:** We report a case of substantial resolution of central macular edema in bilateral eyes of a 31-year-old pregnant patient after slow-release dexamethasone 0.7 mg intravitreal implantation (Ozurdex) for treatment of diabetic macular edema. This patient presented with worsening bilateral diabetic macular edema (DME) during her first trimester. She was monitored fortnightly till 6 weeks postdelivery





after receiving intravitreal Ozurdex implantation in both eyes on 2 separate occasions with multidisciplinary collaboration for observation and management. Close monitoring with optical coherence tomography (OCT) after Ozurdex implantation showed significant reduction in central macular thickness of both eyes with complete recovery of bilateral visual acuity. No prenatal or postnatal abnormalities were detected.

**Conclusions:** Intravitreal corticosteroid treatment is proven safe and beneficial in this case of diabetic macular edema in pregnancy. Further study is warranted to assess the safety and efficacy of intravitreal corticosteroid in pregnant mothers with diabetic macular edema.

---

Poster No.: EX1-104

**Polypoidal Choroidal Vasculopathy: A Composite Assessment of Sociodemographic, Behavioral, and Systemic Associations**

First Author: Raghav **RAVANI**

Co-Author(s): Prateek **KAKKAR**, Atul **KUMAR**, Vineet **MUTHA**, Dheepak **SUNDAR**

**Purpose:** To evaluate the sociodemographic, behavioral, and systemic associations with polypoidal choroidal vasculopathy (PCV) in North India. This study was done to assess the prevalence of formerly unknown factors such as lack of sleep, stress, socioeconomic status, and exercise in patients with PCV in addition to previously studied factors such as diabetes, hypertension, heart disease, smoking, alcoholism, diet, sunlight exposure, obesity, and homocysteinemia because controversies exist amid various publications.

**Methods:** Seventy-seven patients (cases) with unilateral or bilateral, indocyanine green angiography (ICGA) diagnosed PCV were compared with age- and sex-matched subjects with different ocular disease presenting to the same ophthalmic center (controls, n = 177). All 354 subjects underwent a history-based assessment of diet, smoking habits, alcohol consumption, sleep patterns, exercise, stress scores based on a 4-item Perceived Stress Scale (PSS), socioeconomic status, sunlight exposure,

systemic diseases, and obesity.

**Results:** Mean age of PCV cases and controls was  $66 \pm 6$  and  $66 \pm 9$  years with 57% and 62% males, respectively. There was no statistically significant difference ( $P > 0.05$ ) between the 2 groups with reference to diet, smoking, alcoholism, exercise, diabetes mellitus, ischemic heart disease, and plasma homocysteine. Stress, lack of sleep, obesity, hypertension, and higher socioeconomic status ( $P < 0.05$ ) were more commonly seen in PCV cases. Central serous chorioretinopathy (CSC) preceded PCV in 10% of cases.

**Conclusions:** Stress, obesity, hypertension, lack of sleep, and higher socioeconomic status are more prevalent in patients with PCV while diabetes, heart disease, smoking, alcoholism, diet, and homocysteinemia are not.

---

Poster No.: EX1-105

**ROP Diaries of a Retinal Surgeon in an Indian Scenario**

First Author: Aditya Vikram **SHARMA**

Co-Author(s): Maniprabha **BHATNAGAR**, Sunil **JANGED**, Aditi **SHARMA**

**Purpose:** To describe our experience in screening and management of retinopathy of prematurity (ROP) in premature infants admitted into neonatal intensive care units. A comprehensive review was performed of the protocols already suggested and their importance in a developing economy, which has one of the highest burdens of preterm deliveries.

**Methods:** This study is a retrospective, interventional, consecutive case series with a time span of 2 years.

**Results:** A total of 348 newborns were screened and followed up for 12 weeks. Those showing signs of disease or needing intervention were seen regularly till regression was noted. Incidence of ROP was 9.77% (34 babies) in the study population. Among them 8 required laser photocoagulation (both eyes) and 3 babies were given intravitreal injection of anti-VEGF (vascular endothelial growth factor) in



both eyes, followed by laser photocoagulation. Majority of the disease was seen in babies having gestational age of 30-34 weeks (3.16%), birth weight between 1000-1500 g (2.29%), and prolonged oxygen support (2.87%). Disease was completely regressed clinically in treated babies on last follow-up. None of them progressed to severe form or required further intervention.

**Conclusions:** Retinopathy of prematurity (ROP) is an avoidable cause of childhood blindness. Awareness among pediatricians and eye specialists will contain the morbidity and also halt the progression, thus significantly reducing the disease burden. A solid protocol, dedicated team work, and minimal infrastructure can also reap great results.

---

**Poster No.: EX1-106**

### **Retinal Fractal Dimension and Curvature Tortuosity in Obese Children**

*First Author: Evelyn TAI*

*Co-Author(s): Shatriah ISMAIL, Yee Cheng KUEH, Wan Hazabbah WAN HITAM, Tien Yin WONG*

**Purpose:** Alterations of retinal vessel calibers have been observed in obesity, with narrower arterioles and wider venules seen in obese children. However, other retinal vascular parameters have not been widely researched. We thus aimed to compare retinal vascular fractal dimension and curvature tortuosity between obese and nonobese children.

**Methods:** This was a cross-sectional study in Malaysia involving 166 children aged 6 to 12 years old with a normal ocular examination. All children underwent ocular biometry, retinal photography, and blood pressure and body mass index (BMI) measurement. Participants were divided into 2 groups; obese and nonobese. Retinal arteriolar and venular fractal dimension and curvature tortuosity were measured using validated software, the Singapore I Vessel Assessment (SIVA). Larger fractal dimension values represent a more complex branching pattern, while higher curvature tortuosity values represent more tortuous vessels.

**Results:** Mean age was 9.58 years.

Approximately 51.2% were obese. Obese children had higher venular fractal dimension [ $F(1,161) = 6.857, P = 0.010$ ] and curvature tortuosity [ $F(1,160) = 5.325, P = 0.022$ ] than nonobese children, after adjustment for age, blood pressure, and axial length. No significant differences in arteriolar fractal dimension and curvature tortuosity were observed.

**Conclusions:** Retinal vascular parameters are abnormal in obese children. Microvascular disease in obesity likely begins in childhood, suggesting a role for early obesity interventions.

---

**Poster No.: EX1-107**

### **Short-Term Treatment Response of Large Pigment Epithelial Detachment Due to Age-Related Macular Degeneration to Anti-VEGF Therapy**

*First Author: Yu ZHANG*

*Co-Author(s): Chui Ming Gemmy CHEUNG, Kelvin Yi Chong TEO, Yasuo YANAGI*

**Purpose:** To assess the effects of anti-vascular endothelial growth factor (VEGF) drugs for large pigment epithelial detachment (PED) secondary to age-related macular degeneration (AMD).

**Methods:** Medical records of 25 eyes of 24 patients that were treated with monthly injections of 1.25 mg bevacizumab ( $n = 15$ ) or 0.5 mg ranibizumab ( $n = 10$ ) for at least 3 months were reviewed retrospectively. Best-corrected visual acuity (BCVA; logarithm of the minimum angle of resolution, logMAR) and spectral-domain optical coherence tomography (SD-OCT) were performed at all visits. PEDs were graded as hollow and solid based on their reflectivity on SD-OCT at baseline.

**Results:** There was no significant change in mean BCVA in both the bevacizumab ( $0.61 \pm 0.48$  to  $0.52 \pm 0.51$ ) and ranibizumab ( $0.64 \pm 0.53$  to  $0.60 \pm 0.52$ ) groups ( $P = 0.158, P = 0.897$ ). The PED height was  $507.5 \pm 250.5 \mu\text{m}$  and  $444.6 \pm 294.0 \mu\text{m}$  at baseline and significantly reduced to  $320.0 \pm 265.9 \mu\text{m}$  and  $339.6 \pm 370.3 \mu\text{m}$  at month 3 in the bevacizumab and ranibizumab groups,



respectively ( $P = 0.002$  and  $0.022$  vs baseline), with no difference between the 2 groups ( $P = 0.894$ ). There were 9 hollow-type and 6 solid-type PEDs in bevacizumab and 4 hollow-type and 6 solid-type PEDs in the ranibizumab group. In the bevacizumab group, there was a significant reduction in PED height in hollow-type PED ( $P = 0.005$ ), whereas in the ranibizumab group, the reduction was observed in solid-type PED ( $P = 0.031$ ). PED completely resolved in 3 eyes at month 3. Two eyes developed retinal pigment epithelium (RPE) tear.

**Conclusions:** Both bevacizumab and ranibizumab were effective in treating PED secondary to AMD, with no difference in the efficacy between the 2 drugs. Bevacizumab was more effective in treating hollow PED while ranibizumab was in solid PED. These findings warrant further investigation.

**Poster No.: EX1-108**  
**Spectral-Domain Optical Coherence Tomography Evaluation Including En-Face Imaging of the Fluorescein Angiographic Leak in Acute Central Serous Chorioretinopathy**

*First Author: Neha GOEL*  
*Co-Author(s): Aanchal MEHTA*

**Purpose:** To investigate morphological changes around fluorescein leakage sites in acute central serous chorioretinopathy (CSC) (<1 month duration) using spectral-domain optical coherence tomography (SD-OCT) and en-face imaging.

**Methods:** Prospective observational study. A total of 103 eyes of 100 patients underwent complete ophthalmological examination, fluorescein angiography (FA), and SD-OCT. Horizontal and vertical B-scans and consecutive raster scans of the fovea and fluorescein leakage sites were obtained. En-face SD-OCT scans were acquired using the RTvue-100 SD-OCT.

**Results:** Mean age of the patients was 38.38 years (range, 22 to 63 years). Eighty-nine were males. SD-OCT revealed subfoveal

neurosensory detachment (NSD) and retinal pigment epithelium (RPE) abnormalities at the leakage site in all 103 eyes. Features noted were protruding RPE in 46 eyes (45%), pigment epithelial detachment (PED) within the NSD in 40 eyes (39%), fibrinous exudates in the subretinal space in 23 eyes (22%), and dipping of neurosensory retina in 20 eyes (19%). Protruding RPE was the commonest pattern seen in ink blot leaks (50.7%), while protruding RPE and PED were equally common in smokestack leaks (46.6%). None of the smokestack leaks showed presence of fibrin. En-face OCT images at the RPE level revealed specific changes at the leakage site in all eyes, which correlated with pathologic changes seen on cross-sectional SD-OCT and FA.

**Conclusions:** SD-OCT is safer and faster than FA and can be repeated more often. It reveals characteristic morphology of the leaks that may contribute to understanding mechanisms of CSC and also guide laser therapy where FA is contraindicated.

**Poster No.: EX1-109**  
**Spironolactone in the Treatment of Nonresolving Central Serous Chorioretinopathy: A Comparative Analysis**

*First Author: Jin Young KIM*  
*Co-Author(s): Mirinae JANG*

**Purpose:** To evaluate the effect of spironolactone, a mineralocorticoid receptor antagonist, for naive and nonresolving central serous chorioretinopathy.

**Methods:** A retrospective chart review was conducted of all central serous chorioretinopathy patients at 1 center treated with spironolactone (50 mg once a day) or observation. Thirty eyes of 30 patients with central serous chorioretinopathy and persistent subretinal fluid (SRF) for at least 8 weeks were enrolled. Patients were followed at monthly intervals with examination and optical coherence tomography. The primary outcome measure was the changes in SRF thickness from baseline to the apex of the serous retinal detachment. Secondary outcome included the



best-corrected visual acuity (BCVA).

**Results:** The mean duration of central serous chorioretinopathy before enrollment in study eyes was  $11.13 \pm 2.40$  weeks. Spironolactone demonstrated statistically significant visual acuity improvement ( $0.12 \pm 0.09$ ) and SRF reduction ( $273.07 \pm 71.16 \mu\text{m}$ ) at 3 months compared to baseline ( $0.25 \pm 0.17$ ,  $P = 0.003$ ;  $432.57 \pm 108.99 \mu\text{m}$ ,  $P = 0.001$ , respectively). Eight of the 14 patients with spironolactone had complete resolution of SRF at 3 months, compared to 6 of the 16 patients under observation ( $P = 0.377$ ). Data analysis showed a statistically significant improvement in SRF and visual acuity in spironolactone-treated eyes as compared with the same eyes under observation ( $P = 0.043$ ,  $P = 0.047$ , respectively). There were no complications related to treatment observed.

**Conclusions:** In naive eyes with persistent SRF due to central serous chorioretinopathy, spironolactone had a positive effect in the reduction of SRF and recovery of visual acuity.

Poster No.: EX1-110

### Structure-Function Correlation in Choroidal Neovascular Membrane Secondary to Wet Age-Related Macular Degeneration Using Novel Overlay Feature of Optical Coherence Tomography Angiography and Microperimetry-3

First Author: Rakesh JUNEJA

Co-Author(s): Jayesh KHANDELWAL, Navneet MEHROTRA, Manish NAGPAL

**Purpose:** To analyze and correlate the morphological and functional characteristics in choroidal neovascular membrane (CNVM) secondary to age-related macular degeneration (AMD) using the novel overlay feature of optical coherence tomography angiography (OCTA) and microperimetry-3 (MP3), before and after treatment.

**Methods:** Prospective, observational study involving 56 eyes of 44 patients diagnosed on OCT and fluorescein angiography (FA) (Hiedelberg, Spectralis) treated with intravitreal

anti-vascular endothelial growth factor (VEGF) injections, who underwent baseline OCTA (NIDEK RS 3000 Advance) and MP3 (NIDEK MP3) examination. Using the overlay feature, morphologic characteristics at the site of CNVM lesion were analyzed and correlated functionally before and after treatment at 1-month follow-up.

**Results:** OCTA in the pretreatment phase revealed CNVM as an abnormal vascular network arising from the choroid and invading the subretinal space. On MP3 decreased retinal sensitivity was observed corresponding to the area of CNVM. After treatment, OCTA revealed reduction of abnormal vascular network in 51 (91.07%) eyes that correlated with increased retinal sensitivity at the corresponding area in MP3 for all 51 eyes.

**Conclusions:** Combining the findings of OCTA and MP3 using the overlay feature gives us precise information of structure-function correlation at presentation and also in response to treatment.

Poster No.: EX1-111

### The Role of Apelin/APJ in the Animal Model of Retinopathy of Prematurity

First Author: Li CHEN

Co-Author(s): Yanrong JIANG

**Purpose:** The aim was to explore the effect of apelin in the development of physical retinal vessels and the pathological role in a retinopathy of prematurity (ROP) mouse model.

**Methods:** In normal mice, retina whole mount staining was used to evaluate the retinal vessel area; density, width, tip number, and length were evaluated at P7 and P10 after intraperitoneal injection of exogenous apelin (25 nmol/kg). An ROP mouse model was used to explore the progress of neovascularization and vaso-obliteration (VO) area. Quantitative real-time polymerase chain reaction (qRT-PCR) was used to determine the trend of apelin and APJ in normal and ROP mice retinas. Western blot analyzed the expression of phosphatidylinositol 3-OH kinase (PI3K) (p-mTOR), p-PI3K/Akt, and p-Erk





signaling pathway in the hypoxia stage after intraperitoneal injection of apelin and F13A (1 mg/mL).

**Results:** Apelin can promote the development of retinal superficial and deep vessels, especially for tip cells. The expression of apelin was dramatically increased during the hypoxic phase in ROP mice, which coexpressed with lectin in vessels. Apelin also stimulated the number and area of neovascularization in ROP17 mice. qRT-PCR data suggested the expression of apelin and APJ peaked at P14 in normal mice, while the expression of apelin peaked at ROP12-6h, which is earlier than the expression of APJ in ROP mice. Western blot results showed the expression of p-mTOR, p-Akt, and p-Erk were upregulated in ROP mice, while F13A downregulated these protein expressions.

**Conclusions:** These results suggest that apelin is a prerequisite factor for retinal angiogenesis. Apelin/APJ signaling is associated with p-mTOR (p-mTOR), p-PI3K/Akt, and p-Erk signaling in the pathology of vessels in ROP mice.

---

**Poster No.: EX1-112**

**Unheeded Focal Choroidal Excavations in Recurrent Central Serous Chorioretinopathy**

*First Author: V V SAMEERA*

*Co-Author(s): Apoorva AYACHIT, Guruprasad AYACHIT, Shrinivas JOSHI*

**Purpose:** To analyze the prevalence and characteristics of focal choroidal excavation (FCE) concurrent with central serous chorioretinopathy (CSCR) using multimodal imaging.

**Methods:** Prospective study with clinical features and multimodal imaging findings in eyes with CSCR and FCEs, using imaging methods including spectral domain optical coherence tomography (SD-OCT), enhanced depth imaging (EDI), fluorescein angiography (FA), infrared reflectance (IR), and fundus autofluorescence (FAF).

**Results:** Five eyes out of 19 eyes with chronic CSR had FCEs. All were males. Mean age of

the patients was 47 years. Three eyes had macular FCEs and 2 had distant extramacular FCEs. All eyes had type 2 FCEs. One patient had bilateral FCEs. We noted these FCEs as hyperautofluorescent areas on FAF which corresponded to the leaks as well on FA. Mean choroidal thickness of the uninvolved choroid was thicker than normal in all the eyes. No scleral ectasia was seen. In 3 months the subretinal fluid resolved completely with 577 nm micropulse laser therapy over the FCEs.

**Conclusions:** FCE is not uncommon in patients with CSCR. Multimodal imaging predicts the areas of FCEs and leaks and can aid in noninvasive localization of the area concerned for laser therapy. We recommend 12-mm scans in patients with CSCR to detect extrafoveal FCEs as well.

---

**Poster No.: EX1-113**

**Vascular Endothelial Growth Factor Level in Vitreous Humor of Proliferative Diabetic Retinopathy After Intravitreal Injection of Conbercept**

*First Author: Bing LI*

*Co-Author(s): Zhe CHEN, Junjie YE*

**Purpose:** To investigate the vascular endothelial growth factor (VEGF) level in vitreous of proliferative diabetic retinopathy (PDR) after intravitreal injection of conbercept.

**Methods:** Thirty-five eyes of 35 patients with PDR and 20 eyes of 20 patients diagnosed with rhegmatogenous retinal detachment (RRD) with proliferative vitreoretinopathy (PVR) were enrolled. Thirty-five eyes of PDR were randomly assigned into 2 groups. Twenty eyes in group A received 0.5 mg intravitreal conbercept 7-14 days before pars plana vitrectomy (PPV). The other 15 eyes in group B and 20 eyes with PVR in group C underwent PPV directly. Vitreous samples were collected at the beginning of PPV and VEGF concentrations were tested twice through enzyme linked immunosorbent assay (ELISA).

**Results:** There were 9 sanguineous specimens and 11 nonsanguineous specimens in group A;





mean VEGF concentrations were  $263.0 \pm 41.9$  pg/mL and  $36.9 \pm 5.1$  pg/mL, respectively. In group B, there were 6 sanguineous specimens and 9 nonsanguineous specimens, with mean VEGF concentrations of  $313.6 \pm 66.5$  pg/mL and  $68.2 \pm 12.6$  pg/mL. Samples in group C were all nonsanguineous specimens; mean VEGF concentration was  $1.7 \pm 1.1$  pg/mL. VEGF levels in groups A and B were markedly higher than in group C. That in nonsanguineous specimens in group A was significantly lower than group B, while there was no statistical significance in sanguineous specimens of the 2 groups.

**Conclusions:** VEGF level in the vitreous of severe PDR increases conspicuously. Intravitreal injection of conbercept could decrease VEGF levels within 2 weeks and may suppress the activity of neovessels to provide a relatively quiet condition for vitrectomy afterward. Bloody constituents may affect the assessment of VEGF levels in vitreous humor.

---

Poster No.: EX1-134

### A Rare Case of Choroidal Infiltration Secondary to Diffuse Large B-Cell Lymphoma in the Only Seeing Eye

First Author: Nik Nurfarhana **NIK MOHD NOOR**  
Co-Author(s): Kiet Phang **LING**, Haslina **MOHAMAD ALI**

**Purpose:** To report a case of choroidal infiltration secondary to diffuse large B-cell lymphoma (DLBCL) in a patient who had a history of evisceration in the other eye.

**Methods:** Case report.

**Results:** A 45-year-old male former intravenous drug user with underlying hepatitis C and DLBCL from left thigh mass presented with right eye painless, progressive, and gradual decrease in vision of 1-month duration. He had a history of evisceration in the other eye 14 years previously secondary to penetrating injury post motor vehicle accident. Ocular examinations revealed right vision of 6/18 with vitritis and multifocal yellowish retinal infiltrates involving the superior half of the

retina. There was no vasculitis, retinitis, or disc swelling. Anterior segment was normal. Optical coherence tomography (OCT) showed numerous irregular clumps of optically dense material at the level of the retinal pigmented epithelium with subretinal infiltration. Fundus fluorescence angiography (FFA) revealed multiple hyperfluorescence areas, which increased in the late phase corresponding to the area of choroidal infiltrates. Infective blood screening was negative. The clinical diagnosis of choroidal infiltration in lymphoma was made. He was referred to a hematologist and received a poor prognosis due to likely central nervous system (CNS) involvement and high risk of remission and hepatitis C flare-up if started on chemotherapy. He decided against vitreous biopsy and other interventions at the moment.

**Conclusions:** In this case, due to history of evisceration of the other eye and also immunocompromised state, sympathetic ophthalmia and infective cause should be taken into account. OCT and FFA capabilities allow characterization of the intraocular lymphoma infiltration, which is particularly helpful in a patient who refuses vitreous biopsy.

---

Poster No.: EX1-135

### Mutation of CRX and RHO Genes in Retinitis Pigmentosa

First Author: Ma **XIANG**

**Purpose:** To analyze a late-onset retinitis pigmentosa (RP) CRX gene mutation in the southern area of Liaoning Province and sporadic retinitis pigmentosa patients with RHO gene mutation and to investigate the correlation between retinal pigment degeneration and CRX and RHO gene mutation.

**Methods:** We collected patients with primary RP (including familial and sporadic) by screening history, age of onset, clinical manifestations, and related instruments inspection with late-onset autosomal dominant RP. The late-onset family included a total of 22 people, with an incidence of 9 members and the remainder as normal siblings and their spouses. There





were 28 patients with sporadic RP, aged 19-65 years. By polymerase chain reaction (PCR) in exon 3 of the CRX gene and RHO gene 5 exon amplification, CRX and RHO were compared with the normal gene to identify the mutation sites and mutation types.

**Results:** The sequence of 3 exons and coding regions of the CRX gene in the late-onset RP family was not detected, and no mutations associated with the studied disease or adjacent splice site were found. The RHO gene sequences with RP were consistent with NCBI (NM\_000539) sequences, and no significant mutations in exon 5 of the RHO gene were found.

**Conclusions:** There is no significant correlation between the pathogenic factors of the late-onset hereditary RP family and the mutation of the CRX gene in southern Liaoning Province. The same gene varies in different countries or races. The mutation rate of the RHO gene is low in patients with sporadic RP in southern Liaoning Province.

**Poster No.: EX1-138**  
**The Change of Choroidal Thickness in Adult Koreans**

*First Author: Hyunkyung KIL*  
*Co-Author(s): Munjung CHOI*

**Purpose:** To evaluate the change of choroidal thickness in Koreans by age.

**Methods:** One hundred ten eyes of 65 patients were included in this randomized, prospective cross-sectional study. The choroid was imaged in all subjects using enhanced depth imaging (EDI) with Cirrus. The choroid was measured subfoveally, 1000  $\mu\text{m}$  temporal, 2000  $\mu\text{m}$  temporal, 1000 nasal, and 2000 nasal to the fovea.

**Results:** The mean age was  $51.3 \pm 14.97$  years (range, 21-80 years). A statistically significant difference was found in choroidal thickness by age. There was no significant difference in the mean choroidal thickness between locations. The mean subfoveal choroidal thickness was  $368.81 \pm 98 \mu\text{m}$  in subjects in their 20s. The

mean subfoveal choroidal thickness was  $304.19 \pm 98 \mu\text{m}$  in subjects in their 70s. A statistically significant difference was found in choroidal thickness by age ( $P < 0.01$ ).

**Conclusions:** In normal Korean people, the choroidal thickness decreased markedly with advancing age. The decreasing rate of choroidal thickness in Koreans was  $1.4 \mu\text{m}/\text{year}$ . Especially the decreasing rate of choroidal thickness was in rapid decline in men more than women.

**Retina (Surgical)**

**Poster No.: EX1-043**  
**The Internal Limiting Membrane in Diabetic Macular Edema: To Peel or Not to Peel? A Retrospective Review of Anatomical and Visual Outcomes**

*First Author: Wendy Ong Chin FENG*  
*Co-Author(s): Kiat Phang LING, Haslina MOHD ALI, Wan Hazabbah WAN HITAM, Wee Min TEH*

**Purpose:** To evaluate visual function and anatomical outcomes following epiretinal membrane (ERM) and internal limiting membrane (ILM) peeling in diabetic macular edema.

**Methods:** ERM and ILM peeling were performed in 11 eyes for diabetic macular edema with significant ERM. Diabetic eyes with vitreous hemorrhage or tractional retinal detachment affecting the macula were excluded. Preoperative and postoperative visual acuity and macular thickness were assessed. The results were compared with 11 consecutive patients with diabetic macular edema who underwent intravitreal ranibizumab for at least 3 monthly injections.

**Results:** In the ILM peel group, all 11 eyes achieved anatomical improvement as measured by optical coherence tomography (OCT). The mean central foveal thickness decreased from  $465 \mu\text{m}$  to  $310 \mu\text{m}$  (a reduction of 33.3%). However, the visual outcome was unpredictable. Almost three quarters (72.7%) showed visual improvement, while 1 eye (9.1%) maintained





vision and 2 eyes (18.2%) had poorer vision postoperatively. In the ranibizumab group after a course of at least 3 monthly injections, the mean central foveal thickness decreased from 398  $\mu$ m to 344  $\mu$ m (16.1% reduction). Only 9/11 eyes (81.8%) showed an improvement in the anatomical outcome, while 1 eye (9.1%) each had either static or increased central foveal thickness, respectively. For visual acuity, improvement was seen in only 7/11 eyes (63.6%); 2 eyes (18.2%) had static vision while another 2 eyes had worsening of vision.

**Conclusions:** ILM peeling in diabetic macular edema was found to achieve 100% improvement in anatomical outcome as well as better visual acuity as compared to patients treated with intravitreal ranibizumab injections.

---

**Poster No.: EX1-044**

**A Rare Presentation of Delayed Hypersensitivity to Retrobulbar Lignocaine 2%: A Case Report**

*First Author: Jia Hui LEON*

*Co-Author(s): Nor Ismarudi ISMAIL, Selvaraja P VENGADASALAM*

**Purpose:** To report a rare presentation of delayed hypersensitivity to retrobulbar lignocaine 2% in a patient who underwent vitreoretinal surgery.

**Methods:** Case report.

**Results:** A 54-year-old man, previously exposed to lignocaine during ophthalmic surgery for a right eye retinal detachment 6 months prior, had a second operative procedure for removal of silicone oil along with cataract surgery. Both surgeries were uneventful. Five days postoperatively, he presented with right eye pain, swelling, and redness. Examination showed right eye proptosis, erythema, and chemosis with restriction of extraocular movements. His right eye vision was counting fingers and the intraocular pressure was normal. The cornea was hazy and anterior chamber was clear. Fundus examination showed a clear vitreous and flat retina. The fellow eye was phthisical from a childhood trauma. He was

apyrexial with normal blood investigations. Computed tomography (CT) of the orbit showed proptosis of the right globe with preseptal thickening, intraconal fat streakiness, and enlarged thickened optic nerve. He was initially treated as right orbital cellulitis and empirically started on intravenous rocephine with Vigamox. Subsequently, when there was no improvement, he was started on antihistamines and intravenous methylprednisolone, and later on changed to oral prednisolone with tapering dose for 2 weeks. After treatment, he recovered with no proptosis, erythema, or chemosis. Vision improved to 6/60. Skin prick test later showed allergy to lignocaine.

**Conclusions:** Lignocaine is widely used as a local anesthetic agent in ophthalmology. Although hypersensitivity reactions to local anesthetics are rare, it is necessary to suspect lignocaine hypersensitivity in patients presenting with acute postoperative orbital inflammation.

---

**Poster No.: EX1-045**

**Achondroplasia With Exudative Retinal Detachment**

*First Author: Suganeswari GANESAN*

*Co-Author(s): Muna BHENDE, Sudha GANESH, Lingam GOPAL*

**Purpose:** To report on treatment adopted to resolve exudative retinal detachment in a nonnanophthalmic patient with achondroplasia.

**Methods:** A 32-year-old short-statured man with hypermetropia of 1.50 diopters (D) with no features of nanophthalmos or posterior microphthalmos suffered from unilateral exudative retinal detachment (ERD) in which all other modalities of treatment failed including systemic and local steroid therapy and surgical drainage of subretinal fluid. Ultrasound (USG) revealed a thickened sclera. Partial thickness anterior sclerectomy with a central sclerostomy in 2 inferior quadrants resulted in successful resolution of ERD.

**Results:** The retinal detachment resolved completely in 3 months. No sign of subretinal







fluid was noted on optical coherence tomography at the end of 3 months and vision, which was initially counting fingers (CF) at 3 m, improved to 3/60.

**Conclusions:** Scleral resections are effective in the treatment of exudative retinal detachment in achondroplasia. Careful attention to note the thickened sclera on USG can be very helpful in planning the management. Steroid therapy and surgical drainage of subretinal fluid is not effective. Chronic subretinal fluid over the macula can cause significant reduction in vision.

**Poster No.: EX1-046**  
**Clinical Features and Prognostic Factors Predicting Surgical Outcome in Combined Rhegmatogenous and Tractional Retinal Detachment in Proliferative Diabetic Retinopathy**

*First Author: Jee Yao LOKE*

*Co-Author(s): Haslina ALI, Kiet Phang LING, Wee Min TEH*

**Purpose:** To investigate the clinical features and prognostic factors of combined rhegmatogenous and tractional retinal detachment (combined RD) following vitrectomy in proliferative diabetic retinopathy (PDR).

**Methods:** Retrospective review of medical records of 43 eyes that underwent pars plana vitrectomy for PDR with combined RD in 2015 at Hospital Sultanah Bahiyah Alor Setar. All cases were followed-up for at least 6 months postoperatively.

**Results:** The mean age of patients was  $52.6 \pm 6.4$  years. Preoperative visual acuity worse than or equal to counting fingers was seen in 18 eyes (41.8%). Retinal breaks were identified in 7 eyes (16.3%) preoperatively and in 36 eyes (83.7%) intraoperatively. Thirty-four eyes (79.1%) had a single retinal break. Twenty-five eyes (58.1%) had more than 2 quadrants RD. Vitreous hemorrhage was seen in 16 eyes (37.2%) while 27 eyes (62.8%) showed predominant fibrous tissue. Silicone oil was used in 39 eyes (90.7%). Snellen visual acuity improved in 26 eyes

(60.5%), was unchanged in 11 eyes (25.6%), and worsened in 6 eyes (14.0%). Postoperative vision of 3/60 or better was found in 27 eyes (62.8%). Forty eyes (93.0%) achieved retinal reattachment for at least 6 months after primary surgery. Poor visual outcome was significantly correlated with poor preoperative visual acuity ( $r = 0.52, P < 0.001$ ), more than 2 quadrants of RD ( $r = 0.58, P < 0.001$ ), and postoperative retinal atrophy ( $r = 0.56, P < 0.001$ ).

**Conclusions:** Vitrectomy improved or stabilized vision in proliferative diabetic retinopathy with combined retinal detachment. Preoperative visual acuity and extent of RD are features that best predict visual prognosis.

**Poster No.: EX1-047**  
**Clinical Outcomes After Combined Pars Plana Vitrectomy and Pars Plana Tube Placement of Aurolab Aqueous Drainage Implant in Patients With Refractory Glaucoma**

*First Author: YC Venu Gopal REDDY*

*Co-Author(s): Syed MOHIDEEN, Anuj SHARMA, Adheesh SHETTY*

**Purpose:** To describe the characteristics and outcomes of combined pars plana vitrectomy (PPV) and pars plana tube placement of Aurolab aqueous drainage implant (AADI) in patients with refractory glaucoma.

**Methods:** Twenty-eight eyes of 28 patients were included in the study. Preoperative slit lamp evaluation, gonioscopy, and intraocular pressure (IOP) measurement by Goldmann applanation tonometry was done. A complete pars plana vitrectomy including base dissection was carried out. AADI implant was placed in the inferonasal quadrant along with insertion of the tube into the vitreous cavity via pars plana. Postoperatively the IOP was measured at 1 week, 1 month, and 3 months.

**Results:** Mean age of the patients was  $54.03 \pm 16.48$  years with 60.71% being male. Most common ocular cause for refractory glaucoma was neovascular glaucoma secondary to central retinal vein occlusion (21.43%) and posttraumatic glaucoma (21.43%). Mean





preoperative IOP was recorded as  $38.19 \pm 11.3$  mm Hg. A previous failed filtration surgery had been done in 10 eyes (35.71%). Mean IOP at 1 week, 1 month, and 3 months was  $22.74 \pm 12.88$  mm Hg,  $15.81 \pm 9.81$  mm Hg, and  $14.50 \pm 8.91$  mm Hg, respectively. Nine eyes (32.14%) were free of any further topical therapy at the end of the follow-up period while 12 eyes (42.86%) required a single drug to control IOP. Complications were noted in 4 eyes (14.29%) during the follow-up period with conjunctival erosion with tube exposure (2 eyes) being the most common.

**Conclusions:** AADI implantation in the vitreous cavity is a safe, efficacious, and cost-effective method for controlling IOP in cases with refractory glaucoma.

---

**Poster No.: EX1-048**

**Clinical Outcomes of the Surgical Management of Anterior Chamber Migration of a Dexamethasone Implant (Ozurdex)**

*First Author: Min KIM*

*Co-Author(s): Eunyoung CHOI, Hyungseung KANG, Sung Chul LEE*

**Purpose:** To describe the clinical course and individualized management approaches of patients with migration of a dexamethasone implant into the anterior chamber.

**Methods:** A retrospective review of 924 intravitreal dexamethasone injections to identify patients with episodes of anterior chamber migration.

**Results:** Anterior migration of the implant occurred in 4 eyes of 4 patients (0.43%). All 4 eyes were pseudophakic: 1 eye with a posterior chamber intraocular lens (IOL) in the capsular bag but in a postlaser posterior capsulotomy state, 2 eyes with a sulcus IOL, and 1 eye with an iris-fixated retropupillary IOL. The time interval to implant migration ranged from 2–6 weeks. Of the 4 eyes with corneal edema, only 1 eye required a corneal transplantation, although it was unclear whether the implant migration was the direct cause of the corneal decompensation because the patient had a

history of bullous keratopathy resulting from an extended history of uveitis. All patients underwent surgical intervention: 2 patients with a repositioning procedure and the other 2 patients with removal due to repeated episodes, although surgical removal was not always necessary to reverse the corneal complications.

**Conclusions:** In our study, not all patients required surgical removal of the implants. Repositioning the implant back into the vitreous cavity may be considered as an option in cases involving the first episode with no significant corneal endothelial decompensation. Considering potential anterior segment complications and the loss of drug effectiveness together, an individualized approach is recommended to obtain the best treatment outcomes and to minimize the risk of corneal complications.

---

**Poster No.: EX1-049**

**Comparative Analysis of Large Macular Hole Surgeries Using Internal Limiting Membrane Sheet: Insertion Technique Versus Inversion Technique**

*First Author: Jongho PARK*

**Purpose:** To determine whether the insertion of internal limiting membrane (ILM) sheets inside the hole is as effective as inverted ILM flap technique for the initial treatment in eyes with idiopathic large macular hole (MH).

**Methods:** This was a retrospective, nonrandomized, comparative clinical study. We reviewed 37 eyes with idiopathic MH (minimum hole diameter > 500  $\mu$ m). The patients were divided into vitrectomy and insertion of ILM sheet inside the hole (insertion group) and covering the hole with inverted ILM sheet (inversion group). The hole closure rate, postoperative best-corrected visual acuity (BCVA), and optical coherence tomographic findings including foveal contour, integrity of ellipsoid zone (EZ), and external limiting membrane (ELM) at 6 months were analyzed.

**Results:** Eleven eyes were in the insertion group



and 26 eyes in the inverted flap group. Hole closure was achieved in all eyes of both groups. Mean BCVA (logarithm of the minimum angle of resolution, logMAR) improved significantly in both group ( $P = 0.010$  and  $0.000$ , respectively), which was better in the inversion group ( $0.526$  vs  $0.772$ ,  $P = 0.019$ ). Foveal depigmentation was more common in the insertion group than in the inversion group ( $81.8\%$  vs  $7.7\%$ ,  $P = 0.000$ ). In the fovea, complete recovery of the EZ and ELM was found in 18 eyes of the inversion group but not in those belonging to the insertion group ( $P = 0.000$ ).

**Conclusions:** The insertion of ILM sheets inside the hole was as effective as the inverted ILM flap technique in the closure of large MH. However, postoperative BCVA was better in eyes receiving inverted ILM flap, which was in accordance with the greater recovery of photoreceptor layers.

**Poster No.: EX1-050**  
**Comparison of Clinical Outcomes of Vitrectomy With Silicone Oil Tamponade in Eyes With Proliferative Diabetic Retinopathy According to the Timing of Internal Limiting Membrane Peeling**

*First Author: Duck Jin HWANG*  
*Co-Author(s): Ji In PARK*

**Purpose:** To study whether the timing of internal limiting membrane (ILM) peeling affects clinical outcomes of vitrectomy with silicone oil tamponade in eyes with proliferative diabetic retinopathy (PDR).

**Methods:** Forty-two eyes of 36 patients underwent vitrectomy with silicone oil tamponade and stepwise silicone oil removal for PDR and tractional retinal detachment. In group 1 (26 eyes of 24 patients), ILM peeling was performed just before silicone oil injection, while in group 2 (16 eyes of 12 patients), ILM peeling was performed after silicone oil removal. Visual acuity (logarithm of the minimum angle of resolution, logMAR) and macular configuration between the 2 groups were compared.

**Results:** The subjects were followed up for  $14.06 \pm 8.01$  months on average after silicone oil removal. At the final visit, no significant difference was found between the corrected visual acuity ( $-0.63 \pm 0.73$  vs  $-0.69 \pm 0.90$ ,  $P = 0.851$ ), central foveal thickness ( $302.36 \pm 47.37 \mu\text{m}$  vs  $302.00 \pm 50.18 \mu\text{m}$ ,  $P = 0.986$ ), and total macular volume ( $8.69 \pm 0.71 \text{ mm}^3$  vs  $8.66 \pm 0.89 \text{ mm}^3$ ,  $P = 0.913$ ) of the 2 groups. In detailed analyses of macular configuration, retinal nerve fiber layer or photoreceptor layer presented no significant differences in terms of their thickness and volume.

**Conclusions:** The timing of ILM peeling in vitrectomy with silicone oil tamponade does not affect the visual recovery or macular configuration of eyes with PDR.

**Poster No.: EX1-051**  
**Displacement of the Fovea After Macular Hole Surgery Assessed Using En Face Optical Coherence Tomography Images**

*First Author: Jieun LEE*  
*Co-Author(s): Hyunwoong KIM, Jae Jung LEE, Seung Min LEE, Keun Heung PARK*

**Purpose:** To investigate the postoperative displacement of the foveal retinal layers after surgical closure of macular hole.

**Methods:** Medical records of patients who underwent macular hole surgery were reviewed retrospectively. En face optical coherence tomography images were exported at the level of the choroid, ellipsoid zone (EZ), and inner plexiform layer (IPL) at baseline, 1, 3, and 6 months. The foveal center of the EZ and IPL was marked in the choroid en face image. The choroidal images were overlapped to match the vasculature in each patient, and the postoperative displacement of the foveal center was compared to baseline.

**Results:** The study included 26 patients. The center of the EZ and IPL was displaced significantly towards the disc during the first 3 months. The mean horizontal displacement at 1, 3, and 6 months was  $52.7$ ,  $112.5$ , and  $115.4 \mu\text{m}$ , respectively, for the EZ and  $73.8$ ,  $116.3$ ,



and 135.1  $\mu\text{m}$  for the IPL. The location of the foveal center was not significantly different between the EZ and the IPL.

**Conclusions:** Concurrent displacement of the photoreceptor and inner retinal layers suggests that the outer retina would have an important role in metamorphopsia related to macular deformation.

---

**Poster No.: EX1-052**

**Effect of Duration of Macular Detachment on Visual Acuity After Pars Plana Vitrectomy for Primary Macula-Off Rhegmatogenous Retinal Detachments**

*First Author: Hyunwoong KIM*

*Co-Author(s): In Young CHUNG, Dong Geun KIM, Kun Hyung KIM, Jieun LEE*

**Purpose:** To evaluate the effect of duration of macular detachment (DMD) on recovery of visual acuity in primary macula-off rhegmatogenous retinal detachment after pars plana vitrectomy.

**Methods:** Retrospective observational case series. In 57 patients who underwent pars plana vitrectomy for primary macula-off rhegmatogenous retinal detachment, medical records of 1-year follow-up after surgery were reviewed. The macular detachment was confirmed by spectral domain optical coherence tomography (SD-OCT). DMD was defined as the duration from onset of the central visual acuity decrease to surgical intervention. The improvement of postoperative best corrected visual acuity (BCVA) at 3, 6, and 12 months based on different DMD was analyzed.

**Results:** The BCVA at 3, 6, and 12 months after surgery was significantly higher in patients who underwent surgery within 3 days compared with those who underwent surgery more than 4 days after macular detachment ( $P = 0.014, 0.009,$  and  $0.017,$  respectively). The BCVA at 6 and 12 months postoperatively was significantly higher in patients who underwent surgery within 7 days than in those who underwent surgery more than 8 days after macular detachment ( $P = 0.019$  and  $0.009,$  respectively). When DMD

was divided into 3 periods (group 1: 0~3 days; group 2: 4~7 days; group 3: more than 8 days) there was no significant difference in visual acuity between groups 1 and 2.

**Conclusions:** Pars plana vitrectomy performed within 7 days of DMD demonstrated better functional prognosis in patients with primary macula-off rhegmatogenous retinal detachment.

---

**Poster No.: EX1-053**

**Effect of Panretinal Laser Photocoagulation on Retinal Nerve Fiber Layer and Macular Thickness Evaluated With Optical Coherence Tomography**

*First Author: Gokhan KAYA*

**Purpose:** To evaluate the effects of the retinal laser photocoagulation (PRP) starting from the upper or lower half of the retinal layer with optical coherence tomography (OCT).

**Methods:** Fifty eyes of 25 patients were included in the study. OCT was used to measure the macular and retinal nerve fiber layer (RNFL) thickness starting at week 2, 3 months, and 6 months after laser.

**Results:** The average age was 59 and the average HbA1c levels were 9.64. There were no statistically significant difference in macular thickness. There was no statistically significant difference in the group in which the PRP started from the lower part of the retina ( $P < 0.05$ ). There was a statistically significant difference in the group in which PRP started from the upper part of the retina ( $P < 0.05$ ).

**Conclusions:** RNFL thickness increased in the 6 months after PRP. Furthermore, the macular thickness showed no significant difference throughout the 6 months of follow-up.



Poster No.: EX1-054

**Efficacy of Intravitreal Injection of Bevacizumab in Vitrectomy for Patients With Proliferative Vitreoretinopathy Retinal Detachment: A Meta-Analysis of Prospective Studies**

First Author: Xinyu **ZHAO**

**Purpose:** To evaluate the effect of intravitreal injection of bevacizumab in vitrectomy for patients with proliferative vitreoretinopathy (PVR)-related retinal detachment (RD).

**Methods:** PubMed, Embase, and the Cochrane Central Register of Controlled Trials were searched from their earliest entries through October 2016 to identify the studies that had evaluated the effects of intravitreal injection of bevacizumab in vitrectomy for eyes with PVR-related RD. The PRISMA guidelines were followed. The relevant data were analyzed using StataSE 12.0 software. The weighted mean difference (WMD), relative risk (RR), and their 95% confidence intervals (95% CIs) were used to assess the strength of the association.

**Results:** Our search yielded 133 records, of which 3 studies that had examined the effects of intravitreal injection of bevacizumab (120 eyes with PVR-related RD) were included for review and analysis. Our meta-analyses showed that neither the best corrected visual acuity (BCVA) nor retinal redetachment rate showed any clinically or statistically important difference between the nonbevacizumab and bevacizumab groups ( $P > 0.05$ ). In addition, bevacizumab did not influence the interval between vitrectomy and retinal redetachment ( $P > 0.05$ ).

**Conclusions:** Based on the available evidence, intravitreal injection of bevacizumab in vitrectomy for patients with PVR-related RD did not decrease the retinal redetachment rate or improve visual acuity. Better-designed studies with larger sample sizes and longer follow-up are required to reach valid conclusions regarding benefits and harms. Moreover, evaluation of anti-VEGF therapy on surgical outcomes in eyes with milder subtypes of PVR or no PVR, but deemed at high risk of PVR, may

be worthy of future consideration.

Poster No.: EX1-055

**Intraoperative Challenges During Vitrectomy in Patients With SFIOL In Situ: A Case Series**

First Author: Prateek **KAKKAR**

Co-Author(s): Vineet **MUTHA**, R **KARTHIKEYA**, Priyanka **RAMESH**, Raghav **RAVANI**

**Purpose:** To report the surgical challenges during vitreoretinal surgery in patients with scleral-fixated intraocular lens (SFIOL) and provide suggestions to overcome these difficulties.

**Methods:** Four eyes of 4 patients who presented to our tertiary care hospital with retinal pathology requiring vitreoretinal surgical intervention were evaluated. Three patients suffered from retinal detachment requiring vitreoretinal surgery with silicone oil injection. One patient suffered from endophthalmitis requiring pars plana vitrectomy with silicone oil injection. All the patients underwent 23-gauge microincision vitrectomy surgery (MIVS) pars plana vitrectomy and the surgical challenges faced during these surgeries were assessed.

**Results:** The main difficulties faced during vitreoretinal surgery were dislocation of the SFIOL in 1 patient, difficulty in making ports and visible displacement of IOL while making the ports, difficulty in visualization due to edge effect, and entry of air in the anterior chamber during air-fluid exchange hampering visualization in all cases. Displacement of the IOL haptic was noted in 1 case that was repositioned into the scleral tunnel. Complete posterior dislocation of the IOL occurred in 1 case which had to be explanted subsequently. Suggested modifications during surgical intervention to avoid these difficulties include making the ports away from the haptics, minimal manipulation of the instruments, filling viscoelastic in the anterior chamber prior to air-fluid exchange, and formation of inferior Ando's peripheral iridectomy to prevent pupillary block.

**Conclusions:** Presence of SFIOL poses certain



unique surgical challenges during vitreoretinal surgeries. Anticipation of these problems and surgical expertise is essential to avoid intraoperative complications and ensure good surgical outcomes.

Poster No.: EX1-056

### Long-Term Visual Outcomes of Treatment of Massive Submacular Hemorrhage Secondary to Polypoidal Choroidal Vasculopathy

First Author: Min **KIM**

Co-Author(s): Eunyong **CHOI**, Hyungoo **KANG**, Sung Chul **LEE**

**Purpose:** To compare the long-term visual outcome of 3 different treatment strategies consisting of intravitreal bevacizumab (IVB) monotherapy, a combination of IVB and pneumatic displacement (PD), or a combination of IVB and trans pars plana vitrectomy (TPPV) for massive submacular hemorrhage (SMH) secondary to polypoidal choroidal vasculopathy (PCV).

**Methods:** Retrospective comparative case series of 48 eyes from 47 Korean patients with massive SMH secondary to PCV.

**Results:** Twenty-two eyes were treated with IVB monotherapy, 14 with combined IVB and PD, and 12 with combined IVB and TPPV. There was a significant difference of the mean best corrected visual acuity (BCVA) after initial treatment only at month 1 ( $P = 0.005$ ). The changes in mean BCVA over time revealed no significance in the resulting final BCVA ( $P = 0.062$ ), which was 20/155 [logarithm of the minimum angle of resolution (logMAR)  $0.89 \pm 0.64$ ] for IVB monotherapy, 20/174 (logMAR  $0.94 \pm 1.04$ ) for combined IVB and PD, and 20/195 (logMAR  $0.99 \pm 0.90$ ) for combined IVB and TPPV. Long-term BCVAs with sustained improvement of 3 Snellen lines or better compared to the initial were found in 7 (31.82%) IVB monotherapy, 10 (71.43%) combined IVB and PD, and 7 (58.33%) combined IVB and TPPV treated eyes ( $P = 0.043$ ). Massive SMH recurrence was observed in 2 eyes after IVB monotherapy and 1 eye after IVB with PD ( $P = 0.786$ ).

**Conclusions:** Regarding the final BCVA at 24 months, IVB monotherapy was as effective as the combination therapies of IVB with either PD or TPPV for treating PCV with massive SMH, but IVB combined with PD was superior in achieving sustained improvement of over 3 Snellen lines of BCVA.

Poster No.: EX1-057

### Management of Persistent Vitreous Hemorrhage After Pars Plana Vitrectomy With Nd:YAG Laser Capsulotomy in Pseudophakic Patients: A Novel Technique

First Author: Adarsh **NAIK**

Co-Author(s): Anant **BHOSALE**, Karan **KUMARSWAMY**, Venkatapathy **NARENDRAN**, VR **SARAVANAN**

**Purpose:** Patients treated for advanced diabetic retinopathy with vitrectomy without tamponade may have persistent dispersed vitreous hemorrhage. Persistent hemorrhage after vitrectomy is a troublesome situation for the patient and surgeon. We present a novel technique to tackle this situation.

**Methods:** A novel technique of Nd:YAG capsulotomy in 10 pseudophakic patients having persistent dispersed vitreous hemorrhage, who were previously operated for proliferative diabetic retinopathy. After primary vitrectomy these patients had dispersed vitreous hemorrhage until 1 month postoperatively. Nd:YAG laser (wavelength 1064 nm) was used to create 3 openings in the aphakic area of the posterior capsule around the optic of the intraocular lens. Patients showed decrease in vitreous hemorrhage as it drained out through the trabecular meshwork. This is based on the fact that dispersed hemorrhage clears earlier in aphakics than phakics. Patients were given steroid and antiglaucoma medications after laser and close follow-up for intraocular pressure monitoring was done.

**Results:** Vitreous hemorrhage cleared in all 10 patients. Additional laser photocoagulation done to prevent further rebleeding.



**Conclusions:** Nd:YAG laser capsulotomy after vitrectomy is a simple yet novel noninvasive, safe, and effective technique to clear postoperative vitreous hemorrhage in pseudophakic eyes with intact posterior capsule without the patient undergoing additional surgery.

Poster No.: EX1-058

**Optical Coherence Tomography-Angiography Findings After Photodynamic Therapy in Polypoidal Choroidal Vasculopathy**

First Author: Hun Gu **CHOO**

Co-Author(s): Hee Weon **KIM**, Soon Hyun **KIM**, Oh Woong **KWON**, Hyun-Sub **OH**, Yong Sung **YOU**

**Purpose:** To evaluate the change of optical coherence tomography-angiography (OCT-A) findings after photodynamic therapy (PDT) in polypoidal choroidal vasculopathy (PCV) patients.

**Methods:** We retrospectively analyzed the records of 3 patients (3 eyes) diagnosed with PCV. We measured the flow area of polyps and branching vascular networks (BVNs) in OCT-A images and examined the change of flow area after PDT.

**Results:** Polyps were more clearly observed in indocyanine green (ICG) angiography than in OCT-A images, but BVNs were more clearly observed in OCT-A images than ICG angiography. In patient A, the flow area of BVN, which was  $0.717 \text{ mm}^2$  before PDT treatment, decreased to  $0.636$  and  $0.516 \text{ mm}^2$  at 1 month and 2 months after PDT and increased to  $0.754 \text{ mm}^2$  at 4 months. In patient B, the flow area of BVN, which was  $0.588 \text{ mm}^2$  before PDT treatment, decreased to  $0.298$  and  $0.292 \text{ mm}^2$  at 1 month and 2 months after PDT and increased to  $0.393 \text{ mm}^2$  at 4 months. In patient C, the flow area of BVN, which was  $1.213 \text{ mm}^2$  before PDT treatment, decreased to  $0.608 \text{ mm}^2$  at 1 month after PDT and increased to  $1.482 \text{ mm}^2$  at 3 months.

**Conclusions:** OCT-A was able to demonstrate flow changes of BVN in PCV patients who received PDT and quantitative analysis of

area was possible. Therefore, OCT-A can be considered as a noninvasive and useful monitoring device in response to PDT treatment and follow-up in PCV patients.

Poster No.: EX1-059

**Outcomes of Diabetic Vitrectomy Surgery at Hospital Sultanah Bahiyah, Kedah, Malaysia**

First Author: Abdul Aziz **AHMAD MARWAN**

Co-Author(s): Kiet Phang **LING**, Haslina **MOHD ALI**, Wei Wei **LEE**

**Purpose:** To retrospectively review the outcomes of diabetic vitrectomy for advanced diabetic retinopathy and to identify the type of vitrectomy that may influence the visual outcomes and decisions for the surgery.

**Methods:** One hundred ninety-three eyes of 175 patients undergoing vitrectomy for diabetic retinopathy in the Ophthalmology Department of Hospital Sultanah Bahiyah in 2015 were included in this study.

**Results:** The mean age of diabetic vitrectomy was  $58.6 \pm 18.0$  years. The main indication for pars plana vitrectomy (PPV) in our audit was tractional retinal detachment (TRD) affecting the macula (30.0%,  $n = 58$ ) followed by combined tractional rhegmatogenous retinal detachment (TRRD) (25.9%,  $n = 50$ ), persistent vitreous hemorrhage (VH) (15.5%,  $n = 30$ ), epiretinal membrane (ERM) (9.3%,  $n = 18$ ), TRD threatening the macula (8.3%,  $n = 16$ ), postoperative retinal detachment (6.2%,  $n = 12$ ), and postoperative VH (4.7%,  $n = 9$ ). Almost one third of the eyes required intraoperative desegmentation or delamination (65.8%,  $n = 127$ ). Silicone oil 5000 cs (35.2,  $n = 68$ ) was the most commonly used intraocular tamponade agent, follow by air (18.1%,  $n = 35$ ), C3F8 (10.9%,  $n = 21$ ), and heavy silicone oil (4.1%,  $n = 8$ ). In addition, 31.6% of the cases ( $n = 61$ ) did not require any tamponade. The visual function from severe impairment (6/60 or worse) had reversed to moderate impairment (6/36 or better) from 54.0% ( $n = 88$ ) before surgery to 46.0% ( $n = 75$ ) 6 months after surgery. The visual acuity improved in 70.0% eyes ( $n = 114$ ), remained unchanged in 15.3% ( $n = 25$ ), and



worsened in 14.7% eyes (n = 24).

**Conclusions:** Diabetic vitrectomy improved or stabilized vision in 85.3% of cases. Diabetic vitrectomy in Hospital Sultanah Bahiyah has an appreciable visual outcome for all type of surgical indications.

**Poster No.:** EX1-061

### **Primary Vitrectomy With 360-Degree Laser as Surgery for Rhegmatogenous Retinal Detachment**

*First Author:* Shamik **MOKADAM**

*Co-Author(s):* Ian **CONSTABLE**, Mandar **JOGLEKAR**, Vignesh **RAJA**, Smita **UPADHYE**

**Purpose:** To evaluate the efficacy of 360-degree endolaser treatment in eyes undergoing primary vitrectomy surgery for rhegmatogenous retinal detachment (RRD).

**Methods:** A retrospective case study of 166 case records of patients who underwent primary vitrectomy surgery as part of treatment for RRD from November 20, 2014 to December 31, 2016 was done. All the procedures were done by a single surgeon. Under general/local anesthetic, 25G vitrectomy, endodrainage, fluid air exchange, 360-degree endolaser covering the primary break and draining retinotomy, and 25% sulphur hexafluoride gas injection were performed. The outcomes evaluated were the retinal reattachments and additional procedures needed in case of complications.

**Results:** All the surgeries were uneventful; 152 out of the 166 eyes (91.6%) had a completely attached retina with 360-degree lasered retina at 6 months' follow-up and a mean best corrected visual acuity (BCVA) of 6/12. Of the remaining 14 eyes, 3 had a peripheral redetachment and 5 had complete redetachments and needed a second procedure in the form of scleral buckling, vitrectomy, removal of membranes/proliferative vitreoretinopathy, endolaser, and silicone oil injection. The remaining 6 had dense epiretinal membranes (ERM) at the macula needing resurgery in the form of vitrectomy and ERM peeling.

**Conclusions:** Our case study shows that 360-degree laser treatment as part of primary vitrectomy surgery for RRD reduces the redetachment rates and thus obviates the need for a second procedure.

**Poster No.:** EX1-062

### **Subretinal Exudation After Photodynamic Therapy: A Retrospective Study**

*First Author:* Ratnesh **RANJAN**

*Co-Author(s):* George **MANAYATH**, Venkatapathy **NARENDRAN**, Swapnil **VIDHATE**

**Purpose:** To share our experience with cases of serofibrinous exudative complications of photodynamic therapy (PDT) and their long-term outcomes.

**Methods:** Observational case series with retrospective review of all cases developing subretinal exudation within a week after PDT.

**Results:** Post-PDT exudation was noted in 8 eyes of 8 patients, including polypoidal choriocapillopathy (PCV) [4 eyes], PCV with coexisting central serous chorioretinopathy (CSC) [2 eyes], and chronic CSC and occult choroidal neovascular membrane (CNVM) [1 eye each], with a mean age of  $70.25 \pm 6.65$  years. Low-fluence and standard-fluence PDT were done in 7 and 1 eyes, respectively. Six eyes developed exudation after the first sitting of PDT and 2 eyes after the second sitting. Pretreatment mean best corrected visual acuity (BCVA) was logarithm of the minimum angle of resolution (logMAR)  $0.29 \pm 0.21$ , and mean central macular thickness (CMT) was  $228.1 \pm 71.8 \mu\text{m}$ . Post-PDT exudation was noted between 2 to 7 days with mean BCVA reduced to logMAR  $0.91 \pm 0.37$  ( $P = 0.002$ ), and mean CMT increased to  $481.4 \pm 154.8 \mu\text{m}$  ( $P = 0.003$ ). Seven eyes received intravitreal anti-vascular endothelial growth factor (anti-VEGF) within 2 days of PDT, regained baseline tomographic status at a mean interval of  $4.6 \pm 1.2$  weeks, and remained stable for a mean duration of  $13.3 \pm 8.4$  weeks. During final follow-up ( $64.8 \pm 43.2$  weeks), mean BCVA was logMAR  $0.49 \pm 0.28$ , and mean CMT was  $153.6 \pm 40.0 \mu\text{m}$  with only 50% of eyes stable with or without





interventions.

**Conclusions:** Post-PDT subretinal exudation is a transient complication with higher incidence in PCV than in CNVM or chronic CSC. It can occur after either standard- or low-fluence PDT, after the first or repeated sitting of PDT, and shows good response to intravitreal anti-VEGF.

Poster No.: EX1-064

**Surgical Outcomes of Transconjunctival 25-Gauge Plus Pars Plana Vitrectomy for Lens Fragments Dropped Into the Vitreous Cavity During Cataract Surgery**

First Author: Seungwoo LEE

**Purpose:** To evaluate the result, efficiency, and stability of transconjunctival 25-gauge plus pars plana vitrectomy (PPV) for lens fragments dropped into the vitreous cavity during cataract surgery.

**Methods:** A retrospective analysis of 24 eyes of 24 patients who underwent transconjunctival 25-gauge plus PPV for lens fragments dropped into the vitreous cavity during cataract surgery between January 2014 and October 2016 with a minimum of 6-month follow-up was performed, and the size of dropped lens fragments were categorized into 4 stages (1 = <25%; 2 = 26–50%; 3 = 51–75%; 4 = >75%). The main outcome measures were postoperative visual acuity, postoperative intraocular pressure, and postoperative complications.

**Results:** The study included 17 men and 7 women. The mean age of the patients was 68.6 years. The mean interval between cataract surgery and PPV was  $0.58 \pm 1.1$  days, and all PPVs were performed within 4 days after cataract surgery. The mean best-corrected visual acuity (logarithm of the minimum angle of resolution, logMAR) was  $1.42 \pm 0.78$  in the preoperative state and improved significantly to  $0.21 \pm 0.15$  in the postoperative state ( $P = 0.00$ ). The size of the lens and mean operation time were found to have a positive correlation ( $R^2 = 0.86$ ,  $P < 0.01$ ). Postoperative cystoid macular edema occurred in 3 eyes but improved with conservative treatment.

**Conclusions:** Transconjunctival 25-gauge plus PPV for lens fragments dropped into the vitreous cavity during cataract surgery can be a safe and effective solution for dropped lens fragments of modest size.

Poster No.: EX1-065

**Sutureless Scleral Belt Loop: A New Experience in Managing Primary Rhegmatogenous Retinal Detachment in Alor Setar, Kedah**

First Author: Intan MOHD RADZUAN

Co-Author(s): Kiet Phang LING, Haslina MOHD ALI, Wee Min TEH

**Purpose:** To compare the outcome of sutureless scleral belt loop (SBL) and vitrectomy versus other surgical methods used in the management of primary rhegmatogenous retinal detachment (RRD).

**Methods:** Retrospective analysis of patients who underwent surgery for primary RRD from January to June 2017 in Hospital Sultanah Bahiyah, Alor Setar, Kedah. Primary outcome measure was reattachment with a single surgery at 6 weeks postoperatively.

**Results:** Forty eyes from 40 patients were included in the study, with 14 (35%) females and 26 (65%) males. Mean age was 42.9 (range, 8–76 years). Ten eyes (25%) underwent SBL with vitrectomy, 5 eyes (12.5%) underwent vitrectomy combined with conventional scleral buckle (SB), 19 eyes (47.5%) had pars plana vitrectomy only, while the remaining 6 eyes (15.0%) had scleral buckle alone. The retina was reattached in 100% of patients who underwent vitrectomy with conventional scleral buckle and those with scleral buckle alone. Those who underwent only pars plana vitrectomy had a reattachment rate of 89.5%, while the group of subjects who underwent vitrectomy with sutureless scleral belt loop had an 80% reattachment rate at 6 weeks postoperatively. Proliferative vitreoretinopathy was implicated in all cases of redetachment encountered, regardless of the procedures done.

**Conclusions:** Sutureless scleral belt loop



with 40-band is a viable alternative to the conventional sutured scleral buckle as a supplement to pars plana vitrectomy for patients with RRD. It is technically easier to master, yet achieves comparable anatomical outcomes in the majority of patients.

Poster No.: EX1-066

### The Effect of Different Prophylactic Laser Retinopexy on Inferior Rhegmatogenous Retinal Redetachment After Silicone Oil Removal

First Author: Yan **SHI**

**Purpose:** To investigate the effect of prophylactic 180-degree peripheral and 360-degree laser retinopexy on inferior rhegmatogenous retinal redetachment after silicone oil removal.

**Methods:** The data of 64 vitreoretinal patients after silicone oil removal were retrospectively analyzed. Twenty-two patients in the 180-degree laser retinopexy group (group A) were given prophylactic 180-degree peripheral retinopexy before silicone oil removal; 23 patients in the 360-degree laser retinopexy group (group B) were given 360-degree peripheral retinopexy before silicone oil removal while 19 patients in the control group (group C) were not.

**Results:** The duration of silicone oil tamponade was 8-56 weeks, averaging  $16.09 \pm 7.29$  weeks. Seven cases of retinal redetachment were recorded after silicone oil removal, including 1 case in group A (4.55%), 1 case in group B (4.35%), and 5 cases in group C (26.32%). The difference between group A and group C was statistically significant ( $P < 0.05$ ) and the same with group B and group C. There was no statistical difference between group A and group B ( $P > 0.05$ ). Among these 7 patients with retinal redetachment, the main causes were omission of small retinal breaks or reopening of original hole and the development of proliferative vitreoretinopathy (PVR). Six cases of redetachment resulted from the omission of small retinal breaks closed by

silicone oil temporarily or the reopening of primary retinal breaks because of insufficient photocoagulation during the operation; 1 case resulted from the formation of new breaks from PVR.

**Conclusions:** Prophylactic laser retinopexy is associated with a decrease in the incidence of retinal redetachment after removal of silicone oil. There is no significant correlation of different degrees of prophylactic laser retinopexy on inferior rhegmatogenous retinal redetachment after silicone oil removal.

Poster No.: EX1-067

### The Effect of Internal Limiting Membrane Peeling in Combined Hamartoma and Idiopathic Epiretinal Membrane

First Author: Jung Min **PARK**

**Purpose:** This study was designed to evaluate the effect of internal limiting membrane (ILM) peeling in the surgical management of combined hamartoma of the retina and retinal pigment epithelium and idiopathic epiretinal membrane (ERM).

**Methods:** The records of 11 patients (11 eyes) with ERM and combined hamartoma of the retina and retinal pigment epithelium and 22 patients (22 eyes) with idiopathic ERM who had undergone pars plana vitrectomy with removal of the ERM were retrospectively reviewed. The patients were divided into 4 groups: eyes without (6 eyes) or with (5 eyes) ILM peeling in ERM and combined hamartoma of the retina and retinal pigment epithelium and eyes without (12 eyes) or with (10 eyes) ILM peeling in idiopathic ERM. Anatomical outcomes, functional outcomes, complications, and recurrences were compared between the eyes without and with ILM peeling. Anatomical outcomes included the central retinal thickness (CRT) and subfoveal choroidal thickness (SFCT) on optical coherence tomography (OCT). Functional outcomes included the change in best-corrected visual acuity (BCVA).

**Results:** CRT and SFCT decreased and postoperative BCVA improved in without



and with ILM peeling in ERM and combined hamartoma and idiopathic ERM. However, there were no statistically significant differences in CRT, SFCT, and BCVA between without and with ILM peeling in ERM and combined hamartoma and idiopathic ERM. There was no complicated or recurred case in all 4 groups.

**Conclusions:** The additional ILM peeling in patients with ERM and combined hamartoma of the retina and retinal pigment epithelium and idiopathic ERM does not affect the postoperative results in CRT, SFCT, and visual acuity.

---

Poster No.: EX1-068

### The Epidemiology of Motor Vehicle Accident Eye-Related Injuries at UMMC

First Author: Maftuhim **ADDENAN**

Co-Author(s): Han Nie **CH'NG**, Tengku Ain **KAMALDEN**

**Purpose:** To report the demographics, characteristics, and visual outcome of ocular and orbital-related injuries secondary to motor vehicle accidents (MVA).

**Methods:** This was a retrospective case series of ocular and orbital injuries secondary to MVAs at the University of Malaya Medical Centre from 2012 to 2016. Demographic data, type of injuries, ocular trauma score (OTS), alcohol or drug usage, and visual outcome were analyzed.

**Results:** Out of a total of 261 cases reviewed, only 111 patients (42.5%) sustained MVA-associated ocular or orbital trauma. There was a total of 128 affected eyes, where 17 patients had bilateral involvement. The majority of patients (84.7%) were male while only 17 (15.3%) were female. The average age was 32.9 years old (range, 2-80 years). Most patients sustained closed globe injury (CGI, 91.9%) while only 9 patients (8.1%) had open globe injury (OGI). The main cause of OGIs was broken glass fragments from the front shield (33.3%). Out of 128 affected eyes, 57.7% had orbital fracture, and 72.1% sustained contusion. Alcohol consumption was recorded in 14 patients (12.6%). Most of the MVAs occurred

on Mondays (18%). Only 37 patients (33.3%) returned for follow-up for at least 6 months after trauma. Out of these, most patients had vision better than 6/60.

**Conclusions:** Motor vehicle accidents are an important contributor to ocular or orbital trauma at our center. Most patients reported a moderate visual outcome at 6 months.

---

Poster No.: EX1-071

### Factors Affecting Visual and Anatomical Success in Vitrectomy for Advanced Diabetic Eye Disease: A Single-Center Study

First Author: Katherine **SENG**

Co-Author(s): Bethel **LIVINGSTONE**, Dheveya **SINNAYA**

**Purpose:** Proliferative diabetic retinopathy is one of the microvascular complications of diabetes and is the leading cause of visual impairment in the diabetic population. Pars plana vitrectomy is the standard of care in advanced diabetic eye disease (ADED). The objective of this study was to assess the visual and anatomical outcome following vitrectomy for ADED in Hospital Tuanku Ja'afar, Seremban, Malaysia and to identify factors associated with poorer visual outcome.

**Methods:** This was an observational, retrospective, cross-sectional study of vitrectomies performed in patients diagnosed with ADED between January 2011 and December 2016.

**Results:** A total of 260 vitrectomies in 243 patients were included in the analysis. Patients with rhegmatogenous retinal detachment (RRD) in combination with tractional retinal detachment (TRD) had poorer postoperative visual outcomes ( $P < 0.001$ ), whereas patients who had better preoperative visual acuity also had better postoperative visual outcomes ( $P < 0.001$ ). TRD in combination with vitreous hemorrhage (VH), patient age, and lens status did not contribute to a poorer postoperative visual outcome ( $P > 0.05$ ). Common postoperative complications included VH (9.6%), retinal redetachment (3.8%),



rubeotic glaucoma (1.5%), high intraocular pressure (1.2%), and pupillary block (0.4%). The anatomical success was 95.4% within 6 months of follow-up.

**Conclusions:** Vitrectomy improved vision and anatomical outcome in the majority of patients with ADED after vitrectomy. Poorer visual outcomes are associated in patients presenting with RRD in combination with TRD, whereas better preoperative visual acuities were associated with better postoperative visual outcomes.

Poster No.: EX1-072

### Outcomes of Vitreoretinal Surgery in Eyes With Regressed Retinopathy of Prematurity

First Author: Parveen **SEN**

Co-Author(s): Ashutosh **AGARWAL**, Pramod **BHENDE**, Gopal **LINGAM**

**Purpose:** To study the surgical outcomes of retinal detachment in eyes with regressed retinopathy of prematurity (ROP).

**Methods:** A total of 19 eyes of 19 patients were retrospectively studied. Anatomical and functional outcomes were recorded for all patients.

**Results:** Mean age of the patients was  $13.32 \pm 6.59$  years, with a range of 4 to 28 years. All patients had a history of premature birth. History of laser and vitrectomy for acute ROP was present in 6 and 2 patients, respectively. Mean presenting best corrected visual acuity (BCVA) was  $1.69 \pm 0.74$  logarithm of the minimum angle of resolution (logMAR). Pars plana vitrectomy (PPV) with or without scleral buckling (SB) was done in 12 patients and 7 patients underwent scleral buckling as the primary procedure. Of the patients undergoing SB, 5 had successful reattachment of retinal detachment (RD) after single surgery (71.4%), and 2 eyes had recurrent RD. Of the 12 patients who underwent PPV, 7 had retinal reattachment after a single surgery (58.33%), while 5 had recurrent RD. Mean follow-up period was 3.71 years (range, 2 months to 11.2 years). Improvement in visual acuity was noted

in 9 (47.4%) eyes, 5 eyes (26.3%) retained the same visual acuity, and deterioration was noted in 5 (26.3%) eyes. In eyes with visual improvement, mean preoperative BCVA was  $1.54 \pm 0.79$ , which improved to  $0.94 \pm 0.46$  ( $P = 0.007$ ). In eyes with visual deterioration, mean preoperative BCVA was  $1.98 \pm 0.67$ , which worsened to  $2.08 \pm 0.76$  logMAR ( $P = 0.041$ ).

**Conclusions:** Rhegmatogenous RD is the major vision-threatening complication of regressed ROP. Early recognition and surgical intervention can lead to a high rate of anatomical success and prevent the development of profound visual impairment in some patients.

Poster No.: EX1-114

### Choroidal Thickness Changes in Patients With Persistent and Closed Macular Holes Following Vitreoretinal Surgery

First Author: Aylin **KARALEZLI**

Co-Author(s): Sabahattin **SUL**

**Purpose:** To compare the choroidal thickness (CT) between persistent and closed macular holes (MHs) following surgery.

**Methods:** Thirty-five eyes of 35 patients who underwent standard MH surgery (pars plana vitrectomy, internal limiting membrane peeling, 20 % sulphur hexafluoride endotamponade, and face down positioning for 1 week) were included. MH dimensions (minimum hole diameter and hole base diameter) and CTs from various points (subfoveal, temporal, nasal, superior, and inferior 1500  $\mu\text{m}$  from the center of the fovea) were measured with optical coherence tomography (OCT). Axial lengths (AL) were measured with swept-source optical biometry.

**Results:** Mean base diameter ( $930 \pm 317 \mu\text{m}$  vs  $1273 \pm 320 \mu\text{m}$ ,  $P = 0.005$ ), mean minimum hole diameter ( $395 \pm 151 \mu\text{m}$  vs  $658 \pm 185 \mu\text{m}$ ,  $P < 0.001$ ) were significantly lower in closed MHs than persistent MHs. Mean subfoveal CT ( $236 \pm 32 \mu\text{m}$  vs  $204 \pm 22.2 \mu\text{m}$ ,  $P = 0.006$ ) was also significantly higher in closed MHs than persistent MHs. At various points (temporal, nasal, superior, and inferior 1500  $\mu\text{m}$  from the





center of the fovea) mean CTs were insignificant between closed and persistent MHs. There was no correlation between MH dimensions (mean base diameter and minimum hole diameter) and CTs from various points ( $r = -0.072$  for hole base diameter and  $r = -0.190$  for minimum hole diameter). Differences in AL, age, and sex were insignificant between closed and persistent MHs.

**Conclusions:** Subfoveal CT seems to be thinner in persistent MHs in addition to minimal hole and hole base diameter. Local subfoveal choroidal thinning might be considered as a contrary factor to the MH healing process.

**Poster No.: EX1-115**

**ILM Peeling for Macular Edema Secondary to Branch Retinal Vein Occlusion**

*First Author: Hussain KHAQAN*

*Co-Author(s): Farrukh JAMEEL*

**Purpose:** To evaluate anatomic and functional outcomes in patients with macular edema in branch retinal vein occlusion (BRVO) treated with pars plana vitrectomy (PPV) and internal limiting membrane (ILM) peeling.

**Methods:** A total of 55 eyes underwent PPV with ILM peeling. Visual acuity, fluorescein angiography, and optical coherence tomography were performed preoperatively and postoperatively every 4 weeks for 1 year. This study was conducted at the Department of Ophthalmology, Post Graduate Medical Institute/Lahore General Hospital, Lahore from January 2011 to June 2016.

**Results:** In 46 (83.6%) eyes the central macular thickness improved from  $465 \pm 91 \mu\text{m}$  at baseline to  $295 \pm 103 \mu\text{m}$  ( $P < 0.003$ ). In 9 (16.3%) eyes central macular thickness did not decrease. In 43 (78.1%) eyes best corrected visual acuity (BCVA) improved ( $P < 0.05$ ). In 37 (86%) eyes BCVA improved by a mean 3.6 Snellen lines, while in 6 (13.9%) eyes BCVA improved by a mean 2.4 Snellen lines. In 12 eyes (21.8%) BCVA did not improve. There was no statistically significant difference in visual acuity improvement in ischemic or nonischemic

BRVO ( $P > 0.05$ ).

**Conclusions:** PPV with ILM peel is beneficial for macular edema secondary to BRVO and improves visual acuity in ischemic and nonischemic BRVO.

**Poster No.: EX1-116**

**ILM Peeling in Rhegmatogenous Retinal Detachment Associated Macular Holes**

*First Author: Hussain KHAQAN*

**Purpose:** To evaluate anatomical and visual outcomes in patients with retinal detachment (RD) associated macular hole with pars plana vitrectomy (PPV) and internal limiting membrane (ILM) peeling.

**Methods:** A total of 37 eyes underwent PPV, ILM peeling, and internal tamponade of C3F8 in patients with RD associated macular hole. Optical coherence tomography was performed preoperatively and postoperatively. This study was conducted at the Department of Ophthalmology, Post Graduate Medical Institute/Lahore General Hospital, Lahore from April 2013 to December 2016.

**Results:** Macular hole closed and retina was flat in 35 (94.5%) eyes. In 2 (5.4%) eyes retina was attached but macular hole did not close. Visual acuity improved in all 37 patients (mean, 2.2 Snellen lines).

**Conclusions:** PPV and ILM peeling has a high success rate in closure of macular hole and visual acuity improvement in retinal detachment.

**Poster No.: EX1-117**

**Review of Silicone Oil Removal Cases Done in the Year 2016 at a Tertiary Hospital Center**

*First Author: Nurul Shima ISMAIL*

*Co-Author(s): Kiet Phang LING, Haslina MOHD ALI, Nik Nurfarhana NIK MOHD NOOR, Wee Min TEH*

**Purpose:** To study the types of cases and age of patients receiving silicone oil, duration of the oil left in the eye, and its association with redetachment.

**Methods:** Retrospective review of 46 cases of





oil removal (ROO) done at Hospital Sultanah Bahiyah in the year 2016 by various surgeons.

**Results:** Out of the 46 cases with silicone oil tamponade, 21 cases (45.7%) were done for advanced diabetic eye disease (ADED) while 25 cases (54.3%) were for rhegmatogenous retinal detachment (RD). Subjects' age ranged from 26 to 76 years, with the majority (27 subjects or 58.7%) aged between 40 and 60 years. Fourteen subjects (30.4%) were above 60 years of age and the remaining 5 subjects (10.9%) were less than 40 years old. The mean duration of silicone oil in the eye was  $8 \pm 0.5$  months. Three cases (6.5%) had ROO done before 3 months, 3 were done for redetachment, and 1 was due to uncontrolled intraocular pressure. Majority (31 cases or 67.4%) had oil removal within 6 to 12 months, followed by 3 to 6 months (7 cases or 15.2%), and after 12 months (5 cases or 10.9%). There was a case of redetachment occurring within 1 month after ROO due to proliferative vitreoretinopathy changes.

**Conclusions:** The timing of ROO varies, but most authors suggest its removal within 6 months because of oil-related complications. However, in our setting, with limited resources but increasing number of patients indicated for silicone oil, it is essential to study the effect of prolonged silicone oil and optimal timing of ROO in such patients.

---

Poster No.: EX1-118

### Outcome of Macular Hole Surgery With Dye-Assisted Internal Limiting Membrane Peeling in Nepal

First Author: Sanyam **BAJIMAYA**

Co-Author(s): Govinda **PAUDYAL**, Samyek **SHAKYA**, Raba **THAPA**

**Purpose:** This study aimed to assess the anatomical and visual outcomes of idiopathic macular hole (IMH) surgery with dye-assisted peeling of the internal limiting membrane (ILM).

**Methods:** This was a hospital-based, prospective study enrolling all patients with IMH who underwent macular hole surgery from

April 2014 to June 2015 who were followed up for more than 3 months.

**Results:** Out of 50 eyes of 50 patients (12 males and 37 females), 20% had stage 2, 28% had stage 3, and 52% had stage 4 macular hole. The mean minimum linear dimension (MLD) was  $566.26 \pm 208.66 \mu\text{m}$  (range, 120-1290  $\mu\text{m}$ ). Forty-two eyes (84%) underwent vitrectomy, whereas in 8 eyes (8%) vitrectomy was combined with phacoemulsification and foldable intraocular lens (IOL) implantation. Indocyanine green (ICG) dye was used for ILM staining. The MH apposed in 34 eyes (68%) at 6 weeks and in 41 eyes (82%) at 3 months after surgery. Overall visual improvement was seen in 31 eyes (62%); 27 eyes (54%) had a visual improvement of  $\geq 2$  Snellen lines, 4 eyes (8%) had improvement of 1 Snellen line, 8 eyes (16%) had the same vision, while 11 eyes (22%) had worse vision than preoperative best corrected visual acuity (BCVA) at last follow-up. Progression of cataract was seen in 9 eyes (25.71%), whereas high intraocular pressure (IOP) was seen in 2 eyes (4%).

**Conclusions:** Most patients had successful anatomical closure and half of the eyes achieved visual success after macular hole surgery.

---

Poster No.: EX1-119

### A 3-Year Audit of Intraoperative Complication Rates in Klinik Katarak 1 Malaysia Mobile, Sarawak, Malaysia

First Author: Sing Hui **LU**

Co-Author(s): Sangeetha **MANOHARAN**, S Kala **SUMUGAM**

**Purpose:** To describe all the complication rates during the cataract surgeries in Klinik Katarak 1 Malaysia (KK1M) Mobile, Sarawak, Malaysia.

**Methods:** A retrospective cohort study. All intraoperative complications during the cataract surgeries in KK1M Mobile Sarawak, which were registered with the Cataract Surgery Registry during the period of 3 years from 2014 to 2016, were analyzed. The rates were compared with published results and the National Eye





Database's annual reports.

**Results:** From 2014 to 2016, a total of 2287 cataract surgeries were done in KK1M Mobile Sarawak. Of these, 2227 (97.38%) surgeries were done by specialists, 59 (2.58%) surgeries were done by gazetted specialists, and 1 (0.04%) surgery was done by a medical officer. Intraoperatively, there were 55 (2.4%) posterior capsular rents (PCR), 16 cases (0.70%) of vitreous loss, 17 cases (0.74%) of zonular dehiscence, 6 cases (0.26%) of nucleus drop, and 1 (0.04%) suprachoroidal hemorrhage. A total of 2229 (97.46%) surgeries were done by phacoemulsification, 34 (1.49%) surgeries were done by extracapsular cataract extraction (ECCE), and 4 surgeries were done by intracapsular cataract extraction (ICCE).

**Conclusions:** The incidence of PCR and vitreous loss in KK1M Mobile Sarawak is lower than the national average of 2.7% for PCR and 1.7% for vitreous loss. It has met the national key performance index (KPI) and is within the international accepted standard. This has shown that KK1M Mobile Sarawak, an outreach cataract service to rural settings from the Ministry of Health, has successfully accomplished its main objective since its launch on September 12, 2013.

---

**Poster No.:** EX1-120

**Birds, Sex, and Ocular Injuries in Queensland**

*First Author:* Deveraj **SUPRAMANIAM**

*Co-Author(s):* Timothy **BECKMAN**, Richard **SARAFIAN**

**Purpose:** Case report.

**Methods:** The Australian magpie is well known to become aggressive during its mating season between late August and early October. In Central Queensland there were 19 presentations to the emergency department in the past 3 years involving injuries to the eye caused by magpies. Many of these involved children and occurred during the notorious mating season. Three of these presentations were serious penetrating eye injuries requiring surgical intervention. Often, this leaves the child with serious long-term visual issues.

Timely intervention is key in reducing the risk of complications and maximizing visual outcomes. One recent case involved a 13-year-old boy who required extensive repair to his left eye, with a large corneal laceration, traumatic cataract, and significant iris tissue loss. The patient underwent emergency repair of the corneal wound. After 6 months, a secondary intraocular lens (HMK ANI 2, Ophtec) designed for the correction of traumatic aniridia was used.

**Results:** Vision improved from counting fingers to 6/6 corrected, resulting in both a functional and aesthetically pleasing outcome. This is particularly important in such cases, especially when the injury involves children. It is also important to understand the potential risks and complications associated with infection, with previous reports of keratitis after injury attributed either directly or indirectly to the magpie.

**Conclusions:** This case demonstrates the extent to which magpies can cause injury and the importance of establishing preventative measures to reduce such incidences. Education is a vital aspect of prevention and needs to be targeted toward those more at risk.

---

**Poster No.:** EX1-121

**Efficacy and Cost of Focal/Grid Laser Photocoagulation Combined With Intravitreal Injection of Conbercept for Diabetic Macular Edema**

*First Author:* Chang **LIBIN**

**Purpose:** To evaluate the efficacy and cost of focal/grid laser photocoagulation combined with intravitreal injection of conbercept to treat refractory diabetic macular edema.

**Methods:** This prospective case series comprised 62 patients (66 eyes) with refractory diabetic macular edema at Beijing Jingmei Group General Hospital. All patients, who had received more than 3 intravitreal injections of anti-vascular endothelial growth factor (anti-VEGF) drugs, were randomly divided into the intravitreal injection of conbercept





(IVC) group or the focal/grid retinal laser photocoagulation combined with intravitreal injection of conbercept (combined) group. All proliferative diabetic retinopathy (PDR) and severe nonproliferative diabetic retinopathy (sNPDR) patients received panretinal laser photocoagulation. The best corrected visual acuity (BCVA), slit lamp, intraocular pressure, optical coherence tomography, and fundus examination were performed preoperatively and postoperatively at 3 months and 6 months.

**Results:** The BCVA and central macular thickness (CMT) were improved in both groups ( $P < 0.05$ ). No significant difference was found between the IVC group and the combined group for BCVA and CMT ( $P > 0.05$ ). However, during 6 months, in order to stabilize the improvement of BCVA and CMT, compared with the combined group, more repeat injections were needed in the IVC group.

**Conclusions:** Intravitreal injection of conbercept with or without retinal laser photocoagulation remarkably ameliorates refractory macular edema and improves visual acuity in the short-term. Intravitreal injection of conbercept with retinal laser photocoagulation is less costly to treat diabetic macular edema.

---

Poster No.: EX1-122

### Efficacy of Subthreshold Micropulse Laser Therapy for the Treatment of Chronic Central Serous Retinopathy

First Author: V V SAMEERA

Co-Author(s): Guruprasad AYACHIT, Shrinivas JOSHI

**Purpose:** To assess the clinical efficacy of 577-nm micropulse laser therapy (MPLT) for the treatment of chronic central serous retinopathy (CSR).

**Methods:** Nineteen eyes of 17 patients with chronic CSR (>4 months duration) were subjected to ophthalmic examination, fundus fluorescein angiography (FFA), autofluorescence (FAF), and spectral domain optical coherence tomography (SD-OCT). All eyes were subjected to MPLT (IQ 577 laser) and followed up at 4 weeks, 2, and 3 months. Areas of focal and

diffuse leaks were treated with multiple laser spots (grid  $5 \times 5$ , duty cycle 5%) with no spot spacing. Primary outcomes studied were change in subretinal fluid (SRF) height and central macular thickness (CMT). Secondary outcome measure was change in best-corrected visual acuity (BCVA).

**Results:** The average age of the patients was 40.3 years and the mean duration of leak was 7 months. Fifteen patients were males and 2 were females. Three patients were on rifampicin for 12 weeks but never responded. All 19 eyes responded to the treatment. The mean pretreatment SRF height was  $340.25 \mu\text{m}$  and posttreatment showed a mean reduction to  $102.75 \mu\text{m}$  (day 30) and  $38.25 \mu\text{m}$  (3 months), respectively ( $P = 0.0002$ ). The mean CMT improved from  $428 \mu\text{m}$  to  $268 \mu\text{m}$  in 3 months ( $P = 0.006$ ). There was no evidence of retinal or retinal pigment epithelium damage on SD-OCT or FAF. No visible laser marks could be detected by clinical observation, SD-OCT, and FAF. The mean BCVA improved 3 months after laser treatment from 0.46 [in logarithm of the minimum angle of resolution (logMAR)] to 0.26 ( $P = 0.009$ ).

**Conclusions:** Subthreshold MPLT is a cost-effective and safe treatment option in chronic CSR.

---

Poster No.: EX1-123

### Evolution of Subretinal Proliferations After Scleral Buckling for Rhegmatogenous Retinal Detachment Repair

First Author: Yu Cheol KIM

Co-Author(s): Seungmin HA

**Purpose:** To describe the evolution of subretinal proliferation (SRP) with optical coherence tomography (OCT) in patients who had scleral buckling surgery (SB) for the treatment of rhegmatogenous retinal detachment (RRD).

**Methods:** This was a descriptive study of 10 cases (9 patients) who had SB with external drainage for RRD with SRP. The medical records including fundus photographs and serial optical coherence tomography were retrospectively







analyzed. Analysis included shape, preoperative and postoperative location, invagination, size reduction, heterogeneity of SRP, and absorption of subretinal fluid (SRF).

**Results:** The mean subject age was 19.2 years at the time of surgery. Mean follow-up period was 49.1 weeks. One case had a membranous SRP, while all the others had strand-like SRPs. Preoperative SRP locations were beneath the retina in 6 cases, intraretinal in 1 case, and between the retina and retinal pigment epithelium (RPE) in 1 case. SRP showed heterogeneity in 1 case, and no case showed complete resolution of SRP. Final SRP locations were intraretinal in 2 cases, on the RPE in 7 cases, and between the retina and RPE in a single case. The SRP invaginated into the retina in 2 cases while being absorbed.

**Conclusions:** Detached retina can be reattached successfully after retinal break occlusion by buckling surgery, although the remaining SRP can disturb it. The OCT images of SRP have various features in location, reflectivity, and morphology. In most cases, the SRPs are strand-like located beneath the retina before surgery and located on the RPE after reattachment. In some cases, SRP invaginates into the retina after a successful SB.

Poster No.: EX1-124

### Ganglion Cell-Inner Plexiform Layer Thickness and Visual Improvement After Vitrectomy for Rhegmatogenous Retinal Detachment

First Author: Mirinae **JANG**  
Co-Author(s): Jin Young **KIM**

**Purpose:** To evaluate the association of postoperative macular ganglion cell-inner plexiform layer (GCIPL) thickness with postoperative visual outcomes in patients undergoing vitrectomy for macula-off rhegmatogenous retinal detachment (RRD) using spectral domain optical coherence tomography.

**Methods:** Data from 22 eyes with macula-off RRD who were followed for more than 6 months after successful pars plana vitrectomy

were analyzed. Macular GCIPL thickness in eyes with RRD was compared with that of the normal contralateral eyes 6 months after surgery. The correlation between the interocular difference in GCIPL thickness and postoperative best corrected visual acuity (BCVA) was evaluated.

**Results:** Preoperative and postoperative central macular thickness were  $538.09 \pm 318.42 \mu\text{m}$  and  $230.77 \pm 34.69 \mu\text{m}$ . Macular GCIPL thickness in eyes with RRD 6 months after surgery was  $442.05 \pm 40.40 \mu\text{m}$  and in the unaffected contralateral eyes was  $366.23 \pm 72.27 \mu\text{m}$ . The interocular difference in macular GCIPL thickness was significantly correlated with postoperative BCVA. Among patients with intact photoreceptor layers, a greater decrease in GCIPL thickness was correlated with a worse postoperative BCVA ( $r = 0.629$ ;  $P = 0.02$ ). No significant correlations were identified between interocular macular GCIPL thickness difference and age ( $r = 0.629$ ;  $P = 0.85$ ) or axial length ( $r = 0.874$ ;  $P = 0.43$ ).

**Conclusions:** Macular GCIPL thickness decreased after vitrectomy to repair RRD. The decrease in GCIPL thickness was significantly correlated with postoperative visual outcomes.

Poster No.: EX1-125

### Intraocular Foreign Body: Risk Factors, Prognostic Factors, and Visual Outcome

First Author: Han Nie **CH'NG**  
Co-Author(s): Tengku Ain **KAMALDEN**, Haslina **MOHD ALI**

**Purpose:** To evaluate the risk factors, prognosis, and visual outcome in open globe injuries with intraocular foreign body.

**Methods:** Retrospective case series.

**Results:** Out of 142 ocular trauma cases requiring surgery at Hospital Sultanah Bahiyah, Alor Setar from 2012 to 2016, 22 eyes (15.5%) had intraocular foreign body (IOFB). All cases were male, aged from 6 to 67 years old with a mean age of 33 years old. The majority of the cases (45.5%) were associated with hammering or welding work and 36% were caused by lawn equipment. None of these cases wore





any protective eyewear. The presenting vision was counting fingers or worse in 13 eyes (59%) while 9 eyes (41%) had 6/6 to 6/36 vision. Endophthalmitis developed in 5 (22.7%) cases, while 8 eyes (36.4%) developed retinal detachment. All the patients underwent pars plana vitrectomy and IOFB removal. More than two thirds (72.7%) of cases required more than 1 surgery. After 6 months of follow-up, 54% had vision 6/24 or better, while 27% had hand movement vision or worse. Patients with poor visual outcome had a mean ocular trauma score of 69. Endophthalmitis, perforating injury, retinal detachment, and siderosis bulbi were associated with poorer visual outcome.

**Conclusions:** Most cases of IOFB reported were preventable work-related injuries, as none used any protective eyewear. Poorer visual outcome was associated with ocular complications and lower ocular trauma score. Our study highlights the need to reinforce the use of protective eyewear in the work place, including for work involved in farming.

---

Poster No.: EX1-126

### Long-Term Outcome of Conventional and Half-Fluence Photodynamic Therapy for Chronic Central Serous Chorioretinopathy

First Author: Sanghyu **NAM**

Co-Author(s): Kunho **BAE**, Eung Suk **KIM**, Bo Kwon **SON**, Seung Young **YU**

**Purpose:** To evaluate the long-term efficacy and safety of conventional photodynamic therapy (PDT) and half-fluence PDT in chronic central serous chorioretinopathy (CSC).

**Methods:** Retrospective review of chronic CSC patients treated with conventional PDT or half-fluence PDT and a minimum follow-up of 12 months between October 2007 and June 2015. Best-corrected visual acuity (BCVA), central retinal thickness (CRT), neural retinal thickness (NRT), choroidal thickness (CT), recurrence of CSC after PDT, and resolution of subretinal fluid (SRF) at 12, 24, and 36 months were assessed.

**Results:** The study included 52 eyes that completed the 36-month follow-up. Twenty-

eight eyes received conventional PDT and 24 eyes received half-fluence PDT. The mean follow-up period was 45 months. The mean logarithm of the minimum angle of resolution (logMAR) BCVA improved significantly ( $P < 0.001$ ), both in the conventional group (from  $0.36 \pm 0.32$  to  $0.15 \pm 0.27$ ) and in the half-fluence group (from  $0.31 \pm 0.29$  to  $0.15 \pm 0.28$ ) at 36 months, without a significant difference between the 2 groups ( $P = 0.711$ ). The mean CRT decreased significantly ( $P < 0.001$ ), both in the conventional group (from  $395.2 \pm 185$  to  $205.2 \pm 45.8$ ) and in the half-fluence group (from  $341.8 \pm 97.9$  to  $205.6 \pm 50.1$ ) at 36 months, without a significant difference between the 2 groups ( $P = 0.362$ ). Both groups showed significant reduction in CT at months 36 after PDT with a significant difference ( $P < 0.001$ ). At 36 months, all patients in both groups had complete absorption of SRF. There was no recurrence of SRF during the follow-up.

**Conclusions:** Both treatments were effective and safe in chronic central serous chorioretinopathy with a significant improvement in the long term, both anatomic and visual, without recurrence of SRF.

---

Poster No.: EX1-127

### Macular Hole Surgery: Peeling vs Folding Method, Alor Setar Experience

First Author: Fatin Nadia **ZAMAWI**

**Purpose:** To review the surgical outcomes of macular hole surgery with internal limiting membrane (ILM) peeling versus folding method in macular hole (MH) surgery in Hospital Sultanah Bahiyah (HSB), Alor Setar.

**Methods:** A retrospective study reviewing the functional and anatomical outcomes of macular hole surgery via methods of peeling or folding for all purely full-thickness MH (FTMH) in HSB between January 2011 and December 2016.

**Results:** Eighty-seven patients with FTMH underwent surgery from January 2011 to December 2016. A total of 63.2% (55) were females and 32 were males. Age ranged from 33-76 years. We observed the outcomes





of macular hole surgery by comparing the peeling and folding methods based on visual improvement and macular hole closure at 6 months after surgery. All surgeries were performed by a single surgeon at HSB. Twenty-six cases (29.9%) were done using the folding method whilst 61 cases (70.1%) of macular holes were peeled. Eighteen cases (69.2%) operated on using the folding method showed visual improvement by 2 or more lines whereas only 32 cases (52.4%) showed visual improvement with the peeling method. Hole closure was achieved in all cases using the folding method as compared to only 37 cases (60.7%) of complete hole closure using the peeling method at 6 months after surgery.

**Conclusions:** In conclusion, the ILM folding method showed superior outcomes in terms of functional and anatomical closure success as compared to ILM peeling in MH surgery in HSB. Besides techniques, MH surgical success can also be attributed to the size of MH and its chronicity.

---

**Poster No.: EX1-128**  
**Multiple Retinal Holes Secondary to Valsalva Retinopathy**

*First Author: Rajya GURUNG*

**Purpose:** Valsalva retinopathy is a common condition but retinal holes secondary to valsalva retinopathy are rarely reported. We report a case of valsalva retinopathy with incidental multiple retinal holes.

**Methods:** A 25-year-old male presented with sudden loss of vision in the right eye (RE) following lifting heavy load. The presenting best corrected visual acuity (BCVA) in his RE was 6/36 and left eye was 6/6. Fundus evaluation of RE revealed well circumscribed dome-shaped premacular hemorrhage about 3 disc diameters in size. YAG laser membranotomy was done with Zeiss Visuals YAG III machine with a single shot of 8 mJ. At 2 weeks of follow-up, the premacular hemorrhage was noticeably absorbed but he developed 2 full thickness retinal holes near the

inferior border of premacular hemorrhage. At 4 weeks, the full thickness retinal holes increased to 4 in number and the BCVA decreased to 6/60. Optical coherence tomography (OCT) showed 4 full thickness retinal holes with intact but thickened internal limiting membrane. Pars plana vitrectomy (PPV) with internal limiting membrane peel with gas tamponade was done for the retinal holes.

**Results:** Post PPV, the BCVA improved to 6/18. Fundus examination showed complete absorption of macular hemorrhage. OCT showed that the retinal holes were still present. Six months after the onset, the BCVA, fundus examination results, and OCT findings were stable.

**Conclusions:** Multiple retinal holes secondary to valsalva retinopathy have been rarely reported and the mechanism needs further understanding. This case illustrates the possibility of retinal hole formation in valsalva retinopathy.

---

**Poster No.: EX1-129**  
**Pars Plana Posterior Capsulectomy During Combined Vitrectomy and Cataract Surgery**  
*First Author: Yu Cheol KIM*

**Purpose:** To evaluate the effect and safety of pars plana capsulectomy during combined vitrectomy and cataract surgery.

**Methods:** Patients (n = 76) who underwent combined vitrectomy and cataract surgery from June 2013 to November 2015 and had follow-up of more than 2 months were enrolled in this study. The patients were categorized into group A (patients with pars plana capsulectomy during surgery) and group B (patients without pars plana capsulectomy during surgery). The medical records were reviewed and best corrected visual acuity (BCVA), intraocular pressure, intraocular lens (IOL) stability, and inflammation were analyzed.

**Results:** Group A included 17 males and 20 females with a mean age of 60.58 years. Group B included 21 males and 18 females with a mean age of 64.3 years. Preoperative diagnoses





were epiretinal membrane, proliferative diabetic retinopathy, macular hole, vitreomacular traction, and vitreous hemorrhage. Preoperative BCVA was logarithm of the minimum angle of resolution (logMAR)  $0.65 \pm 0.32$  in group A and logMAR  $0.56 \pm 0.21$  in group B. Postoperative BCVA was logMAR  $0.32 \pm 0.11$  and logMAR  $0.38 \pm 0.14$ , respectively, showing no significant difference ( $P = 0.332$ ). In group A, no case had capsular opacity that needed additional capsulotomy. IOL decentration or gas prolapse to the anterior chamber was not identified in either group.

**Conclusions:** Pars plana posterior capsulectomy during combined vitrectomy and cataract surgery is a safe and effective procedure.

**Poster No.: EX1-130**

**Reopening of Macular Hole After Intravitreal Aflibercept for Neovascular Age-Related Macular Degeneration**

*First Author: Errol CHAN*

*Co-Author(s): John CHEN, Vincent SUN*

**Purpose:** To describe the clinical course and surgical outcome of a patient with full-thickness macular hole (FTMH) recurrence after aflibercept injections for wet age-related macular degeneration (AMD).

**Methods:** Case report with spectral domain optical coherence tomography (SD-OCT) retinal imaging.

**Results:** An 84-year-old patient had a FTMH in the right eye (OD), which was successfully closed following pars plana vitrectomy and internal limiting membrane (ILM) peel 4 years previously. In the past 1 year, he developed neovascular AMD OD. After 6 intravitreal aflibercept injections, visual acuity (VA) was 20/50 OD and the macula was dry. Four days after the seventh injection, VA had decreased to 20/200. SD-OCT demonstrated a reopened FTMH with a diameter of 430  $\mu\text{m}$ . There was a reduction in pigment epithelial detachment (PED) height and increase in subretinal fluid (SRF). An epiretinal membrane (ERM) was also present. We performed a 23-gauge pars

plana vitrectomy with indocyanine green-assisted removal of additional ILM, followed by sulfur hexafluoride (SF<sub>6</sub>) 20% tamponade. Postoperatively at 1 month, the FTMH was closed and VA had improved to 20/80.

**Conclusions:** Reopening of a macular hole is a rare complication of wet AMD managed with aflibercept therapy. In this case, pars plana vitrectomy and membrane peel successfully effected hole closure and preserved baseline VA.

**Poster No.: EX1-131**

**The Efficacy of Low-Duration Laser in Preserving the Survival of Inner Retinal Cells**

*First Author: Ohisa HARLEY*

**Purpose:** To evaluate the efficacy of low-duration laser (50 ms duration) in maintaining the survival of inner retinal cells in diabetic retinopathy patients.

**Methods:** Twenty-two eyes with severe nonproliferative diabetic retinopathy or proliferative diabetic retinopathy that underwent 3 panretinal photocoagulation treatments were prospectively followed. The patients were divided into 2 groups involving the standard laser or low-duration laser treatment. Survival of the inner retina was assessed using full-field electroretinography involving changes in amplitude and implicit times of the b-wave rod response.

**Results:** There was no significant change in amplitude in eyes treated with the low-duration laser ( $-14.29 \pm 30.479 \mu\text{V}$ ;  $P = 0.172$ ), but there was a significant change in eyes treated with the standard laser ( $-45.65 \pm 28.189 \mu\text{V}$ ;  $P = 0.001$ ). There was no significant change in implicit times in each group ( $P = 0.177$  and  $P = 0.685$ , respectively). The change in amplitude in eyes treated with the low-duration laser was significantly lower than in eyes treated with the standard laser ( $-71.43 \pm 25.408$  versus  $8.18 \pm 86.432$ , respectively;  $P = 0.018$ ).

**Conclusions:** Treatment with the low-duration laser is effective in maintaining the survival of inner retinal cells.



Poster No.: EX1-132

**Use of Third-Generation Recombinant Tissue Plasminogen Activator (Tenecteplase) in Submacular Hemorrhage Secondary to Ruptured Macroaneurysm: First Reported Case in Malaysia**

*First Author: Wen Yee LEE*

*Co-Author(s): Kiet Phang LING, Haslina MOHD ALI, Norlina MOHD RAMLI, Wee Min TEH*

**Purpose:** To report a case of severe submacular hemorrhage resulting from ruptured macroaneurysm that was successfully treated with vitrectomy and intravitreal tenecteplase (50 mcg/0.1 mL).

**Methods:** Case report.

**Results:** A 51-year-old Malay man with underlying diabetes mellitus, hypertension, dyslipidemia, and end-stage renal failure was under regular follow-up for proliferative diabetic retinopathy (quiescent and well-lasered). He returned with sudden painless loss of vision in the right eye. Right eye vision had dropped from 6/9 to counting fingers. Left eye vision remained the same (6/9). Clinically, there was no fundus view in the right eye due to vitreous hemorrhage. A diagnosis of right eye advanced diabetic eye disease was made. He received 3 monthly intravitreal ranibizumab injections before proceeding to right eye pars plana vitrectomy for nonclearing vitreous hemorrhage. Intraoperatively, dense vitreous hemorrhage with extensive submacular hemorrhage and inferotemporal macroaneurysm were noted. Intravitreal tenecteplase (50 mcg/0.1 mL) was given at the end of vitrectomy. The subretinal hemorrhage completely reabsorbed at 1 month postoperatively. He underwent phacoemulsification and intraocular lens implantation about 2 months after vitrectomy surgery. Final visual acuity improved significantly, regaining his previous vision of 6/9.

**Conclusions:** Tenecteplase, with its better retinal penetration as well as lesser toxicity compared with other recombinant tissue plasminogen activators, could represent

a feasible treatment alternative for the management of subretinal and subhyaloid hemorrhages.

Poster No.: EX1-136

**Combined Retinal Detachment and Lens Dislocation in Marfan Syndrome: Clinical and Surgical Approach**

*First Author: Osman ARSLAN*

*Co-Author(s): Mahmut KAYA, Nilüfer KOÇAK, Süleyman SKAYNAK, Arif Taylan ÖZTÜRK*

**Purpose:** To determine the functional and anatomic outcome of combined retinal detachment and dislocated crystalline lens surgery in Marfan syndrome.

**Methods:** Retrospective review of charts of Marfan syndrome patients who had combined retinal detachment and dislocated crystalline lens surgery at Dokuz Eylül University, Department of Ophthalmology.

**Results:** Three patients with 3 surgically treated eyes were identified. Retinal detachment and dislocated crystalline lens were present in all eyes. Cases involving 3 eyes with dislocated crystalline lens and rhegmatogenous retinal detachment, into which liquid perfluorocarbon was injected after vitrectomy to float the dislocated lens material off the retina and reattach the retina, were observed. The dislocated lens was removed while floating on the perfluorocarbon liquid, which also provided a cushion that prevented dropped fragments of lens from traumatizing the retina. In all 3 cases, eyes were left aphakic and underwent pars plana vitrectomy with silicone oil injection. All 3 eyes had visual acuity of 20/200 or better (range, 20/30-20/200). The retina of all eyes remained successfully reattached after a long term follow-up.

**Conclusions:** Results of surgical repair of combined retinal detachment and dislocated crystalline lens in Marfan syndrome were better than previously thought. Currently available vitreoretinal surgical techniques result in successful reattachment of the retina and functional improvement in eyes with combined





retinal detachment and dislocated crystalline lens.

Poster No.: EX1-137

### Effect of One-Third Dose Photodynamic Therapy for Chronic Central Serous Chorioretinopathy

First Author: Shun **KUMASHIRO**

Co-Author(s): Tetsushi **ARIMURA**, Yuichi **HORI**, Hironori **OSAMURA**, Tomoaki **SHIBA**

**Purpose:** To evaluate the effect of one-third dose photodynamic therapy (PDT) for chronic central serous chorioretinopathy (CSC).

**Methods:** We studied 7 chronic CSC patients with serous retinal detachment lasting more than 6 months. One-third PDT was performed only changing the dosage of verteporfin from the conventional recommended PDT. Visual acuity, central foveal thickness (CFT), and central choroidal thickness (CCT) were evaluated at the points before, 2 weeks, and 1 month after 1/3 PDT.

**Results:** CFT was significantly reduced from before 1/3 PDT [before:  $253 \pm 62$ ; 2 weeks:  $168 \pm 46$ ; 1 month:  $180 \pm 46 \mu\text{m}$ ;  $P = 0.0004$ ; analysis of variance (ANOVA)]. Serous retinal detachment (SRD) was absorbed in all cases at 2 weeks. CCT and visual acuity did not show a significant difference during the measurement period. SRF in 1 eye recurred at 1 month.

**Conclusions:** One-third dose PDT for chronic CSC may be a useful method for morphological improvement.

Poster No.: EX1-139

### Optical Coherence Tomographic Findings of Retinal Pigment Epithelium Changes After Photodynamic Therapy for Polypoidal Choroidal Vasculopathy

First Author: Sarojini **KRISHNAN**

Co-Author(s): Kiat Phang **LING**, Haslina **MOHAMAD ALI**, Wee Min **TEH**

**Purpose:** To describe the optical coherence tomography (OCT) changes in the retinal pigment epithelium (RPE) induced by photodynamic therapy (PDT) in eyes

associated with idiopathic polypoidal choroidal vasculopathy (IPCV).

**Methods:** A retrospective study of patients with IPCV who underwent PDT followed by 3 consecutive monthly intravitreal ranibizumab injections, with a 6-month follow-up.

**Results:** Eighteen eyes of 13 patients (6 male and 7 female with median age 69 years) were included in this study. All the eyes had shown some degree of RPE alterations after PDT, characterized by thickening changes (hypertrophy) or thinning changes (atrophy) compared to baseline. At 3 months, 14 eyes (77.78%) showed hypertrophy of RPE and only 4 eyes (22.22%) showed atrophy of the RPE. At 6 months, RPE atrophy was seen in 12 eyes (67.67%) and only 6 eyes had thickened RPE layer compared with baseline.

**Conclusions:** OCT images demonstrated some degree of RPE alterations after PDT, whereby the natural evolution of RPE atrophy will take months or several years. Hence, the OCT findings of RPE changes can be used to serve as a marker of disease activity and treatment response. It has been reported that RPE atrophy correlated with visual acuity. Therefore, we believe that with rapid progression of RPE atrophy at 3 months, different modalities such as anti-vascular endothelial growth factor (anti-VEGF) or reduced-fluence PDT should be considered. Our study showed that most RPE atrophy occurred after 6 months. Further research is required to define the role of post-PDT RPE changes in OCT in the treatment of IPCV.

Poster No.: EX1-140

### Efficacy of Photodynamic Therapy Combined With Intravitreal Ranibizumab for Idiopathic Polypoidal Choroidal Vasculopathy

First Author: Sarojini **KRISHNAN**

Co-Author(s): Haslina **ALI**, Kiat Phang **LING**, Wee Min **TEH**

**Purpose:** To report the efficacy of combined photodynamic therapy (PDT) with intravitreal ranibizumab injection in the treatment of



idiopathic polypoidal choroidal vasculopathy (IPCV).

**Methods:** We retrospectively reviewed the records of 13 patients (13 eyes) diagnosed to have IPCV between August 2015 and November 2016. All patients were treated with PDT combined with 3 consecutive monthly intravitreal ranibizumab injections and followed up for 6 months.

**Results:** Initial visual acuity (VA) ranged from hand movements (HM) to 6/9 and final VA varied from counting fingers (CF) to 6/9 at the end of follow-up. At 6 months, VA improved in 6 eyes (46.2%) by 1 line or more, was stable in 3 eyes (23.1%), and decreased in 4 eyes (30.8%). Optical coherence tomography showed an improvement in macular thickness in 6 eyes (46.2%) and recurrence in 5 eyes (38.5%). Two eyes (15.4%) had no regression with subfoveal scarring. One eye was complicated with subretinal hemorrhage after PDT.

**Conclusions:** PDT combined with ranibizumab injection seemed to be effective for improving vision and causing regression of the polypoidal lesions at 6 months. However, 30% showed less favorable outcomes. This might be caused by collateral damage to adjacent structures due to the effect of PDT and the natural history of PCV. Therefore, it is also important to exert clinical judgment in choosing either combination therapy or monotherapy based on individualized disease characteristics.





## E-POSTERS

### Intraocular Inflammation, Uveitis & Scleritis

#### **Burkholderia cepacia: A Rare Cause of Corneal Ulcer**

First Author: Jin Yi **YAP**

Co-Author(s): Mohtar **IBRAHIM**

**Purpose:** We aim to report a case of an uncommon organism that caused corneal ulcer together with intraocular inflammation.

**Methods:** We describe a single case study of corneal ulcer and intraocular inflammation caused by *Burkholderia cepacia*.

**Results:** We describe a case of a patient who presented with sudden onset of painful red left eye with discharge for a duration of 4 days. The patient complained of a wooden particle entering his left eye while cutting grass prior to the symptoms. Examination showed left eye corneal ulcer at paracentral 3 o'clock and the surrounding cornea was edematous. The anterior chamber activity was 3+ and the lens was cataractous. Intraocular pressure was 24 mm Hg. Fundus examination was normal. Corneal scraping culture and sensitivity was done and the result returned as *Burkholderia cepacia* sensitive to antibiotics ceftazidime, meropenem, and Bactrim (trimethoprim and sulfamethoxazole). He was treated with intensive topical ceftazidime and made a complete recovery after 4 weeks of treatment.

**Conclusions:** In conclusion, *Burkholderia* ocular infections are rare. A high index of clinical suspicion and laboratory investigations are required to initiate appropriate treatment. This is important in cases of *Burkholderia* infection because of its high resistance to antibiotics.

#### **A Case of Atypical Presentation of Herpetic Uveitis**

First Author: Mariam **AHMAD**

Co-Author(s): Sujaya **SINGH**

**Purpose:** To describe a case of herpetic uveitis

with unusual keratic precipitates.

**Methods:** A case report.

**Results:** A 21-year-old Malay man with no underlying comorbidities presented to our eye clinic with a complaint of left eye (LE) blurring of vision for 1 week. This was the first episode and was associated with glaring and sensitivity to light with mild redness. He denied any eye discharge. There was no associated facial pain or rashes or any history of trauma previously. There was no history of tuberculosis contact and no associated constitutional symptoms. There was no contact with anyone who had a red eye. He was not a contact lens user. On examination his vision in LE was 6/18 (6/9). Skin overlying his eye lids was healthy. Conjunctiva was mildly injected, cornea sensation was intact with diffusely scattered white stellate keratic precipitates (KPs) covering the endothelium. Anterior chamber cells were 3+ at presentation and anterior vitreous cells. Retina and intraocular pressure remained normal. Despite being on hourly steroids for 4 days he did not show any signs of improvement. He was subsequently started on acyclovir for 2 weeks and there was complete resolution of the keratic precipitates, anterior chamber cells, and vitreous cells.

**Conclusions:** Herpetic uveitis is a common presentation in the younger age group; however, its presentation can vary and should always be a differential diagnosis in patients with unusual KPs.

#### **A Rare Case of Choroidal Neovascular Membrane Following Endogenous Fungal Endophthalmitis**

First Author: Krishnendu **NANDI**

**Purpose:** We report here a rare case of choroidal neovascular membrane (CNVM) following endogenous endophthalmitis with subretinal abscess in the left eye due to *Scedosporium apiospermum* in an







immunocompetent individual.

**Methods:** The patient suffered from diabetic ketoacidosis and liver abscess, which was managed successfully. Subsequently the patient developed endophthalmitis in the right eye and subretinal abscess in the left eye. Left eye was treated with intravitreal antifungal and steroid injection. Systemically, the patient was treated with intravenous antibiotics and oral voriconazole. Left eye showed gradual improvement with reduction in abscess size with intravitreal injections. After 6 months the patient developed CNVM in the left eye, which was then treated successfully with 3 monthly injections of ranibizumab. She was then followed up for 3 years.

**Results:** At presentation the best corrected visual acuity was 6/6, N6 in the left eye (OS). At 3 years of follow-up following injection of ranibizumab, the best corrected visual acuity was 6/18, N12 in OS.

**Conclusions:** Our case was unique due to the rarity of presentation in an immunocompetent individual with no history of ocular trauma of vegetative origin or otherwise. This report also highlights the aggressive medical and surgical management required to salvage eyes affected by fungal endophthalmitis with subretinal abscess in the other eye. Such patients can develop CNVM related to subretinal scar tissue. Early detection, energetic treatment, and long follow-up are critical in such cases.

### Absence of Posterior Vitreous Detachment is a Risk Factor for Severe Bleb-Related Endophthalmitis

*First Author: Kazuhiko UMAZUME  
Co-Author(s): Hiroshi GOTO, Jun SUZUKI, Yoshihiko USUI, Yoshihiro WAKABAYASHI*

**Purpose:** Bleb-related endophthalmitis (BRE) after glaucoma surgery is an infection caused by bacteria in the avascular bleb gaining access into the eye. We report the clinical features and outcome of 10 consecutive eyes with severe BRE treated at our hospital.

**Methods:** Ten patients (10 eyes) with stage

IIIb BRE after trabeculectomy diagnosed and treated at the Department of Ophthalmology, Tokyo Medical University between April 2013 and May 2015 were studied. Patient background, interval from the first trabeculectomy, causative microorganisms, surgical methods, status of posterior vitreous detachment (PVD), and postoperative visual acuity were examined.

**Results:** The 10 patients comprised 8 males and 2 females, with mean age of 70.6 years at BRE onset. All eyes underwent trabeculectomy combined with mitomycin C prior to development of BRE. The interval from the first glaucoma surgery to onset of endophthalmitis was  $8.5 \pm 4.1$  years. Bacteria were isolated from intraocular samples of 8 eyes, namely, viridans streptococci in 5 eyes, *Staphylococcus epidermidis* in 1, *Branhamella catarrhalis* in 1, and coagulase-negative staphylococci in 1. BRE was treated by vitrectomy in 9 eyes and enucleation in 1 eye. PVD was produced intentionally during vitrectomy in 6 eyes. Histopathological examination of the enucleated eye showed no PVD. Visual acuity improved by 3 lines or more in 6 patients, while decimal visual acuity remained lower than 0.1 in 4 patients.

**Conclusions:** BRE developed frequently in eyes with no PCD. The absence of PVD may be a risk factor for severe BRE.

### Atypical Presentation of Eales Disease

*First Author: Justin YEAK  
Co-Author(s): Tajunisah IQBAL, Sujaya SINGH*

**Purpose:** To report a case of Eales disease presenting as uveitic glaucoma.

**Methods:** A case report.

**Results:** A 39-year-old man of Indian origin, with history of treated tubercular encephalitis in 2005, presented with recurrent episodes of right eye pain and redness with occasional halos for the past 6 months. Every exacerbation was treated as acute anterior uveitis with topical steroids. He subsequently developed increased intraocular pressure requiring topical





antiglaucoma medication. He presented to us during the fourth episode of right eye redness and pain, with visual acuity of 6/6. Examination of right eye showed quiet anterior chamber with no posterior synechiae. Gonioscopy showed peripheral anterior synechiae almost 360 degrees. There were cells in anterior vitreous, optic disc was pink with cup disc ratio of 0.6; there were new vessels seen at superotemporal and inferotemporal arcade, with gliosis. Intraocular pressure (IOP) was 31 mm Hg. Fundus fluorescein angiography (FFA) showed areas of hyperfluorescence temporal to the macula, with evidence of leakage. There was presence of capillary fallout next to the neovascularizations. Inflammatory and infective screenings were normal. Quantiferon TB Gold test was negative. Capillary fallout areas were treated with photocoagulation and neovascularizations with intravitreal bevacizumab. IOP was controlled with the addition of topical antiglaucoma therapy.

**Conclusions:** Eales disease can present as uveitic glaucoma. It can be due to angle damage caused by chronic recurrence of inflammation as evident in this case. It should be considered as a differential diagnosis in patients with history of tuberculosis exposure presenting with uveitis, high IOP, and retinal neovascularizations.

### Case Report: Panuveitis in Idiopathic CD4 Lymphocytopenia

First Author: Albaaza **NUADY**

Co-Author(s): Suharjo **PAWIROANU**

**Purpose:** Idiopathic CD4 lymphocytopenia (ICL) was first defined in 1992 by the US Centers for Disease Control and Prevention (CDC) as the repeated presence of a CD4+ count fewer than 300 cells per cubic millimeter or less than 20% of total T cells with no evidence of human immunodeficiency virus (HIV) infection and no condition that might be depressed CD4+ count. Most of our knowledge about ICL is based on scattered case reports because of the rarity of this condition. In this paper, we report a case of panuveitis in ICL.

**Methods:** Case report.

**Results:** A 46-year-old female was diagnosed with bilateral panuveitis. The panuveitis was complicated with exudative retinal detachment. Laboratory findings were low for CD4+ counts (49 cells/ $\mu$ L) and nonreactive for HIV antibody test. Laboratory test for TORCH was positive for chronic infection. The disease progressed from neuroretinitis to panuveitis in 3 months. She received gancyclovir the first time she was admitted to RSUP. Steroid was given locally to control the inflammation with close monitoring for complications. The symptoms were improved following increased CD4+ counts 5 months later.

**Conclusions:** Idiopathic CD4+ lymphocytopenia is a rare disease. Cases were reported from all over the world, with no apparent predilection to 1 geographical area. Most patients were diagnosed upon development of opportunistic infection without the presence of identifiable underlying immunosuppressed status. Treatment was given to control complications from the immunosuppressed condition.

### Clinical Presentation and Outcomes of Endogenous Endophthalmitis in an Indian Population at a Tertiary Care Hospital: Role of Newer Intravitreal Antibiotics in Management of Resistant Cases

First Author: Lakshmi **KRUPA**

Co-Author(s): Himabindu **ADUSUMILLI**, Nitin **SHETTY**

**Purpose:** Endogenous endophthalmitis (EE) is a sight-threatening emergency and its clinical presentation and etiology are often multifactorial. We describe newer management protocols and visual outcomes of EE.

**Methods:** Prospective case series. A total of 14 eyes of 10 patients presenting with EE from January 2016 to June 2017 were included. Data was collected in a standardized manner. Outcome measures included demographic information, visual acuity, microbial profiles, response to conventional and newer antibiotics, and vitrectomy rate.

**Results:** In 14 eyes of 10 patients of EE, mean





age was 53.6 years (range, 10-77 years); 80% were male. Presenting visual acuities ranged from no light perception (NPL; 5 eyes) and counting fingers (CF) at 2 meters to perception of light (PL+) in 9 eyes. Unilateral involvement was noted in 60% with bilateral involvement in 40%. Identifiable systemic risk factors were present in 80%, with the majority related to uncontrolled diabetes/hypertension and end-stage renal disease with septicemia. One child had infective endocarditis. An 80% blood culture positivity rate was recorded. Vitrectomy with intravitreal antibiotics in 42.8% (6 eyes) and only intravitreal antibiotics in 42.8% (6 eyes) was recorded. Newer intravitreal antibiotics (linezolid/piperacillin) and newer antifungal (voriconazole) were used in the management of 3 patients (42.8%). Final Snellen acuities ranged from 6/18 to NPL. The above management was followed by topical steroids/intensive antibiotics. Blood culture showed *Staphylococcus aureus* in 5 cases, *Streptococcus dysgalactiae* in 1 case, *Klebsiella* in 2 cases, *Escherichia coli* in 1 case, *Candida* in 1 case, and pus culture from foot showed coagulase-negative *Staphylococcus* in 1 case. One patient had intracranial spread of infection up to optic chiasm.

**Conclusions:** EE is a serious ocular condition and has varied etiology. Visual outcomes are often poor, and delayed diagnosis may exacerbate poor visual prognosis. Association between microbial isolate and risk factors for central line, diabetes, and liver abscess were noted. Newer antibiotics seem to show resolution of subretinal abscess in patients not responding to conventional lines of treatment.

### Clinical Presentations and Multimodal Imaging in Ocular Syphilis

First Author: Mudit **TYAGI**

Co-Author(s): Soumyava **BASU**, Avinash **PATHENGAY**, Rajeev R **REDDY**

**Purpose:** To describe the clinical presentations along with imaging features of ocular syphilis.

**Methods:** A retrospective, noncomparative chart review of 5 patients with active ocular

syphilis seen at a tertiary care hospital in South India from 2015-2017. Positive serologic tests supported the diagnosis in all patients. Color and red-free photographs along with fluorescein angiography (FA), indocyanine green angiography (ICGA), optical coherence tomography (OCT), and fundus autofluorescence were performed.

**Results:** Ocular involvement was bilateral in all 5 patients. One patient was positive for human immunodeficiency virus. Vitreous inflammation was evident in 3 patients. In 4 patients, posterior segment examination in the involved eyes revealed yellowish, placoid, outer retinal lesion. Fluorescein angiography showed progressive hyperfluorescence in the area of the lesion, often with scattered focal hypofluorescence or leopard spotting. Multiple elevated, creamy, yellow superficial retinal infiltrates overlying ground glass retinitis were noted in 4 cases. Spectral domain optical coherence tomography of the lesions revealed loss of the photoreceptor inner segment-outer segment junction layer along with mild choroidal infiltration. Treponema pallidum hemagglutination assay or TPHA is a better serological test for confirming the diagnosis of ocular syphilis as it has a higher specificity compared to VDRL.

**Conclusions:** The clinical findings of placoid chorioretinitis or retinitis with superficial retinal precipitates or ground glass retinitis along with leopard spot changes can be appreciated with fundus autofluorescence as well as on FA and ICGA. OCT is a valuable investigation in assessing photoreceptor damage in cases of ocular syphilis.

### Clinicoetiological Presentation of Posterior Uveitis in Bangladesh

First Author: Pankaj **ROY**

**Purpose:** To find out the cause of unexplained vision loss in patients attending the uvea and retina clinic and to raise interest in the causation of posterior uveitis by mycobacterium tuberculosis (MT).





**Methods:** This was a prospective case control study conducted from July 2012 to December 2016. A total of 98 posterior uveitis patients of unknown etiology were included in this study. Sixty patients who were MT positive (>15 mm) and received antituberculosis (anti-TB) drugs where no recurrences were found during the follow-up period were regarded as the study group and 38 patients who were MT negative were the control group of the study.

**Results:** A total of 60 patients (84 eyes) were affected. Vasculitis with or without retinal hemorrhage was seen in 20 eyes (24%), multifocal choroiditis in 18 eyes (21%), disseminated choroiditis in 17 eyes (20%), vitreous hemorrhage in 8 eyes (10%), single focal choroiditis in 6 eyes (7%), vasculitis with branch retinal vein occlusion (BRVO) in 5 eyes (6%), serpiginous choroiditis in 4 eyes (5%), vasculitis with tractional retinal detachment in 3 eyes (4%), and exudative detachment due to choroiditis in 3 eyes (4%).

**Conclusions:** Sixty patients (61%) of a group of 98 patients with primarily unexplained visual loss had chronic posterior uveitis and tuberculosis. Posterior uveitis presented as focal, multifocal, or diffuse areas of retinitis or choroiditis, with varying degrees of vitreous cellular activity and/or involvement of the retinal vasculature. Early diagnosis and treatment is needed to reduce mortality and morbidity due to posterior uveitis resulting from mycobacterium tuberculosis.

### Complications of Punctate Inner Choroidopathy

*First Author: Xiongze ZHANG*  
*Co-Author(s): Feng WEN*

**Purpose:** To investigate the complications of punctate inner choroidopathy (PIC).

**Methods:** Forty-two consecutive PIC patients (60 eyes) with at least 3 months of follow-up were reviewed.

**Results:** Among the 60 eyes with PIC, choroidal neovascularization developed in 28 eyes (47%) (23 of 42 patients, 55%) during the active phase

(25%) or the atrophic phase (75%). Stage III lesions occasionally invaded the inner retina, causing segmental retinal phlebitis in 2 eyes (3.3%). Late occult macular atrophy occurred in 4 eyes. The atrophy occurred between the foveal pit and a lesion with retinal hernia or between 2 adjacent lesions with retinal hernia. Within the atrophy, the inner retina became disorganized, and the photoreceptor layer was lost, but the retinal pigment epithelium (RPE) remained intact, making the atrophy undetectable by funduscopy and angiography.

**Conclusions:** Choroidal neovascularization is a common complication in PIC. Complications of PIC are closely related to the progression of PIC lesions.

### Cytokine Concentrations in Aqueous Humor of Eyes With Uveal Melanoma

*First Author: Jing FENG*  
*Co-Author(s): Yong CHENG, Jianhong LIANG*

**Purpose:** To investigate the aqueous concentrations of angiogenic, inflammatory, and chemotactic cytokines in eyes with uveal melanoma.

**Methods:** This clinical comparative study included a study group of 38 patients with uveal melanoma and a control group of 22 patients undergoing cataract surgery. Aqueous humor samples were assessed for interleukin 6 and 8 (IL-6 and IL-8, respectively), interferon-inducible protein-10 (IP-10), placental growth factor 1 (PIGF1), regulated on activation normal T cell expressed and secreted (RANTES), monocyte chemoattractant protein 1 (MCP1), nerve growth factor-beta (NGF- $\beta$ ), epidermal growth factor (EGF), basic fibroblast growth factor (bFGF), and vascular endothelial growth factor A (VEGF-A) by multiplex bead assay.

**Results:** In the study group as compared with the control group, significantly higher concentrations were measured for IL-6 ( $P = 0.006$ ), IL-8 ( $P = 0.018$ ), IP-10 ( $P = 0.004$ ), RANTES ( $P = 0.008$ ), MCP1 ( $P = 0.02$ ), NGF- $\beta$  ( $P = 0.013$ ), EGF ( $P < 0.001$ ), PIGF1 ( $P = 0.01$ ), bFGF ( $P = 0.016$ ), and VEGF-A ( $P = 0.017$ ).



**Conclusions:** Numerous cytokines are associated with the presence and the amount of uveal melanoma.

### Free-Floating Vitreous Cyst in an Adult Male

First Author: Jing HE

Co-Author(s): Mingying LAI

**Purpose:** To report an unusual case of solitary unilateral vitreous cyst in an adult male.

**Methods:** A complete ocular examination, fundus photography, B-scan ultrasound, and fluorescence fundus angiography were performed in this patient. Besides, the blood serology tests were examined for *Toxoplasma gondii*, *Toxocara canis*, cysticercosis, and *Echinococcus*.

**Results:** The patient (an 80-year-old man) reported a slow visual deterioration in both eyes over the past 2 years. He was referred to our hospital because of cataract in both eyes. Slit-lamp examination showed nuclear cataract in both eyes, and anterior segments were otherwise normal. Fundus examination performed with 90 diopter (D) lens was unremarkable in the left eye, while in the right eye a single oval cyst was identified floating freely in the vitreous. B-scan ultrasound revealed a round-shaped cyst that was localized at the posterior vitreous. Fluorescence fundus angiography showed a clear-edged hypofluorescence. Simultaneously, the results of blood serology for parasites were negative. After all examinations, a diagnosis of congenital vitreous cyst was made.

**Conclusions:** Vitreous cysts are rare clinical findings. They can be observed in normal eyes or associated with previous eye pathology. When the vitreous cyst floats into the visual axis area, it can cause blurred vision or disturb visual function. A prompt clinical examination is necessary for differentiating this rare condition.

### Hemorrhagic Occlusive Retinal Vasculitis After Cataract Surgery

First Author: Özlem TÖK

Co-Author(s): Lütfi SEYREK, Levent TÖK, Çiğdem YAŞAR

**Purpose:** To report a case of hemorrhagic occlusive retinal vasculitis (HORV) after uncomplicated cataract surgery in a patient with leukocytoclastic vasculitis (LCV).

**Methods:** An 80-year-old patient's right eye underwent an uncomplicated phacoemulsification cataract extraction under topical anesthesia. The patient had painless visual loss in the right eye 2 days after surgery.

**Results:** On examination, visual acuity (VA) was hand movements. Slit lamp examination revealed mild corneal edema, hypopyon, and pupillary membrane. There was no eyelid edema or conjunctival chemosis. Fundus could not be seen clearly. It was noticed that the patient did not use topical dexamethasone treatment after surgery. During the etiological investigation, it was found that the patient was followed up for 2 years with the diagnosis of LCV in the department of rheumatology. During vitrectomy, we found vitreous condensation, the retinal vascular structures were empty, tangential and axial traction in the posterior pole, macular migration to the optic nerve, diffuse preretinal hemorrhages, and snowball inflammatory deposits. The membranes were peeled off and a silicone tamponade was placed with 360-degree laser photocoagulation. VA was hand movements in the right eye postoperatively.

**Conclusions:** LCV is an immune complex mediated small-vessel vasculitis. Ocular manifestations are rare and there have been reports suggesting associations of iritis, episcleritis, retinitis, and panuveitis. We did not know that the patient was followed up with the diagnosis of LCV before cataract surgery. If we had used intensive steroid treatment postoperatively or preoperatively, could we have prevented HORV in our patient with leukocytoclastic vasculitis?



### Post-Cataract Surgery Cluster Endophthalmitis Caused by Multidrug-Resistant *Pseudomonas aeruginosa*: A Retrospective Analysis

First Author: Pritam **BAWANKAR**

Co-Author(s): Diva **MISRA**, Ronel **SOIBAM**

**Purpose:** The purpose of this study was to investigate an outbreak of multidrug-resistant (MDR) *Pseudomonas aeruginosa* endophthalmitis in 13 patients after cataract surgery and to emphasize the importance of clinical profile, risk analysis, and treatment outcomes.

**Methods:** The present study was a hospital-based retrospective, interventional, case series. Thirteen patients who had small-incision cataract surgery with intraocular lens implantation developed acute postoperative endophthalmitis. The anterior chamber taps, vitreous aspirates, and environmental surveillance specimens were inoculated for culture. Antibiotic susceptibility testing was performed by agar diffusion method.

**Results:** *P. aeruginosa* was isolated from all 13 eyes with acute postoperative endophthalmitis and Trypan blue solution used for the surgery. Sensitivity tests revealed that all *P. aeruginosa* eye isolates had an identical MDR susceptibility profile and were found susceptible to only imipenem. Despite the prompt use of intravitreal antibiotics and early vitrectomy with intraocular lens explantation in some patients, the outcome was poor in at least 50% of cases (evisceration of 4 eyes, phthisis of 2 eyes, retinal and choroidal detachment with extensive proliferative vitreoretinopathy in 1 eye) and a moderate degree of improvement was observed in 6 eyes at the last control visit.

**Conclusions:** Postoperative endophthalmitis caused by *P. aeruginosa* is often associated with a poor visual prognosis despite prompt treatment with intravitreal antibiotics. The detection of multidrug-resistant isolates is a serious problem, jeopardizing an appropriate choice of treatment. Susceptibility to imipenem suggests that this antibiotic may be a potential

candidate for the treatment of ocular infections caused by multidrug-resistant *P. aeruginosa*.

### Recombinant Tissue Plasminogen Activator in Recalcitrant Anterior Uveitis: Case Series

First Author: Sylves **PATRICK**

Co-Author(s): Liza Sharmini **AHMAD TAJUDIN**, Zunaina **EMBONG**, Hui Tze **CHAN**, Wan Hazabbah **WAN HITAM**, Azhany **YAAKUB**

**Purpose:** To report the effect of intracameral recombinant tissue plasminogen activator (rtPA) injection in reducing postoperative inflammation in recalcitrant anterior uveitis.

**Methods:** Case 1: A 40-year-old woman presented with bilateral redness and reduction of vision for 2 weeks. There was bilateral anterior uveitis, vasculitis, retinitis, and optic disc swelling. *Bartonella henselae* serology was positive. Systemic antibiotic and corticosteroid were commenced. She was treated with long-term systemic steroid for persistent anterior uveitis. Case 2: A 30-year-old healthy man presented with bilateral painless red eye with reduced vision, headache, and tinnitus for 2 weeks. There was bilateral granulomatous inflammation with vitritis, choroiditis, retinitis, and hyperemic optic disc. He was diagnosed as Vogt-Koyanagi-Harada (VKH) disease and treated with systemic corticosteroid. Both cases developed secondary cataract and glaucoma that necessitated surgical intervention. However, persistent inflammation led to formation of thick membrane anterior to intraocular lenses. Membrane was removed surgically and injection of intracameral rtPA 25 µg was given.

**Results:** There was resolution of persistent inflammation and significant improvement in visual acuity within a week of intracameral rtPA injection.

**Conclusions:** Intracameral rtPA is beneficial in patients with recalcitrant anterior uveitis.



### Unexpected Course of Events in a Patient Treated With Dexamethasone Implant

First Author: Meher Tej **RAVULA**  
Co-Author(s): Ramya **METLA**, Hasika **RAVULA**,  
Srirama Chandra Murthy **RAVULA**

**Purpose:** To report a patient with recurrent macular edema due to hemicentral retinal vein occlusion treated with intravitreal Ozurdex implant who developed acute endophthalmitis.

**Methods:** A patient previously treated with multiple bevacizumab injections who received intravitreal Ozurdex implant for recurring macular edema developed acute endophthalmitis following the injection. An immediate 23-gauge pars plana vitrectomy with intravitreal antibiotics was performed. However, hazy media did not allow removal of Ozurdex implant. A vitreous biopsy was sent for culture and sensitivity.

**Results:** The patient gradually improved clinically and endophthalmitis resolved in due course. The culture was positive for *Staphylococcus epidermidis*. After the media cleared up, the Ozurdex implant was visible in the vitreous cavity. However, the patient progressed to mature cataract quickly. Five months after resolution of endophthalmitis, the patient underwent cataract surgery and regained decent visual acuity. However, macular edema recurred.

**Conclusions:** Post-intravitreal injection endophthalmitis is on the rise due to remarkable increase in the number of intravitreal injections being performed each year. There are only 3 reported cases of endophthalmitis after Ozurdex implant injection in the literature. In all 3 reported cases, the implant was removed via pars plana vitrectomy. Though it is ideal to remove the implant, in this case the implant was retained and the endophthalmitis still resolved, suggesting that the implant harboring the microorganisms may not be the cause of endophthalmitis every time. Preoperative lid and conjunctival examination is of prime importance and any signs of meibomitis or other infections should

be treated prior to injection procedure.

### Retina (Medical)

### A Case of Cystoid Macular Edema Caused by Nanoparticle Albumin-Bound Paclitaxel

First Author: Yuri **HANZAWA**  
Co-Author(s): Hideo **KOHNO**, Masaomi **KUBOTA**,  
Tadashi **NAKANO**, Akira **WATANABE**, Tomoyuki  
**WATANABE**

**Purpose:** To report a case of cystoid macular edema (CME) that occurred during treatment with nanoparticle albumin-bound paclitaxel (Abraxane).

**Methods:** Retrospectively, records were reviewed for visual acuity and CME as assessed by optical coherence tomography.

**Results:** The patient was a 63-year-old Japanese man who received treatment with Abraxane and gemcitabine for pancreatic cancer. Approximately 5 months after beginning chemotherapy, CME was observed in both eyes. Visual acuity decreased to 0.4 in the right eye and 0.3 in the left eye. The patient was started on betamethasone eye drops, but there was no improvement in central retinal thickness (CRT) or visual acuity. Hence, administration of Abraxane was discontinued. Within 2 months, a reduction in CRT and improvement of CME was observed. Visual acuity improved to 0.7 in the right eye and 1.0 in the left eye.

**Conclusions:** Abraxane is easy to use and is likely to be widely adopted in the treatment of malignant tumors. However, it may cause a reduction in visual acuity due to CME. Intravitreal and subtenon triamcinolone acetate injections are reported to have a certain level of efficacy in the treatment of CME caused by Abraxane; but considering the benefits and risks of these treatments, we selected betamethasone eye drops for this case, which did not show a sufficient level of efficacy. In this case, we believe that the discontinuation of Abraxane led to the improvement of CME. Based on our present



knowledge, if CME occurs, discontinuation of Abraxane is believed to be the most effective treatment option.

### Atypical Presentation of Idiopathic Intracranial Hypertension: Severe Peripapillary Exudation With Macular Edema

First Author: Lakshmi **KRUPA**

Co-Author(s): Himabindu **ADUSUMILLI**, Nitin S **SHETTY**

**Purpose:** Idiopathic intracranial hypertension (IIH) is a headache syndrome characterized by raised cerebrospinal fluid pressure in the absence of any cranial mass lesion or ventricular dilatation, normal spinal fluid composition, usually normal findings on neurological examination except for papilledema, sometimes VI nerve palsy, and normal level of consciousness. Prompt diagnosis and treatment is needed to prevent potentially permanent visual loss.

**Methods:** A 41-year-old woman presented with blurred vision for 2 weeks associated with headache of 2-3 months' duration. On examination, she was conscious and well oriented. Her vitals along with higher mental functions were normal. Her systemic examinations were normal with no evidence of focal neurological deficit. Ocular examination revealed bilateral papilledema with peripapillary exudation with macular edema. Hematology and biochemistry were within normal limits. Magnetic resonance imaging (MRI) of the brain and orbits revealed no abnormality. MR angiogram and MR venogram were normal. Cerebrospinal fluid (CSF) study at the time of admission only revealed high CSF opening pressure (290 mm of H<sub>2</sub>O). With the exception of a high opening pressure, the patient's CSF analysis was normal. She was diagnosed with idiopathic intracranial hypertension and managed with acetazolamide.

**Results:** The patient recovered with oral acetazolamide treatment and has been under follow-up; after 3 months of treatment, her visual acuity improved with resolution of headache.

**Conclusions:** Idiopathic intracranial hypertension is rare and potentially vision-threatening but prompt diagnosis and treatment especially in cases with atypical presentation like our patient will prevent potentially permanent visual loss.

### Better Prognosis for Eyes With Preserved Foveal Depression After Anti-Vascular Endothelial Growth Factor Therapy for Macular Edema Secondary to Branch Retinal Vein Occlusion

First Author: Shunsuke **YASUDA**

Co-Author(s): Yasuki **ITO**, Shuta **KITAGAWA**, Hiroko **TERASAKI**, Shinji **UENO**

**Purpose:** To determine the prognosis of eyes with branch retinal vein occlusion (BRVO) that had a preserved foveal depression at baseline and were treated by intravitreal ranibizumab (IVR) or aflibercept (IVA) injections.

**Methods:** We reviewed the medical records of 41 eyes of 41 consecutive treatment-naive patients who received IVR (24 eyes) or IVA (17 eyes) to treat macular edema (ME) due to BRVO. The same drug (ranibizumab or aflibercept) was used to treat the same eye throughout the study. Eyes were classified by the pre-IVR/IVA presence or absence of a foveal depression. A foveal depression was defined as a central foveal thickness that was <50  $\mu$ m thinner than the average thickness at 200  $\mu$ m temporal and nasal to the central fovea. The characteristics of the 2 groups were compared.

**Results:** Thirteen of 41 eyes had a preserved foveal depression before treatment. The mean number of injections within 12 months after the initial IVR/IVA was significantly fewer ( $P = 0.001$ ) in eyes with foveal depression ( $1.7 \pm 0.8$ ) than in eyes without foveal depression ( $3.3 \pm 1.5$ ). The mean best-corrected visual acuity at 12 months after the initial IVR/IVA was significantly better ( $P = 0.002$ ) in eyes with foveal depression [ $0.06 \pm 0.10$  logarithm of the minimum angle of resolution (logMAR) units] than in eyes without foveal depression ( $0.23 \pm 0.18$  logMAR units).

**Conclusions:** These results indicate that





one of the characteristics of eyes with good treatment outcome after IVR/IVA treatment is the presence of a preserved foveal depression at baseline in eyes with BRVO.

### Bilateral CMV Retinitis With Underlying Acute Lymphoblastic Leukemia: A Treatment Conundrum

First Author: Logesvaran **MURUGAN**

Co-Author(s): Umi Kalthum **MD NOH**, Aida Zairani **MOHD ZAHIDIN**, Wan Haslina **WAN ABDUL HALIM**

**Purpose:** To discuss the challenges in managing a case of cytomegalovirus (CMV) retinitis in an adolescent immunocompromised patient with underlying acute lymphoblastic leukemia (ALL).

**Methods:** Case report.

**Results:** A 13-year-old Malay boy with underlying B-cell ALL on chemotherapy presented with right eye painless, progressive blurring of vision. On examination, the visual acuity was 6/9 in the right eye and 6/6 in the left eye. There was no relative afferent pupillary defect and the anterior segment examination was unremarkable. Bilateral fundus revealed necrotizing retinitis with focal areas of hemorrhages within, consistent with active CMV retinitis. Subsequently he was given 3 doses of intravenous ganciclovir and promptly converted to oral valganciclovir induction phase. This resulted in improvement of the lesion. Nevertheless, valganciclovir had to be withheld prematurely following development of neutropenia. Systemic therapy was abandoned, chemotherapy was withheld, and local intravitreal (IVT) ganciclovir initiated. The IVT ganciclovir, however, must be given under general anesthesia and this posed a risk for the patient as it needs to be given for many months as the patient would be immunosuppressed due to chemotherapy for almost 1 year. Attempts to restart systemic therapy also met with the setback of neutropenia, which was also potentiated by the chemotherapy. The risk of injection, particularly endophthalmitis, harbors the risk of blindness.

**Conclusions:** This case highlights the difficulty

in managing CMV retinitis in young patients who cannot tolerate systemic antivirals and alternative IVT injection has to be done under general anesthesia. It is paramount to strike a balance between the risk of general anesthesia administered chronically and the benefit of visual recovery in such cases.

### Bilateral Central Retinal Vein Occlusion in Hyperhomocysteinemia: A Case Report

First Author: Nazmun **NAHAR**

Co-Author(s): Md Nowroz **BAHAR**, Mamunur Rashid **CHOWDHURY**, Fahim **HOSSAIN**, Abdul Mahid **KHAN**, Farhana **YASMIN**

**Purpose:** To report a case of bilateral central retinal vein occlusion (CRVO) due to increased serum homocysteine level.

**Methods:** Case report.

**Results:** A 35-year-old male patient presented with sudden painless loss of vision for 2 weeks in the right eye (OD). He had poor visual acuity in the left eye (OS) for 2 years. Visual acuity was 6/36 OD and 3/60 OS. Anterior segment examination was unremarkable except sluggish pupillary reactions in OS. Intraocular pressures were 14 and 16 mm Hg OD and OS, respectively. Fundus examination of OD revealed all findings of recent-onset central retinal vein occlusion. Fundus examination of OS showed signs of old CRVO with pigmentary changes at the macula. Optical coherence tomography (OCT) of OD showed macular edema with macular thickness of 665  $\mu\text{m}$  and OS showed atrophy at macula. The patient was not diabetic and not hypertensive. Along with routine laboratory investigations tests for thrombophilic disorder including homocysteine level were advised. All results were normal except serum homocysteine level. The serum homocysteine level was found to be 36  $\text{mlmol/l}$  (normal range, 0–12). He was treated with 2 doses of injection of Lucentis for macular edema, consulted with an internist, and folic acid treatment was started. Homocysteine level was normalized and visual acuity increased to 6/6 at the sixth month follow-up visit with resolution of fundus findings.



**Conclusions:** Retinal vascular occlusions in youth should be investigated throughout for any disease causing thrombophilia. We would like to stress the investigation for homocystinemia as a predisposing condition for the bilateral occlusion of central retinal veins in the absence of other risk factors.

### Change of Retinal Pigment Epithelial Atrophy After Anti-Vascular Endothelial Growth Factor Treatment in Exudative Age-Related Macular Degeneration

First Author: Seung-Jun LEE

**Purpose:** This study aimed to investigate the quantitative changes of retinal pigment epithelial (RPE) atrophy during a 24-month follow-up period of anti-vascular endothelial growth factor (VEGF) for exudative age-related macular degeneration (AMD).

**Methods:** This was a retrospective study. Sixty-five eyes of 62 consecutive patients with naive exudative AMD who had received treatment with anti-VEGF therapy and were followed for more than 24 months were enrolled. All patients received 3 initial monthly injections of anti-VEGF (ranibizumab or bevacizumab), followed by pro re nata or treat-and-extend protocol. Color fundus images, optical coherence tomography, and fundus autofluorescence were evaluated for RPE atrophy. Multiple regression analysis was performed to investigate the predictive factors found during univariate analysis to identify an association with increased RPE atrophic areas.

**Results:** The mean number of anti-VEGF treatments was 9.18. RPE atrophic area was  $1.293 \pm 1.298 \text{ mm}^2$  at baseline and enlarged to  $2.394 \pm 1.940 \text{ mm}^2$  after 24 months, which differed significantly ( $P = 0.001$ ). Multiple regression analysis revealed that larger areas of RPE atrophy at month 4 and greater numbers of anti-VEGF treatments were associated with increased RPE atrophic areas.

**Conclusions:** RPE atrophy progresses in eyes with exudative AMD during anti-VEGF treatment. Larger areas of RPE atrophy at

month 4 and greater numbers of anti-VEGF injections were associated with an increased risk of progression of RPE atrophy following treatment. These findings may be useful to clinicians using intravitreal anti-VEGF for the treatment of exudative AMD, both for selecting an appropriate treatment plan and for predicting the progression of RPE atrophy.

### Choroidal Melanoma: Experience From a Tertiary Referral Center in Malaysia

First Author: Li Ying LONG

Co-Author(s): Roslin Azni ABDUL AZIZ

**Purpose:** Choroidal melanoma is known as the most common primary intraocular malignancy in adults. Nevertheless, it is more commonly found in Caucasians and rarely found in the Malaysian population. We present 8 cases of choroidal melanoma referred to the medical retinal clinic in a tertiary center from the year 2012 to 2016.

**Methods:** Retrospective case series.

**Results:** There were 7 females and 1 male with a mean age of 53.9 years old. Five patients were Chinese and 3 were Malay. The presenting complaints were visual field defect ( $n = 3$ ), distorted vision ( $n = 2$ ), photopsia ( $n = 2$ ), and decreased vision ( $n = 1$ ). The tumor thickness ranged from 3.00 to 13.94 mm (mean, 8.93 mm). One case had exudative retinal detachment while the remaining had adjacent subretinal fluid. Three patients had undergone globe-preserving therapy (plaque brachytherapy and stereotactic radiotherapy) while the remaining had undergone enucleation or exenteration. The histopathological examinations showed 3 cases of spindle B cells, 1 with epithelioid cells, and 1 with mixed features. One patient died due to tumor recurrence and complications of multiple distant metastasis while the rest were well under regular follow-up.

**Conclusions:** Although choroidal melanoma is very rare among the Malaysian population, it is a crucial diagnosis to make in view of its metastatic risks. Early presentation and



diagnosis of choroidal melanoma is significant to save lives.

### Clinical and Spectral Domain Optical Coherence Tomography Features of Idiopathic Juxtafoveal Retinal Telangiectasia

First Author: Mahantesh **BIRAJDAR**

Co-Author(s): Kiran **CHANDRAN**, Chetan **CHHIKARA**, Yogish **KAMATH**, Shailaja **SHENOY**, Akash **TANDON**

**Purpose:** To describe the spectral domain optical coherence tomography (SD-OCT) features of idiopathic juxtafoveal telangiectasia (IJT) and to correlate the OCT features with visual acuity.

**Methods:** Retrospective analysis of the medical records of 22 eyes of 11 patients with the diagnosis of IJT was done. Data regarding age, gender, presence of diabetes mellitus, and best corrected visual acuity (BCVA) in each eye was collected. Fundus photographs, fundus fluorescein angiography (FFA), and OCT images were analyzed. Spearman coefficient of rank correlation ( $r^2$ ) was determined between BCVA and central foveal thickness. Logistic regression analysis was performed to see the association between inner segment-outer segment (IS-OS) disruption and BCVA. OCT features analyzed included central foveal thickness, IS-OS disruption in the foveal region, IS-OS disruption in the parafoveal region, foveal cystoid, parafoveal cystoid, internal limiting membrane (ILM) druse, intraretinal blood vessels, retinal pigment epithelium (RPE) hyperplasia, and presence of choroidal neovascular membrane (CNVM).

**Results:** We studied 22 eyes of 11 patients. The average age was 61.8 years, and male:female ratio was 5:6. All the patients had a history of diabetes mellitus but 3 patients had diabetic retinopathy changes. Mean central foveal thickness was 217.3  $\mu\text{m}$ . The standard deviation was 21.38. The range was 153-283  $\mu\text{m}$ . BCVA ranged from 6/6 to 6/60, N6 to N36. Spearman coefficient of rank correlation ( $r^2$ ) was determined between BCVA and central foveal thickness: "r" value was 0.73, which signified a high correlation with marked relationship.

**Conclusions:** SD-OCT is useful in the diagnosis of IJT. Loss of photoreceptor layer is associated with vision loss.

### Comparison of Central Retinal Thickness Measurements Between Two Commercial Spectral Domain Optical Coherence Tomography Machines

First Author: Harvey **UY**

Co-Author(s): Pik Sha **CHAN**, Paola **COJUANGCO**, Franz Marie **CRUZ**

**Purpose:** Optical coherence tomography (OCT) is now standard of care for retinal practices but the cost of the technology may be prohibitive. A recently introduced, low-cost OCT machine could increase access to this technology but its clinical validity has yet to be reported. The purpose of this study was to compare reader grading, central retinal thickness (CRT), and macular volume (MV) measurements obtained using high-end and low-end OCT machines.

**Methods:** Noninterventional, paired-observational study. One hundred normal and diseased eyes underwent imaging using 2 spectral domain OCT machines (CIRRUS 4000 and PRIMUS 200, Carl Zeiss Meditec, Jena, Germany). Central 6-mm macular scans were obtained using automated software. Main outcome measures were mean CRT, mean MV, and pairwise agreement frequency of image assessment as normal or abnormal.

**Results:** The mean (SD) CRT using the CIRRUS was 258.9 (58.2)  $\mu\text{m}$ ; the mean (SD) using the PRIMUS 200 was 257.8 (50.0)  $\mu\text{m}$  ( $P = 0.92$ ). The mean (SD) MV were 13.3 (27.7) and 13.3 (27.9)  $\mu\text{m}^3$ , respectively ( $P = 1.0$ ). Pairwise agreement frequency by a masked reader was 91%. Fisher exact test for masked reader grading was 0.6962.

**Conclusions:** Both machines yielded comparable measurements of CRT and MV. There was excellent pairwise agreement in classifying eyes as normal or abnormal. The lower-cost PRIMUS 200 has similar ability to measure relevant clinical parameters as the CIRRUS 4000.



## Correlation Between Visual Field Index and Structural Characteristics of the Retina and Choroid in Advanced Retinitis Pigmentosa

First Author: Gisung **SON**

Co-Author(s): Yoon Jeon **KIM**, Suhwan **LEE**, Young Hee **YOON**

**Purpose:** To compare the visual function and the structural characteristics of the retina and choroid in patients with advanced retinitis pigmentosa (RP).

**Methods:** A retrospective study was conducted including 291 eyes of 149 RP patients, who showed visual field (VF) constriction within the central 30-2 Humphrey VF chart. Spectral domain optical coherence tomography (SD-OCT) was used for measuring central retinal thickness (CRT), ellipsoid zone (EZ) length, and submacular choroidal thickness (SMChT). Quantitative correlation between visual field index (VFI) and best corrected visual acuity (BCVA), CRT, EZ length, and SMChT was assessed.

**Results:** Mean ( $\pm$ SD) age was 46.3 ( $\pm$ 15.5) years, and the mean ( $\pm$ SD) duration of illness was 60.7 ( $\pm$ 60.0) months. Mean ( $\pm$ SD) values at baseline were BCVA, 0.48 ( $\pm$ 0.75); VFI, 33.9 ( $\pm$ 25.4%); CRT, 182.7 ( $\pm$ 55.1  $\mu$ m); EZ length, 2433.0 ( $\pm$ 1419.7); and SMChT, 209.8 ( $\pm$ 62.3  $\mu$ m). Pearson correlation showed that BCVA and VFI showed a progressive worsening in association with age ( $r = 0.258$ ,  $P = 0.001$  and  $r = -0.314$ ,  $P < 0.001$ , respectively) or duration of disease ( $r = 0.307$ ,  $P < 0.001$  and  $r = -0.435$ ,  $P < 0.001$ , respectively). Not only BCVA but also VFI showed significant correlation with CRT ( $r = -0.505$ ,  $P < 0.001$  and  $r = 0.333$ ,  $P < 0.001$ , respectively) and EZ length ( $r = -0.290$ ,  $P < 0.001$  and  $r = 0.487$ ,  $P < 0.001$ , respectively). However, neither BCVA nor VFI was correlated with SMChT ( $r = -0.091$ ,  $P = 0.125$  and  $r = 0.088$ ,  $P = 0.139$ , respectively).

**Conclusions:** Among patients with advanced RP, VFI as well as BCVA were closely correlated with the degree of retinal structural changes such as CRT or EZ length. SMChT was decreased in all eyes, resulting in no significant

correlation with the degree of VFI.

## Cost-Effectiveness of Intravitreal Medications for Retinal Disease

First Author: Harvey **UY**

Co-Author(s): Annelisa **KOH**

**Purpose:** To determine the cost-effectiveness of different intravitreal medications for the treatment of common retinal diseases.

**Methods:** A meta-analysis of published randomized clinical trials was conducted to determine the visual acuity benefits of aflibercept, bevacizumab, dexamethasone, and ranibizumab for eyes with branch/central retinal vein occlusion (B/CRVO), diabetic macular edema (DME), and wet age-related macular degeneration (AMD). The cost of the drug from a published drug reference book was used in calculating the cost per letter gained (CPL). The main outcome measure was the lowest CPL per disease.

**Results:** For BRVO, the lowest CPL was USD 3.0 using triamcinolone acetonide 1 mg q3 months. For CRVO, the lowest CPL was USD 202 using intravitreal dexamethasone implant q6 months. For DME, the lowest CPL was USD 406 using dexamethasone implant q16 weeks. For nAMD 1-year treatment, the lowest CPL was USD 586 with aflibercept using a treat-and-extend regimen. The ratio of highest/lowest cost for 1 year of treatment was 4.4 in BRVO, 5.86 in CRVO, 2.27 in DME, and 3.48 in nAMD.

**Conclusions:** Several factors influence the cost of each letter of vision gained including the type of intravitreal medication, dosing regimen, and disease type. Cost-effectiveness and patient socioeconomic status should be considered when recommending treatment options.

## Demographic Features, Risk Factors, Clinical Patterns, and Angiographic Features in Newly Diagnosed Polypoidal Choroidal Vasculopathy in a Malaysian Tertiary Hospital

First Author: Sor Eann **TAN**

**Purpose:** To determine the demographic





features, clinical characteristics, and angiographic features of newly diagnosed polypoidal choroidal vasculopathy (PCV) in Malaysian patients.

**Methods:** A cross-sectional study was undertaken among 170 newly diagnosed PCV patients in a Malaysian tertiary hospital between June 2015 and September 2016. All patients underwent complete ophthalmic examination, fluorescein, and indocyanine green angiography (ICGA).

**Results:** A total of 170 patients (173 eyes) were newly diagnosed with PCV. The mean age of PCV was  $67.08 \pm 8.3$  years. PCV was more common in men (104, 61%) and unilaterally (149, 87.6%). Majority of newly diagnosed PCV patients comprised Chinese (98, 57.6%), followed by Malays (51, 30%) and Indians (21, 12.4%). The patients had systemic hypertension (82, 48.2%), diabetes mellitus (50, 28.8%), dyslipidemia (34, 20.0%), chronic kidney disease (9, 5.3%), and coronary artery disease (8, 4.7%). Colored funduscopy revealed 83 (48.3%) patients showed hemorrhagic retinal detachments (RD) and hemorrhagic pigment epithelial detachments (PED), 64 (37.2%) showed serous RD and serous PED, 17 (9.9%) massive submacular bleed, and 50 (28.9%) orange subretinal nodule. ICGA characteristics included nodular appearance stereoscopically (163, 94.2%), hypofluorescent halo (112, 64.7%), abnormal vascular network (146, 84.4%), and pulsation of the polyps (4, 2.3%). The most common optical coherence tomography findings were hemorrhagic PED with subretinal fluid (100, 57.8%) and serous PED with subretinal fluid (73, 42.2%).

**Conclusions:** Similar to other Asian populations, the disease occurred more commonly in the older population, men, and was usually unilateral. Majority of patients comprised individuals of Chinese descent. Majority of patients presented with hemorrhagic pattern, followed by exudative pattern.

### Exudate Quantification in Color Retinal Images for Diabetic Retinopathy

*First Author: Shaochun CHEN*

*Co-Author(s): Te-I CHANG, Chung-Ming LO, Shu-Min TSAO*

**Purpose:** A computer-aided diagnosis (CAD) system was proposed to automatically quantify and detect exudates in color retinal images for screening of diabetic retinopathy.

**Methods:** In total, 47 images containing exudates and 35 normal images comprised the image database. The relative brightness in a local area was proposed to detect potential exudates in this study. Consequently, similar structures such as vessels and the optic disc were first detected and removed. The subsequent pixel-wise standard deviation was used for tissue segmentation. Extracting quantitative regional features from the segmented candidates and combining them in a logistic regression classifier comprised the CAD system.

**Results:** The proposed 6 regional features were evaluated to be significant ( $P < 0.001$ ) in distinguishing between exudate images and normal images using the Mann-Whitney U test. As a diagnostic result, the CAD system achieved an accuracy of 83%, a sensitivity of 85%, a specificity of 80%, a positive predictive value of 85%, and a negative predictive value of 80%.

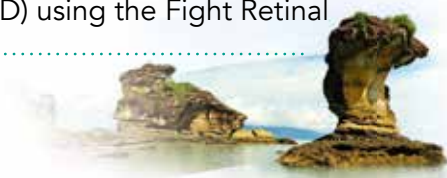**Conclusions:** Automatic exudate detection in fundal photographs has the potential to assist ophthalmologists in screening examinations.

### First Experience With Fight Retinal Blindness System for Real-World Outcomes of Exudative Age-Related Macular Degeneration in a Predominately Asian Population

*First Author: Kelvin TEO*

*Co-Author(s): Chui Ming Gemmy CHEUNG, Mark GILLIES*

**Purpose:** We report the real-world 12-month treatment outcomes of 135 treatment-naïve eyes with exudative age-related macular degeneration (wet AMD) using the Fight Retinal





Blindness (FRB) system, which previously reported outcomes in Australian cohorts.

**Methods:** Index visit characteristics including lesion type, greatest linear dimension (GLD), activity, visual acuity (VA), as well as treatments and outcomes (VA, lesion activity status), were recorded prospectively using the FRB system.

**Results:** Mean change in 12-month VA was 7.5 (CI = 2.15-12.6) letters, with a mean of 5.3 (3-8) injections. Time to lesion inactivity was 80.5 days (CI = 64-120). A total of 56.2% of the eyes were diagnosed with polypoidal choroidal vasculopathy (PCV). Significant baseline difference was the age of onset between PCV and typical AMD (tAMD) ( $69.1 \pm 9.5$  versus  $74.3 \pm 7.9$  years,  $P < 0.001$ ) and no difference in other characteristics such as gender (PCV: females, 50% vs tAMD: 32%,  $P = 0.057$ ), baseline VA (PCV: 45.928.1 vs tAMD: 45.124 letters,  $P = 0.872$ ), and GLD [PCV: 3513 nm (CI = 1733-5197) vs tAMD: 2988 nm (CI = 2038-4055)]. Twelve-month comparisons showed PCV eyes required fewer injections [4.5 (3-6) vs tAMD 6 (4-8),  $P = 0.003$ ] and median VA was significantly better in PCV [PCV: 69.0 (CI = 40.2-79.2) vs 57.0 (CI = 33.0-73.0) letters,  $P = 0.043$ ]. Time to inactivity showed no difference [PCV: 71 (CI = 64-98) vs 90 (CI = 70-120) days,  $P = 0.532$ ]. PCV eyes with anti-vascular endothelial growth factor (anti-VEGF) and photodynamic therapy ( $n = 36$ ) versus anti-VEGF monotherapy ( $n = 40$ ) showed no difference in baseline characteristics and 12-month outcomes: change in VA [combination: 10.5 (CI = 0.8-28.5) vs monotherapy: 5.5 (0.0-15.0) letters,  $P = 0.118$ ], number of injections [combination: 5 (3-6.2) vs monotherapy: 4 (3-6),  $P = 0.127$ ], and time to inactivity [combination: 87 (56-112) days vs monotherapy: 85 (70-203) days,  $P = 0.131$ ].

**Conclusions:** This reports the first cohort of real-world outcomes using the FRB system in Singapore. There was a difference in functional outcome between PCV and tAMD, and combination or monotherapy in PCV treatment can achieve reasonably good outcomes for either subtype.

## Foveal Avascular Zone Dimensions and Reliability in Healthy Korean Eyes Using OCTA

*First Author: Do-Gyun KIM*

*Co-Author(s): Han SONG, Ji Ho YANG*

**Purpose:** To evaluate foveal avascular zone (FAZ) dimensions and circularity in healthy eyes of Koreans and the reliability of optical coherence tomography angiography (OCTA).

**Methods:** Sixty-one eyes of 36 healthy Koreans were investigated using NIDEK RS-3000 with prototype OCTA. Each volunteer was separately examined 2 consecutive times by the 2 examiners with 1-hour interval. The FAZ dimension in superficial and deep capillary plexuses (SCP & DCP) were analyzed with built-in software. The circularity was calculated by Image J software. Repeatability and reproducibility were evaluated by calculating intraclass correlation coefficient (ICC).

**Results:** The mean dimension ( $\text{mm}^2$ ) and circularity (%) were  $0.38 \pm 0.11$  and  $0.87 \pm 0.40$  in SCP and  $0.50 \pm 0.13$  and  $0.90 \pm 0.21$  in DCP. The repeatability of the FAZ dimension was high (ICC of 0.994 to 0.996 in SCP and 0.984 to 0.991 in DCP). However, the repeatability of circularity was relatively low (ICC of 0.105 to 0.501). The mean difference in dimension between the 2 examiners was -0.01 to 0.003 and ICC was 0.956 to 0.988 and in circularity was -0.03 to -0.02 and ICC values were 0.048 to 0.239. The FAZ dimension was significantly correlated with central macular thickness (CMT) (SCP:  $P = 0.00$ ; DCP:  $P = 0.00$ ) and larger in females than in males (SCP:  $P = 0.00$ ; DCP:  $P = 0.04$ ).

**Conclusions:** Our study provides a standard value of mean FAZ dimension and circularity using OCTA in healthy Korean eyes. OCTA produces highly reliable FAZ dimension. OCTA can become a valuable tool for diagnosing retinal disease and the need for careful follow-up.





### Identification of Eyes at Risk for Severe Retinopathy of Prematurity by Third Year Ophthalmology Residents in a Tertiary Hospital

First Author: Eleonore **IGUBAN**

**Purpose:** The aim of the present study is to determine the efficacy of third year ophthalmology residents from a tertiary hospital in performing preliminary retinal examination to identify eyes at risk for retinopathy of prematurity (ROP) on the basis of retinal fundus findings up to International Classification of Retinopathy of Prematurity (ICROP) Zone II.

**Methods:** This is a single-center, cross-sectional, prospective comparative research. The presence of retinal vessel dilatation and tortuosity were identified by third year ophthalmology residents using indirect funduscopy. The residents' fundus findings were then compared to that of a retina consultant. Statistical analysis used for the data obtained were the Kappa index, Fisher exact, and McNemar test.

**Results:** A total of 82 eyes of 41 premature infants were evaluated to determine if retinal findings observed by ophthalmology residents were comparable to that of a retina consultant. Odds ratios show that age of gestation, birth weight, and history of blood transfusion are significantly associated with the presence of ROP. Retinal vessel tortuosity and dilatation are also more common among infants diagnosed with ROP. There was no significant difference between the retinal vascular findings of the retina consultant and the third year ophthalmology residents in terms of identifying retinal vessel dilatation and tortuosity ( $P < 0.05$ ).

**Conclusions:** After sufficient and in-depth ophthalmology training, third year ophthalmologists, who will be general ophthalmologists in the future, can reliably identify eyes at risk for severe retinopathy of prematurity on the basis of retinal vascular dilatation and/or tortuosity.

### Intravitreal Injection of Conbercept for Aggressive Posterior Retinopathy of Prematurity

First Author: Yong **CHENG**

**Purpose:** To observe the effects of intravitreal injection of conbercept for aggressive posterior retinopathy of prematurity (AP-ROP).

**Methods:** This was a retrospective case study. Twenty-one patients (40 eyes) with AP-ROP were enrolled in this study. There were 9 males (18 eyes) and 12 females (22 eyes), with the mean gestational age of  $28.30 \pm 1.79$  weeks and the mean birth weight of  $1021.40 \pm 316.70$  g. All the lesions in 40 eyes were located in the posterior zone, with 24 eyes in zone I and 16 eyes in zone II. All the eyes were treated with intravitreal injection of conbercept 0.025 mL (0.25 mg). During follow-up, nonresponders or patients with deterioration were retreated with intravitreal injection of conbercept or photocoagulation; patients with progressive deterioration to stage 4 received vitrectomy. At 1, 2, 4, 8, 12, 16, 20, and 24 weeks after treatment, the disappearance or decrease of retinal vessel tortuosity and neovascularization and the growth of the normal retinal vessels toward the peripheral retina were evaluated.

**Results:** Thirty-six eyes were cured with only 1 injection; the cure rate was 90.00%. However, 2 eyes (5.00%) progressed to stage 4 with contractive retinal detachment, which underwent vitrectomy. Two eyes (5.00%) received 2 injections, with the remaining avascular zone area treated by photocoagulation. No major systemic or ocular complications after injection appeared. All lenses remained transparent and no iatrogenic retinal hole occurred during follow-up.

**Conclusions:** Intravitreal injection of conbercept is effective in the treatment of AP-ROP.





### Is Antithymocyte Globulin Therapy Responsible for Central Serous Retinopathy in Aplastic Anemia?

First Author: Sushil **PATIL**

Co-Author(s): Sherine Marina **DSOUZA BRAGANZA**, M B **THIRUMALES**, K Bhujang **SHETTY**

**Purpose:** To investigate the association of central serous retinopathy (CSR) in aplastic anemia with treatment via antithymocyte globulin (ATG).

**Methods:** Complete ophthalmic evaluations with optical coherence tomography (OCT), OCT angiography, fundus autofluorescence, and fundus photo were performed. ATG therapy was 1.5 mg/kg IV infusion per day for 7-14 days. Follow-up was at 1, 3, and 6 months.

**Results:** Complete remission of central serous retinopathy with resolution of neurosensory detachment from 630  $\mu$ m with altered foveal contour to 180  $\mu$ m with normal foveal contour on cessation of ATG was observed at 1, 3, and 6-month follow-up.

**Conclusions:** We found that ATG was responsible for inducing central serous retinopathy, which resolved upon cessation of ATG.

### Is Optic Disc Drusen Associated With Idiopathic Polypoidal Choroidal Vasculopathy?

First Author: Sarojini **KRISHNAN**

Co-Author(s): Haslina **ALI**, Kiat Phang **LING**, Wee Min **TEH**

**Purpose:** To report an eye with idiopathic polypoidal choroidal vasculopathy (IPCV) and optic disc drusen (ODD).

**Methods:** Case report.

**Results:** A 50-year-old Malay woman presented with left eye central scotoma for the past 1 month. The visual acuity was 6/18 in the left and 6/9 in the right. Posterior segment examination showed ODD in both eyes and the left eye associated with peripapillary subretinal fluid and submacular hemorrhage. Ultrasound B-scan and red free photography revealed optic nerve

head drusen. Optical coherence tomography (OCT) of the left eye showed peripapillary pigment epithelial detachment with subretinal fluid. Provisional diagnosis of left eye choroidal neovascularization (CNV) secondary to ODD was made. However, indocyanine green angiography (ICGA) of the left eye revealed presence of peripapillary polyps with branching vascular network. Therefore, the patient was treated as IPCV and given combination of photodynamic therapy and monthly anti-vascular endothelial growth factor (anti-VEGF). The left eye vision was improved to 6/12 and OCT revealed resolving of the subretinal fluid after 2 months.

**Conclusions:** ODD can cause compression of the subretinal vessels at the optic disc resulting in retinal ischemia and release of vascular endothelial growth factor, which may trigger the development of CNV or PCV. The rarity of this combination makes it interesting to study more cases of ODD with IPCV. Importantly, thorough evaluation in distinguishing the PCV from the CNV that mimics it is crucial for early detection and prompt intervention. In this case, ICGA was the diagnostic method to differentiate the PCV from CNV secondary to ODD.

### Kuala Lumpur General Hospital Experience on Management of Aggressive Posterior Retinopathy of Prematurity

First Author: Nor Akmal **BAHARI**

Co-Author(s): Jamalia **RAHMAT**, Sunder **RAMASAMY**

**Purpose:** Aggressive posterior retinopathy of prematurity (APROP) is a severe form of ROP that rapidly progresses to stage 5 if untreated. However, with early detection, accurate treatment, and proper monitoring the complications can be reduced. Therefore, we would like to report the APROP outcomes managed in Kuala Lumpur General Hospital (KLGH).

**Methods:** This was a retrospective review of 17 patients with 33 eyes diagnosed as APROP from the year 2008 until 2014.

**Results:** Mean gestational age was  $28.29 \pm 2.44$







weeks and mean birth weight was  $1120 \pm 290$  g. Mean first ROP screening was at  $32 \pm 2.0$  weeks and mean first treatment given was at 34.1 weeks of gestation. One eye was excluded as it was diagnosed as high-risk prethreshold ROP. Thirteen eyes were treated for ROP previously by the referring center. The main clinical features were flat neovascularization ( $n = 14$ ), retinal hemorrhage ( $n = 9$ ), vitreous hemorrhage or preretinal hemorrhage ( $n = 8$ ), and retinal detachment ( $n = 5$ ). The APROP features were mainly found in zone 1 ( $n = 20$ , 60.6%). Twenty-four eyes (72.7%) had received combination treatment: laser photocoagulation and intravitreal ranibizumab. Five eyes (15.2%) had received intravitreal ranibizumab monotherapy, and 4 eyes (12.1%) had received laser only. Twelve eyes (36.4%) had required additional treatment for recurrence. At final visit, 28 eyes (82.4%) had a favorable anatomical outcome, where the retina was flat at last review. Thirteen eyes (39.4%) had a favorable visual outcome with logarithm of the minimum angle of resolution (logMAR) vision  $\geq 0.5$ . The majority ( $n = 14$ , 42.8%) had moderate visual impairment whereas 5 eyes (15.2%) were blind.

**Conclusions:** Despite good structural outcome, the visual outcome for APROP in this study was poor.

### Modified Approach for Public Education in Diabetic Retinopathy

*First Author: Lokesh JAIN*

**Purpose:** To find the best possible method for increasing public awareness for screening purposes in diabetic retinopathy.

**Methods:** All the screening camps organized between November 2009 and December 2014 for diabetic retinopathy were included in the study. Dilated fundus examination was done with binocular indirect ophthalmoscopy with +20 diopter (D) lens by a retinal specialist. Various approaches included mass audience approaches with public meetings, posters, TV, radio, banners, and newspapers. Group approaches such as seminars and patient

interaction and individual approaches through patient education and counseling were compared with a modified approach of a dramatized short movie on diabetic retinopathy.

**Results:** In 140 camps, out of 22,540 patients 4680 were diabetic; 2202 had diabetic retinopathy and 1602 required laser treatment. Our results showed that the new approach of the movie showed a significant increase in diabetes mellitus (DM) patients and a 17% increase in laser treatment.

**Conclusions:** People vary widely in their socioeconomic conditions, traditions, beliefs, attitudes, and level of knowledge so that a uniform communication approach is not viable. A mixture of different approaches must be developed depending on the local circumstances and we must constantly evolve new methods of screening and awareness.

### Multimodal Imaging in Macular Telangiectasia Type 2


*First Author: Ling CHEN*

*Co-Author(s): Feng WEN*

**Purpose:** To report the multimodal imaging features of macular telangiectasia type 2 (Mac-Tel 2).

**Methods:** A 62-year-old woman complained of blurred vision for more than 5 years. She was diagnosed with binocular neovascular age-related macular degeneration (AMD) in other hospitals, and intravitreal anti-vascular endothelial growth factor (anti-VEGF) injection was performed in her right eye about 2 months previously but without obvious effects. Color fundus photography (CFP), autofluorescence (AF), fundus fluorescein angiography (FFA), optical coherence tomography (OCT), and optical coherence tomography angiography (OCTA) were performed.

**Results:** Characteristic findings on FA were observed as telangiectatic capillaries predominantly temporal to the foveola in the early phase and a diffuse hyperfluorescence in the late phase. OCT showed the hyporeflective cavities of the inner and outer neurosensory





retina, as well as the outer neurosensory atrophy. AF showed a binocular symmetrical oval high autofluorescence region, which corresponded to the FFA leakage zone. OCTA showed a decrease in the inner capillary network and dilatation in the deep capillary network, as well as an invasion of the inner and deep retinal vessels into the outer and subretinal space. Combined with the imaging features and fundus changes, the diagnosis was corrected to Mac-Tel 2.

**Conclusions:** Mac-Tel 2 has typical multimodal imaging features; a diffuse hyperfluorescence in the late phase of FFA is not an indication of an anti-VEGF injection. It is believed that its pathogenesis is associated with Muller cell damage and that neurotrophic factors may slow disease progression.

---

### Multimodal Imaging of Choroideremia and Its Carrier State With Autofluorescence and OCT Angiography

*First Author: Shaheeda MOHAMED  
Co-Author(s): Chi Wai TSANG*

**Purpose:** To evaluate the relationships between retinal pigment epithelium (RPE), photoreceptors, choroidal atrophy, and peripapillary atrophy in choroideremia and its carrier state.

**Methods:** Four eyes of 2 patients with choroideremia and 2 eyes of a choroideremia carrier underwent fundus photography, optical coherence tomography (OCT), fluorescein and indocyanine green angiography, OCT angiography, and autofluorescence imaging.

**Results:** Choroideremia is a rare, X-linked progressive retinal dystrophy. Nyctalopia is followed by loss of peripheral visual field in teenage years, although good central visual acuity can be retained into the fifth decade. Choroideremia carriers are often asymptomatic but demonstrate mosaic patchy pigmentary changes on fundus examination, which correlates with autofluorescence. Choroideremia patients, on the other hand, demonstrate widespread

pigment clumping at the level of the RPE and RPE loss. Peripapillary atrophy is also an early feature. Choriocapillaris loss is seen on OCT angiography. Outer segment loss of photoreceptors and photoreceptor tubulations at the margins correlate with loss of RPE seen on autofluorescence.

**Conclusions:** In choroideremia, progressive structural changes at the level of the RPE affect the overlying photoreceptors in a centripetal fashion, causing a shrinking island centered on the fovea and loss of visual acuity. Multimodal imaging is valuable in monitoring disease progression and may serve as biomarkers in the evaluation of retinal function in future gene therapy trials.

---

### Natural Course and Nonsurgical Management of Idiopathic Macular Hemorrhage

*First Author: Pritam BAWANKAR  
Co-Author(s): Diva MISRA, Ronel SOIBAM*

**Purpose:** To investigate the natural course of idiopathic solitary macular hemorrhage (ISMH) in young adults in reference to its resolution and visual recovery and also to evaluate observation alone as a management modality of such hemorrhage.

**Methods:** The study was a prospective, nonrandomized observational series. Nine consecutive cases of unocular ISMH without any systemic and local ocular pathology with decreased vision were closely observed. The cases were diagnosed on the basis of clinical examination and investigations. Main outcome measures were complete visual recovery, complete absorption of hemorrhage, normalization of foveal contour on optical coherence tomography (OCT), and normal multifocal electroretinogram (MFERG) findings.

**Results:** Average age of the cohort was 36.6 years and 5 of them were male, with presenting vision ranging from 20/40 to 20/120. Clinically, hemorrhage had typical glistening reflex and surface striae and naturally absorbed within 2 months of follow-up. Vision recovered to 20/20 in all with normalization of foveal contour on





OCT.

**Conclusions:** ISMH in young adults can be diagnosed clinically with slit lamp biomicroscopy. It resolves naturally without residual visual defect. Observation is a safe management option for the condition.

### Nonarteritic Anterior Ischemic Optic Neuropathy: An Ocular Manifestation of Systemic Lupus Erythematosus

*First Author: Hanis ZUHAIMY*

*Co-Author(s): Hayati ABDUL AZIZ, Siew Hong HOOI*

**Purpose:** To report a case of consecutive nonarteritic anterior ischemic optic neuropathy (NAION) as an ocular manifestation of systemic lupus erythematosus (SLE).

**Methods:** A case report.

**Results:** A 44-year-old woman with diabetes mellitus, hypertension, and dyslipidemia presented to a different eye center with sudden onset of right eye inferior visual field defect for 1 month's duration. She was diagnosed as right eye NAION. Two months later, she presented to us with sudden onset of total visual loss in the left eye. She had symptoms of joint pain, photophobia, alopecia, and a history of 11 recurrent miscarriages. The visual acuity of the right eye was 6/36 while the left eye was counting fingers. There was a left relative afferent pupillary defect and left optic disc swelling. The right optic disc was crowded and hyperemic. Perimetry showed a dense inferior arcuate defect in the right eye and total visual field defect in the left eye. Inflammatory markers were raised and antinuclear antibody was positive. Coagulation profile and antibodies for antiphospholipid syndrome (APS) were negative. Neuroimaging of the brain and orbit were normal. A diagnosis of bilateral NAION secondary to underlying SLE was made based on the clinical signs supported by laboratory results. Systemic steroids and lifelong aspirin were commenced. However, she became blind in both eyes from optic disc atrophy.

**Conclusions:** Bilateral consecutive nonarteritic anterior ischemic optic neuropathy is a rare

ocular manifestation of SLE and often has a poor visual outcome. A thorough history, ocular, and systemic examination with appropriate investigations would be sight saving.

### Nuances in Pathology of Retinal Pigment Epithelium Atrophic Changes

*First Author: Pritam BAWANKAR*

*Co-Author(s): Dipankar DAS, Diva MISRA, Ronel SOIBAM*

**Purpose:** Retinal pigment epithelial (RPE) changes in pathology are challenging for ophthalmologists and basic scientists. We studied the pattern of atrophy in RPE in pathological samples.

**Methods:** Observation and laboratory study in 18 enucleated eyeball samples of traumatic/painful blind eye. RPE were studied in those samples unstained and with different types of staining. They were documented with grossing and with compound microscope. Pattern of RPE atrophy correlated with underlying choroidal vascular patterns.

**Results:** Pattern of RPE atrophy showed the central cell in the cluster was first to be affected compared to the adjoining cells. Sizes of inner cells were seen larger and correlated with the rest of the cells. These cells form a rosette, which stands alone and can act as an anatomical unit.

**Conclusions:** Morphological cellular changes in RPE were found to be unique and can have a clinical significance.

### Optical Coherence Tomography Angiography Findings of an Optic Disc Melanocytoma in a Glaucomatous Eye

*First Author: Yoshiyuki KITA*

*Co-Author(s): Akito HIRAKATA, Ritsuko KITA, Akiko MURAI, Masahiko SANO*

**Purpose:** To determine the optical coherence tomography angiography (OCTA) characteristics of a case of optic disc melanocytoma (ODM) with associated visual field and retinal nerve fiber layer (RNFL) defect due to glaucoma.





**Methods:** The left eye of a 37-year old female patient followed for a stable ODM for 10 years was investigated with OCT, OCTA, and fluorescein (FA) and indocyanine green angiography (ICGA). In addition to the detection of previously unknown moderate inferotemporal neuroretinal rim loss, an extensive melanocytoma covering the superior part of the disc and an inferotemporal and superotemporal wedge-shape glaucomatous RNFL thinning were seen. Inferior nasal step and mild superior arcuate sensitivity loss were found with Humphrey. Intraocular pressure was 12 mm Hg in both eyes.

**Results:** In the area of the melanocytoma, FA showed minimal vasculature and weak staining in the late angiography stages, while ICGA showed no signals. In contrast, OCTA showed a dense vasculature of both the superficial and deep layers of the melanocytoma. OCTA also showed a reduction of peripapillary perfusion in the areas of the glaucomatous RNFL bundle defects.

**Conclusions:** In the presented case of stable ODM and newly detected normal-tension glaucoma, OCTA provided more information on perfusion than FA and ICGA which are limited by the heavy pigmentation of ODM. It also showed a similarly decreased capillary perfusion in both RNFL bundle defects, suggesting that the structural damage is related to glaucoma and not compression by melanocytoma. These results suggest that OCTA may be a preferred method over angiography in ODM cases.

### Peripapillary Circumscribed Choroidal Hemangioma in a Child With PHACE(S) Syndrome

*First Author: Akash TANDON*  
*Co-Author(s): Mahantesh BIRAJDAR, Chetan CHHIKARA, Yogish KAMATH, Leslie LEWIS, Shailaja SHENOY*

**Purpose:** To describe the ocular features in a child with PHACE(S) syndrome.

**Methods:** A 2-year-old female child with PHACE(S) syndrome based on the presence of

left-sided facial hemangioma and Dandy Walker malformation was referred from the pediatrics department for ophthalmic evaluation. Other cerebrovascular anomalies that were noted on magnetic resonance imaging (MRI) were as follows: 1) the flow void of the intracranial segment of the right internal carotid artery (ICA) was attenuated and smaller as compared to the left ICA; 2) a prominent flow void connecting the supraclinoid left ICA and posterior circulation.

**Results:** On examination, the anterior segment was normal. Intraocular pressure was also normal in both the eyes. On fundus examination peripapillary circumscribed hemangioma was noted in the left eye. As there was no exudation or subretinal fluid, the child was asked to follow up after 3 months.

**Conclusions:** PHACE(S) syndrome should be considered as a differential diagnosis in children presenting with choroidal hemangiomas and facial angiomas. A thorough systemic work-up and neuroimaging should be considered to confirm the diagnosis.

### Predictors of Visual Outcome in Treated Polypoidal Choroidal Vasculopathy Among a Multiracial Population in a Malaysian Tertiary Center

*First Author: Nazima ALI*  
*Co-Author(s): Wan Haslina Wan Abdul HALIM, Hazlita MOHD ISA, Mushawiahti MUSTAPHA*

**Purpose:** To determine the predictors of visual acuity improvement in treated multiracial polypoidal choroidal vasculopathy (PCV) patients.

**Methods:** The demographic data of 99 patients with PCV were included in this retrospective review. Study parameters included visual acuity (VA), clinical characteristics on fundus photography, optical coherence tomography (OCT), fundus fluorescein angiography (FFA), and indocyanine green angiography (ICG). The patients were divided into 2 groups: improved vision and no improvement in vision based on their logarithm of the minimum angle of resolution (logMAR) VA at 1-year follow-up.



**Results:** One hundred ten eyes of 99 PCV patients (average age 70.76) were included. Fifty-seven (57.2%) subjects were male, 63 (63.6%) Chinese, and 32 (32.3%) Malay. There were no significant visual outcome differences among the races. At 1-year follow-up, 22 eyes had improved visual outcome. The baseline logMAR VA significantly determined the VA at 1 year ( $P = 0.004$ ). Presence of drusen was associated with no improvement in vision ( $P = 0.003$ ). The absence of multiple pigment epithelium detachments (PED) on OCT and multiple cluster-like polyps on ICG were associated with improvement in vision ( $P = 0.023$  and  $P = 0.014$ , respectively). Patients who received at least 3 monthly intravitreal anti-VEGF as well as photodynamic therapy (PDT) or argon laser had visual improvement ( $P = 0.003$ ).

**Conclusions:** Presence of drusen indicated neovascular age-related macular degeneration (NV-AMD) variant of PCV and was associated with no improvement in visual outcome. Absence of multiple PED on OCT and cluster of polyps on ICG are of significant value in predicting visual improvement. Treatment with intravitreal anti-VEGF and PDT or argon laser are also important in predicting visual improvement.

### Prognostic Factors for Visual Outcome at 12 Months After Intravitreal Anti-VEGF Injection for Eyes With Naive Myopic Choroidal Neovascularization

First Author: Rei **NEMOTO**

**Purpose:** To determine the efficacy of 1 intravitreal anti-vascular endothelial growth factor (VEGF) injection followed by pro re nata (1 plus PRN) injection in cases of naive myopic choroidal neovascularization (CNV) and to identify the prognostic variables relative to myopic CNV treated with intravitreal anti-VEGF.

**Methods:** Retrospective observational case series. In total, 35 eyes of 32 consecutive patients with naive myopic CNV who had received intravitreal anti-VEGF injections were retrospectively reviewed. They had been

followed up for at least 12 months. The primary outcomes were the patient's age, refractive error, logarithm of the minimum angle of resolution (logMAR), central macular thickness, CNV location, lacquer cracks, and CNV fundus autofluorescence pattern.

**Results:** The mean age was 61 years. The mean spherical equivalent refractive error was -11.5 diopters. The mean number of injections was 3 times during 12 months. No additional treatment was required in 6 eyes. At baseline and at 1 month, 2 months, 3 months, 6 months, and 12 months, the average logMAR were 0.50, 0.39, 0.33, 0.31, 0.29, and 0.28, respectively. In univariate analysis, a better baseline logMAR was significantly associated with better visual outcomes at 12 months.

**Conclusions:** One plus PRN intravitreal anti-VEGF monotherapy was effective in improving visual acuity in myopic choroidal neovascularization. The baseline logMAR was the prognostic factor of myopic CNV at 12 months.

### Real-World Effectiveness and Safety Outcomes With Ranibizumab 0.5 mg Treatment in Taiwanese Patients With Polypoidal Choroidal Vasculopathy: Subgroup Analysis of the REAL Study

First Author: Shwu-Jiuan **SHEU**

Co-Author(s): Jiann-Torng **CHEN**, San-Ni **CHEN**, Cheng-Kuo **CHENG**, Chi-Chun **LAI**, Ling **YEUNG**

**Purpose:** To evaluate the effectiveness and safety of ranibizumab 0.5 mg treatment in Taiwanese patients with polypoidal choroidal vasculopathy (PCV) in the REAL study.

**Methods:** REAL was a 12-month, multicenter, observational, prospective study of ranibizumab 0.5 mg treatment in patients with neovascular age-related macular degeneration. The effect of ranibizumab in patients with PCV was assessed by exploratory subgroup analysis.

**Results:** Of the 64 patients diagnosed with PCV at baseline, 23.4% had received ranibizumab as prior treatment. During the study, photodynamic therapy (PDT) in addition



to ranibizumab 0.5 mg was received by 11 patients [once ( $n = 9$ ); twice ( $n = 2$ )]. At month 12, the mean (SD) change in visual acuity (VA) from baseline was 1.1 (17.8) Early Treatment Diabetic Retinopathy Study (ETDRS) letters in patients treated with ranibizumab alone [nonsignificant;  $n = 47$ ; mean baseline, 50.1 (12.9) letters] versus a marked improvement in VA in patients treated with ranibizumab plus PDT [ $P < 0.001$ ; 14 (9.2) letters; mean baseline, 51.4 (15.9) letters]. The mean (SD) number of ranibizumab injections was similar in patients receiving and not receiving PDT [3.5 (1.8) and 3.1 (1.4) injections, respectively]. However, 43% of the monoranibizumab group received additional bevacizumab [2.7 (1.9) injections]. Patients ( $n = 5$ ) administered with bevacizumab in the ranibizumab-PDT group received only 1 bevacizumab injection, mostly on the same day with PDT. No new safety findings were observed.

**Conclusions:** In real-world settings, ranibizumab 0.5 mg treatment for 12 months maintained VA in Taiwanese patients with PCV. Improvements in VA were more pronounced in patients receiving ranibizumab plus PDT. There were no new safety findings.

### Repeated Intravitreal Bevacizumab Injections Versus Single Combined Intravitreal Bevacizumab and Posterior Subtenon Triamcinolone Injections for Treatment of Diabetic Macular Edema

*First Author: Sameh MANDOUR  
Co-Author(s): Nermeen BADAWI, Amin ELLAKWA*

**Purpose:** To compare the efficacy of combined intravitreal bevacizumab and subtenon triamcinolone versus 3 intravitreal injections of bevacizumab at 1-month intervals for reducing foveal thickness.

**Methods:** Sixty eyes of 30 diabetic patients with bilateral diabetic macular edema were randomly enrolled in 2 groups, group A eyes treated with 3 intravitreal injections of bevacizumab 1 month apart and group B eyes treated with a single intravitreal injection of bevacizumab combined with subtenon

triamcinolone in the same operative session. Pre- and postoperative clinical data were measured and followed up over 6 months.

**Results:** Difference between pretreatment and posttreatment clinical data for each parameter in the same group was highly statistically significant. However, on comparing results of posttreatment best corrected visual acuity (BCVA), intraocular pressure (IOP), and central macular thickness (CMT) in both groups, there was no statistically significant difference.

**Conclusions:** Combination of subtenon triamcinolone and intravitreal bevacizumab is a safe and effective choice to treat diabetic macular edema (DME).

### Retinal Vein Occlusion as the Surrogate Marker for Premature Brain Aging in Young Patients

*First Author: Kwan Hyuk CHO*

**Purpose:** To investigate cerebral small vessel disease (SVD) in patients with incident retinal vein occlusion (RVO).

**Methods:** Retrospective, case-control, observational trial of 125 patients with RVO who had brain magnetic resonance imaging (MRI) available and 1105 age-matched controls who underwent comprehensive medical interviews and MRI. Underlying cardiovascular diseases and MRI findings were investigated in the patients with RVO according to age ( $<60$  years or  $\geq 60$  years) and RVO occlusion level (central or branch). The characteristics of underlying cardiovascular disease and MRI findings were compared between the younger patients with RVO and age-matched controls. The cerebrovascular burden was also assessed in the younger patients with RVO.

**Results:** The mean age of the patients with RVO was  $63.9 \pm 12.1$  years and the predominant underlying disease was hypertension (72/125, 58%). The older RVO group had a longer history of hypertension and less smoking history. The prevalence of cerebral SVD in the RVO group was 54% (68/125). The prevalence of cerebral SVD was significantly higher in older



than in younger patients with RVO [62% (53/86) vs 38% (15/39),  $P = 0.016$ ]. However, the latter had a significantly higher prevalence of cerebral SVD than their age-matched controls [38% (15/39) vs 4% (47/1105),  $P < 0.001$ ]. There was no difference in prevalence of cerebral SVD between the central and branch RVO groups ( $P = 0.478$ ).

**Conclusions:** Cerebral SVD presented frequently in patients with RVO and was magnified in young patients, suggesting that RVO is a surrogate marker for cerebral SVD.

### Reversal of Impending CRVO Secondary to Hyperleukocytosis in CML by Leukapheresis: A Life and Vision Saving Procedure

First Author: Logesvaran **MURUGAN**

Co-Author(s): Umi Kalthum **MD NOH**, Aida Zairani **MOHD ZAHIDIN**, Wan Haslina **WAN ABDUL HALIM**

**Purpose:** We report an uncommon case of impending central retinal vein occlusion (CRVO) in a patient with newly diagnosed chronic myeloid leukemia (CML) and successful reversal with leukapheresis.

**Methods:** Case report.

**Results:** A previously healthy 13-year-old Malay girl presented with vomiting for 2 days associated with abdominal discomfort. General examination revealed lymphadenopathy and massive splenomegaly. Investigations showed severe hyperleukocytosis and anemia. Bone marrow aspirate and trephine biopsy confirmed CML in the chronic phase. She was promptly referred to the ophthalmology team for assessment of vasculopathy. She denied any visual symptoms and her visual acuity was 6/6 in both eyes with no relative afferent pupillary defect. Her anterior segment examination and intraocular pressure were unremarkable. Bilateral fundus showed swollen and hyperemic optic disc. There were markedly dilated and tortuous retinal venules with peculiar perivascular white cell extravasation, scattered intraretinal hemorrhages, and Roth spots at midperiphery. The macula was normal and there was no neovascularization either in retina

or at angle. She received cytoreduction therapy with hydroxyurea, cytarabine, and 4 cycles of leukapheresis. Consequently, her leukocytes reduced dramatically with associated significant improvement in fundus findings. The retinal vessels became progressively less tortuous and dilated with resorption of perivascular leukocytes and improvement in optic disc swelling.

**Conclusions:** This case highlights the dramatic improvement in fundus with swift cytoreduction and remedial measures which halted and reversed the progression of impending CRVO. Progressive improvement in retinal venules helps to indicate the success of the treatment regime in such cases.

### Subretinal Neovascularization Secondary to Choroidal Nevus: A Diagnostic Dilemma

First Author: Diva **MISRA**

Co-Author(s): Manabjyoti **BARMAN**, Pritam **BAWANKAR**, Ronel **SOIBAM**

**Purpose:** To report a challenging case of choroidal neovascularization (CNV) with suspicious choroidal nevus masquerading as age-related macular degeneration (AMD) that was treated successfully with anti-VEGF and transpupillary thermotherapy (TTT).

**Methods:** Retrospective case report.

**Results:** A 50-year-old male with vision of counting fingers at 2 m was referred with a diagnosis of exudative AMD in the left eye. The patient was given 3 monthly doses of intravitreal bevacizumab by the referring doctor with minimal improvement. Fundus examination revealed elevated, yellow-white chorioretinal lesion with exudation at macula and an adjacent pigmented lesion of 2 disc diameters with minimal elevation inferotemporal to the macula. Fluorescein angiography demonstrated mixed hyperfluorescence with minimal leakage at subfoveal location near the border of the hypofluorescence due to pigmented lesion. Optical coherence tomography confirmed CNV with overlying subretinal fluid. A diagnosis of subfoveal classic CNV associated with





a choroidal nevus was made. After written informed consent was obtained, the patient was given 3 sittings of TTT. Three months later, CNV appeared inactive and smaller in size with complete resolution of exudation and subretinal fluid. The choroidal nevus appeared smaller with minimal pigmentation and without fresh exudation. Best-corrected visual acuity improved to 20/200. The lesion was still inactive and final visual acuity was stable throughout 1 year of follow-up.

**Conclusions:** To conclude, CNV-related choroidal nevus may result in a diagnostic dilemma due to its uncommon nature. Careful examination and proper treatment may help in saving vision and the eyeball.

### The Use of Bevacizumab in the Treatment of Patients With Retinopathy of Prematurity in Mongolia

*First Author: Tsengelmaa CHULUUNBAT*

**Purpose:** To investigate the outcome of the anti-vascular endothelial growth factor agent bevacizumab in the treatment of retinopathy of prematurity (ROP) in NCMCH.

**Methods:** Prospective cohort study.

**Results:** A total of 611 premature infants with birth weight (BW)  $\leq$  2500 g and/or gestational age (GA)  $\leq$  34 weeks had completed ROP screening. ROP was diagnosed in 52 (8.5%) infants. The mean GA was  $28.6 \pm 1.88$  weeks and the mean BW was  $1277.35 \pm 271.29$  g. Of the 28 (4.5%) infants receiving treatment, the mean GA was  $28.6 \pm 2.11$  weeks, and the mean BW was  $1315.50 \pm 230.71$  g. After receiving IVB injections, 4 patients (15%) exhibited ROP regression. The mean injection time was  $35.2 \pm 2.1$  weeks postmenstrual age. No notable systemic complications related to the IVB injections were observed.

**Conclusions:** After IVB, resolution of ROP was noted in 85% of the patients in treatment-requiring ROP. However, nonresponse to IVB was noted in 15% of treated eyes and required additional treatment.

### The Use of Weight, Insulin-Like Growth Factor, Neonatal ROP (WINROP) Algorithm in Predicting Severe Retinopathy of Prematurity in a Local Hospital: A Pilot Study

*First Author: Ronald TIU*

**Purpose:** The purpose of this study is to investigate the accuracy of the WINROP algorithm in predicting severe retinopathy of prematurity (ROP) among preterm infants of less than 32 weeks age of gestation (AOG) in a local hospital.

**Methods:** The records of preterm infants of less than 32 weeks gestational age who were admitted to the neonatal intensive care unit at a local hospital from September 2013 to August 2016 were reviewed. Birth weight (BW) and the weekly weight measurements were entered into the secure online computer-based surveillance system WINROP (weight, IGF-1, neonatal ROP) and the outcome was analyzed. The fundus findings of the infants were examined for ROP following the guidelines of International Classification of ROP via indirect ophthalmoscopy.

**Results:** A total of 45 neonates (90 eyes) were entered into the WINROP online surveillance. The algorithm had a sensitivity of 68.42% for detecting infants at risk of developing severe ROP and 81.08% when all forms of ROP were considered. The specificity was 47.17%. WINROP had more accuracy in detecting infants with younger gestational age, lower birth weights, and small size for gestational age. Positive predictive value was at 31.70% while the negative predictive value was at 80.64%.

**Conclusions:** The sensitivity of 68.42% and specificity of 47.17% of the WINROP algorithm in predicting severe ROP in a local hospital was lower compared with previous studies done in other countries.







### Ultra-Widefield Imaging Findings of an Infant With Retinopathy of Prematurity Treated With Intravitreal Bevacizumab

First Author: Cenap **ESENULKU**  
Co-Author(s): Mehmet **KOLA**

**Purpose:** To show the ultra-widefield (UWF) imaging findings of retinopathy of prematurity (ROP) before and after the intravitreal injection of bevacizumab.

**Methods:** A newborn in the 32nd week with a birth weight of 2345 g was referred to us. The first fundus examination with binocular indirect ophthalmoscopy was done at the fifth postnatal week. There was plus disease, zone 2 posterior stage 3 ROP in both eyes at the time of examination. Intravitreal bevacizumab 0.625 mg was injected into both eyes the next day. We obtained fundus photos using the Optos UWF imaging system before and after the injection at the first, second, and third week.

**Results:** Posterior pole and peripheral retina were well visualized by UWF imaging. Regression of plus disease, fibrovascular proliferation, ridge, and other ROP findings might be monitored by the UWF system.

**Conclusions:** Plus disease, extraretinal fibrovascular proliferation, demarcation line, ridge, avascular area, popcorn lesion (nodular endothelial proliferation), and other findings of retinopathy of prematurity are clearly demonstrated by UWF imaging.

### Ultra-Widefield Imaging of Choroidal Dystrophies

First Author: Vinod **KUMAR**

**Purpose:** To study the ultra-widefield (UWF) imaging and swept-source optical coherence tomography (SS-OCT) features of choroidal dystrophies.

**Methods:** Retrospective study of 13 patients with various choroidal dystrophies seen in a tertiary eye care center. All patients underwent complete ophthalmological examination and were evaluated in terms of visual acuity, color fundus photographs, autofluorescence, and

fluorescein angiography (in selected patients) using ultra-widefield imaging (Optos Inc) and SS-OCT. The findings were studied and compared to standard fundus photography and fluorescein angiography.

**Results:** Two cases of gyrate atrophy, 2 cases of choroideremia, 1 case of choroideremia carrier, 2 cases of posterior polar annular choroidal dystrophy, 1 case of posterior polar central and annular choroidal dystrophy, 2 cases of posterior polar central choroidal dystrophy, 2 cases of central areolar choroidal dystrophy, and 1 case of posterior polar hemispherical choroidal dystrophy were identified. The ultra-widefield imaging provided quick panoramic images with characteristic patterns of chorioretinal atrophy in these cases. SS-OCT characterized the patterns of choroidal thinning as the chorio-scleral junction could be seen in all cases.

**Conclusions:** UWF imaging along with SS-OCT helps in better characterization of various choroidal dystrophies. Excellent quality images could be obtained despite poor patient cooperation because of poor vision.

### Validation of the WINROP Screening Algorithm of Preterm Infants in East Malaysia

First Author: Nurhayati **ABDUL KADIR**  
Co-Author(s): Shuaibah **AB GHANI**, Syed Shoeb **AHMAD**, Mae-Lynn **BASTION**

**Purpose:** To validate the WINROP screening algorithm ([www.winrop.com](http://www.winrop.com)) based on longitudinal measurements of neonatal body weights in predicting the development of severe retinopathy of prematurity (ROP) among preterm infants admitted to the neonatal intensive care unit of a tertiary care center in Malaysia.

**Methods:** All premature infants of less than 32 weeks gestational age were included in this cohort. Their body weight was measured weekly from birth to 36 weeks postmenstrual age and entered into the computer-based surveillance system: WINROP. Infants were then classified by the system into high- or low-





risk alarm groups. The retinopathy findings were recorded according to Early Treatment for Retinopathy of Prematurity criteria.

**Results:** A total of 151 infants with median gestational age at birth of 30 weeks (IQR 2.1) and mean birth weight of 1264 g (SD 271) were analyzed. High-risk alarm was signaled in 85 (56.3%) infants and 9 (6.6%) infants developed type 1 ROP. One infant in the low-risk alarm group developed type 1 ROP requiring laser retinal photocoagulation. The median time from the high-risk alarm signal to the development of type 1 retinopathy of prematurity was 10.4 (IQR 8.4) weeks.

**Conclusions:** In this cohort, the WINROP algorithm had a sensitivity of 90%, with negative predictive value of 98.5% (95% CI) for detecting infants with type 1 ROP and was able to predict infants with ROP earlier than their due date screening. This study shows that a modified version of the WINROP algorithm aimed at specific populations may improve the outcome of this technique.

### Values of Standard Full-Field Electroretinography in Indonesian Diabetic Retinopathy Patients

*First Author: Syntia NUSANTI  
Co-Author(s): Ari DJATIKUSUMO, Anggun RAMAYUDHANTA, Kirana SAMPURNA*

**Purpose:** Electroretinography (ERG) is an objective method to evaluate retinal function. The aim of this study was to evaluate ERG values in patients with diabetic retinopathy (DR).

**Methods:** Thirty-three patients with diabetic retinopathy underwent ERG examination. ERG amplitudes and implicit time values were measured according to recommendations by the International Society for Clinical Electrophysiology of Vision (ISCEV). Evaluations consisted of scotopic 0.01 ERG (rod response), scotopic 3.0 ERG (rod-cone response), scotopic 3.0 oscillatory potential (OP) ERG, and photopic (cone response) 3.0 flicker. Patients were grouped based on their DR severity.

**Results:** There were 10 patients with mild to

moderate nonproliferative DR (NPDR) with a 6.5-year history of diabetes mellitus (DM), 6 severe NPDR with a 9.3-year history of DM, and 17 proliferative DR with a 9.5-year history of DM. Mean scotopic 0.03 a-wave amplitude was 179.50  $\mu\text{V}$  for group I, 139.87 for group II, and 156.16 for group III. Mean scotopic 3.0 b-wave amplitude was 351.5  $\mu\text{V}$  in group I, 236.5 in group II, and 278.35 in group III. Mean scotopic 3.0 OP-wave sum amplitude was 152.8  $\mu\text{V}$  in group I, 63.5 in group II, and 71.59 in group III. Mean photopic 3.0 flicker wave amplitude was 83.1  $\mu\text{V}$  in group I, 65.01 in group II, and 83.13 in group III.

**Conclusions:** These results showed that amplitude ERG in NPDR is lower than in other groups.

### Retina (Surgical)

#### A Rare Case of Vitrectomy-Induced Sympathetic Ophthalmia in a Young Boy

*First Author: Ronel SOIBAM  
Co-Author(s): Manabjyoti BARMAN, Pritam BAWANKAR, Dipankar DAS, Diva MISRA*

**Purpose:** To describe a case of sympathetic ophthalmia following vitrectomy for retinal detachment due to blunt trauma.

**Methods:** Retrospective case report.

**Results:** An 11-year-old male child underwent band buckle surgery with vitrectomy for retinal detachment following blunt trauma in the right eye. On the 26th postoperative day the patient reported diminution of vision in the left eye (6/9p N12). Ocular examination revealed flare in anterior chamber with 2+ vitreous cells, exudative retinal detachment (RD), and disc hyperemia. B-scan ultrasonography in the left eye revealed increased retinochoroidal thickness and shallow RD. Fluorescein angiography (FA) showed focal areas of diffuse hyperfluorescence with pooling of dye in subretinal spaces. The patient was put on intravenous methylprednisolone therapy for 3 days followed by tapering dose of oral steroids.



Two weeks after commencement of treatment, there was significant improvement with visual acuity (VA) 6/6, N6 and resolution of exudative RD in the left eye. The patient is maintaining normal vision with present medication in the sympathizing eye.

**Conclusions:** Persistent or atypical uveitis following vitrectomy should alert surgeons to sympathetic ophthalmia. Prompt diagnosis and management is essential to salvage vision.

### Acute Angle Closure Glaucoma Secondary to Polypoidal Choroidal Vasculopathy

First Author: Chuan Chun LIM

**Purpose:** To report a case of hemorrhagic choroidal detachment as an event leading to acute angle closure glaucoma in a patient with polypoidal choroidal vasculopathy and describe the role of pars plana vitrectomy (PPV) surgery for this condition.

**Methods:** Case report.

**Results:** An 86-year-old Chinese man presented with sudden onset monocular visual field defect of the left eye temporally. He was a known case of polypoidal choroidal vasculopathy and baseline visual acuity was 6/9 bilaterally. Examination revealed a huge pigment epithelial detachment with subretinal bleed nasal to the left optic disc. With conservative treatment, 1 week later the patient presented to the emergency department with a complaint of severe left eye pain. Vision was light perception with clinical features of angle closure glaucoma. The patient underwent left eye PPV. Postoperative recovery was complicated by hyphema and rebleeding from the hemorrhagic choroidal detachment. The patient did not regain any vision, but the eye pain was relieved.

**Conclusions:** Acute angle closure glaucoma following massive hemorrhagic choroidal detachment is a rare but grave complication of polypoidal choroidal vasculopathy with dismal visual prognosis despite prompt treatment and intervention.

### An Interesting Case of Blunt Trauma Injury With a Cricket Ball in a 12-Year-Old Child

First Author: Roshan COLACO

Co-Author(s): Mohd Anash PATHAN, Gauri KHARE, Chinmay NAKHWA, Sundaram NATARAJAN, Hemalatha VIDYASHANKAR

**Purpose:** To ensure early and correct intervention for better restoration of vision.

**Methods:** A 12-year-old child presented with a history of blunt trauma with a cricket ball to the left eye 3 months prior. On examination, left eye vision was hand movements close to face with traumatic cataract, phacodonesis, and superior nasal retinal detachment. Ultrasound biomicroscopy showed left eye zonular tear from 2-5 o'clock position. The patient underwent cataract extraction with posterior chamber intraocular lens implantation, scleral buckle with 25G pars plana vitrectomy, perflurocarbon liquid with fluid-gas exchange, and silicone oil injection.

**Results:** After 6 weeks, his vision improved to counting fingers at 3 m and N6 with video magnifier in the left eye. He was advised polycarbonate glasses.

**Conclusions:** Early timely surgical intervention will help save the eye and restore vision, especially in a young child.

### Anatomical and Functional Outcomes of Vitrectomy Surgery in Myopic Macular Holes

First Author: Renu PUTHENVILAYIL RAJAN

Co-Author(s): Sonali LOMTE, Kim RAMASAMY

**Purpose:** To evaluate macular hole surgery outcomes in patients with myopic macular holes.

**Methods:** Retrospective interventional case series. Patients with myopia (axial length > 25 mm) and macular hole that underwent pars plana vitrectomy with internal limiting membrane peeling with tamponade and minimum postoperative follow-up of 6 months were included in this study. Optical coherence tomography (OCT) before and after surgery were analyzed.



**Results:** A total of 21 eyes of 19 patients were analyzed, with an age range of 32-70 years. Most were women (n = 15, 71.42%) and the mean axial length was 27.70 mm. Associated macular detachment was seen in 8 cases (38%). SF6 was used as tamponade in 12 eyes, C3F8 in 3 eyes, and silicone oil in 6 eyes. Initial mean best corrected visual acuity was 0.89 logarithm of the minimum angle of resolution (logMAR); final mean best corrected visual acuity was 0.731 logMAR. At 6 months type 1 closure was seen in 11 (52.38%) eyes, type 2 closure in 9 (42.85%), and the hole remained open in 1 (4.76%) eye. Type 2 closure was seen in 50% of patients with preoperative serous detachment. In 2 eyes the hole closed after repeat fluid-air exchange with gas tamponade.

**Conclusions:** Pars plana vitrectomy with internal limiting membrane peeling with tamponade is an effective strategy for management of myopic macular hole. Serous macular detachment is often associated with myopic macular holes and can result in higher incidence of type 2 closure after surgery.

### Clinical Characteristics and Functional Outcomes of Vitrectomy and Internal Limiting Membrane Peeling on Macular Hole Surgery

*First Author: Chalid KURNIAWAN*

**Purpose:** The main purpose of this study was to describe the clinical profile and to report the outcome of postoperative patients with peeling of the internal limiting membrane (ILM) as a supplement to induce hole closure in macular hole (MH) surgery.

**Methods:** Retrospective observational study from medical records of patients with MH who underwent vitrectomy and peeling of ILM during 2015. Baseline characteristics and visual acuity data were described and analyzed.

**Results:** Thirty-five eyes from 31 patients were included in the study. The mean age of enrolled patients was  $62.25 \pm 6.23$  years (range, 47 to 75 years); the mean duration of MH was  $2.25 \pm 2.49$  months (range, 0.25 to 12 months); and

the mean follow-up interval was  $3.54 \pm 2.07$  months (range, 0.25 to 7 months). All eyes underwent ILM peeling during vitrectomy. The average visual acuity before operation and after operation at 1-week, 1-month, and 3-month follow-up were  $1.417 \pm 0.37$ ,  $1.602 \pm 0.72$ ,  $1.138 \pm 0.50$ , and  $1.015 \pm 0.49$ .

**Conclusions:** Most of the patients who underwent ILM peeling were female, more than 60 years old, with less than 6 months of MH duration, and had stage 4 MH. Visual acuity was clinically improved 1 and 3 months after surgery.

### Clinical Characteristics in Children Who Underwent Vitrectomy Due to Vitreous Hemorrhage

*First Author: Yu XU*

*Co-Author(s): Peiquan ZHAO*

**Purpose:** To analyze the clinical profile, causes, and outcomes of vitreous hemorrhage in children who underwent vitrectomy.

**Methods:** Charts of children less than 18 years old who presented with vitreous hemorrhage and underwent vitrectomy between July 1, 2012 and June 30, 2014 were reviewed. Data collected included demographics, cause of vitreous hemorrhage, management details, visual acuity, and follow-up.

**Results:** Sixty-two eyes of 57 children were included in this study. There were 14 female and 43 male patients. The mean age was  $7.5 \pm 5.6$  years old (range, 4 months to 18 years old). The most common causes included trauma, familial exudative vitreoretinopathy, and retinoschisis. Five patients had bilateral vitreous hemorrhage and the causes were exudative vitreoretinopathy, Terson syndrome, and retinopathy of prematurity. The intraocular tamponade included expansion gas in 10 eyes of 10 cases (16.1%), silicone oil in 20 eyes of 20 cases (32.3%), and balanced salt solution (BSS) in 32 eyes of 27 cases (51.6%). Thirty-four children (59.6%) were able to complete visual inspection. The preoperative best corrected visual acuity (BCVA) was no light perception



(NLP) to 0.2, while postoperative BCVA was NLP to 0.6. Twenty-two of them (64.7%) had improvement in visual acuity. The follow-up time was  $11.1 \pm 4.8$  months (range, 6-24 months).

**Conclusions:** Pediatric vitreous hemorrhage has a diverse etiology. Trauma was the most common cause in our series. Early vitrectomy is beneficial to the recovery of visual function in dense vitreous hemorrhage patients.

### Comparison of OCT Angiographic Changes After Anti-VEGF Monotherapy Alone or in Combination With Photodynamic Therapy in Polypoidal Choroidal Vasculopathy

First Author: Kelvin **TEO**

Co-Author(s): Gemmy **CHEUNG**, Shu Yen **LEE**, Yasuo **YANAGI**

**Purpose:** To compare changes in optical coherence tomography angiography (OCTA) in eyes with polypoidal choroidal vasculopathy (PCV) following treatment with anti-vascular endothelial growth factor (VEGF) monotherapy or combined with photodynamic therapy (PDT).

**Methods:** This was a longitudinal case-controlled study. We performed OCTA at baseline and month 3 in patients with treatment-naïve PCV undergoing monotherapy ( $n = 10$ ) or combination therapy ( $n = 13$ ). Flow signal was assessed in the outer retina and choriocapillaris using automated segmentation. Choroidal changes and pachyvessels were assessed using 10.4  $\mu\text{m}$  segment through the Haller layer. Changes were compared between treatments.

**Results:** At month 3, both groups showed similar improvement in best-corrected visual acuity (BCVA) and central retinal thickness. However, flow signal within the PCV lesion was decreased in more eyes following combination than monotherapy (84.6% vs 40.0%,  $P = 0.04$ ). Patchy reduction in flow signal within the choriocapillaris layer was noted in 15.4% and 10.0% after combination and monotherapy, respectively ( $P = 0.61$ ). Significant reduction in pachyvessel caliber was only seen after

combination therapy but not after monotherapy (75.0% vs 0.0%,  $P = 0.01$ ).

**Conclusions:** Longitudinal OCTA demonstrates more significant reduction in lesion flow and pachyvessels in the short-term following combination therapy than monotherapy, although visual and structural OCT showed similar improvement.

### Effective Treatment of Epithelial Downgrowth in a Patient With Persistent Wound Leak Following Removal of Silicone Oil for Retinal Detachment

First Author: Mae-Lynn **BASTION**

Co-Author(s): Zairani **AIDA ZAHIDIN**, Kong Yong **THEN**

**Purpose:** To share a case of epithelial downgrowth following persistent wound leak after removal of silicone oil (ROSO) in a case of recurrent retinal detachment and its effective treatment.

**Methods:** Retrospective case report.

**Results:** A 16-year-old patient with a history of bilateral cataract and high myopia underwent bilateral phacoemulsification and implantation of multifocal intraocular lens (MFIOL). Four months postoperatively he complained of left eye floaters and reducing vision. Examination showed left eye vitreous hemorrhage with MFIOL subluxation. He underwent left vitrectomy and internal search revealed 8 retinal tears. Endolaser and carbon perfluoropropane gas injection with repositioning of the MFIOL was performed. Six weeks later, retinal redetachment was noted. MFIOL was explanted and revision vitrectomy with silicone oil was performed. ROSO at 4 months was uneventful via a superior corneal incision and retina remained attached. Two weeks post ROSO, Seidel test was positive and resuturing was performed. Subsequently, an advancing epithelial membrane was noted at the superior cornea. The anterior segment surgeon performed scleral-fixated IOL implantation with manual removal of the epithelial downgrowth and injection of 5-fluorouracil (5-FU) into the anterior chamber. Three months postoperatively



the cornea was clear and pinhole vision was 6/7.5.

**Conclusions:** Epithelial downgrowth is a rare but visually threatening complication of wound leak and may occur after ROSO via the anterior chamber in aphakic individuals. The posterior segment surgeon is key in detecting this complication through thoughtful anterior segment examination. Treatment with manual removal and 5-FU injection combined with secondary lens implantation surgery can yield positive results.

### Functional and Anatomical Outcomes of Posterior Iris Claw Intraocular Lens Implant for Correction of Aphakia in Eyes With No Capsular Support

*First Author: Shah-Noor HASSAN*  
*Co-Author(s): Shahnaz HASSAN*

**Purpose:** The purpose of this study was to evaluate functional and anatomical outcomes of posterior iris claw intraocular lens (IOL) implant for correction of aphakia in eyes with no capsular support.

**Methods:** Prospective case series of 20 aphakic eyes with inadequate capsular support that underwent posterior iris claw IOL with a 3-month follow-up period was conducted. The cases belonged to 2 clinical settings: elective secondary implantation and those with intraoperative posterior dislocation of cataractous lens or IOL. Main outcome measures were visual acuity, anterior chamber reaction, stability of IOL, and intraocular pressure (IOP).

**Results:** The mean best-corrected visual acuity was logarithm of the minimum angle of resolution (logMAR) 0.25. None had chronic anterior chamber inflammation. Two eyes had raised IOP which were managed with medication and did not need laser peripheral iridotomy. There were no IOL dislocations or other adverse events in our series.

**Conclusions:** Posterior chamber iris claw lenses are a good option in eyes with inadequate posterior capsular support. Chronic

inflammation, poor lens stability, or permanent rise of IOP was not observed during the 3-month follow-up period.

### Globe Salvage in a Thrashing Stone Injury

*First Author: Chaitali BHAVSAR*  
*Co-Author(s): Roshan COLACO, Chinmay NAKHWA, Sundaram NATARAJAN, Mohd Anash PATHAN*

**Purpose:** The incidence of pelting vehicles by prowlers has been increasing recently in certain areas of rural India. Such attacks can lead to really severe ocular injuries whose management pose challenges to ophthalmologists.

**Methods:** A 49-year-old male fell victim to pelting by prowlers while traveling by car. His right eye was hit by a large stone measuring 5 × 6 inches. Primary lid repair was done in the local hospital. He presented to our hospital with vision of light perception, a large chemosis temporally, and total hyphema. B-scan showed vitreous hemorrhage, shallow suprachoroidal hemorrhage, and vitreous incarceration in scleral tear at the equator. Computed tomography (CT) scan showed comminuted fracture of the right orbital roof, floor, and medial wall along with ethmoid and maxillary hemosinuses. Primary wound exploration and scleral tear repair was done followed by anterior chamber (AC) wash, dislocated lens aspiration, vitrectomy, drainage of suprachoroidal hemorrhage, and silicone oil injection.

**Results:** Two weeks later with aphakic silicone oil refraction, his vision improved to 6/60.

**Conclusions:** Such road traffic accidents can lead to severe ocular injuries disrupting the whole anatomy. Careful management of cases with a step-by-step approach can result in really good ambulatory vision even in badly injured eyes.

### Incidence of Retinal Detachment After Laser Photocoagulation in Patients With Familial Exudative Vitreoretinopathy

*First Author: Karthik KUMAR*  
*Co-Author(s): Naresh Babu KANNAN, Piyush KOHLI, Kim RAMASAMY*

**Purpose:** To calculate the incidence of retinal





detachment (RD) after laser photocoagulation in patients with familial exudative vitreoretinopathy (FEVR) stage 1.

**Methods:** Records of patients with FEVR stage 1 who underwent laser photocoagulation in the form of peripheral retinal photocoagulation (PRP) or barrage for lattice(s) or tear(s) were retrospectively reviewed. Average follow-up was  $36.6 \pm 36.8$  months (range, 1 week to 17 years).

**Results:** Eighty-five eyes of 63 patients underwent laser photocoagulation. While 53 eyes underwent peripheral retinal photocoagulation, 32 eyes underwent barrage. Twelve eyes (14.1%) of 10 patients developed RD and 2 patients developed bilateral RD. Mean age of patients developing RD was  $14.1 \pm 8.2$  years. Incidence of RD in patients who underwent peripheral retinal photocoagulation and barrage was 11.3% and 18.8%, respectively. While median time between peripheral retinal photocoagulation and RD was 9.5 months, the least time was 1 week. All patients were operated for RD and retina was on at the end of the follow-up. Average number of surgeries required was 1.25.

**Conclusions:** Unlike retinopathy of prematurity, there is a broad spectrum of treatment response to laser in cases of FEVR. Laser may be held responsible in causing RD in an otherwise stable patient.

### Laser Photocoagulation Without Angiography Guidance for Chronic Central Serous Chorioretinopathy

*First Author: Nisita SURYANTO*

*Co-Author(s): Angela Nurini AGNI, Muhammad Bayu SASONGKO, Supanji SUPANJI, Firman Setya WARDHANA, Tri Wahyu WIDAYANTI*

**Purpose:** To present a case of chronic central serous chorioretinopathy (CSC) and its management.

**Methods:** This was a descriptive study.

**Results:** A 43-year-old male presented with CSC documented by optical coherence tomography (OCT). Visual acuity was 1.0 and 0.3 in right

and left eyes, respectively. Acetazolamide 250 mg 2 times per day was given as treatment. Two months later, visual acuity in the left eye decreased to 0.05. Exudates appeared near the retinal superior vascular arcade. OCT revealed enhancement of subretinal fluid at the macula. Angiography could not be performed due to lack of facility. Grid laser photocoagulation was performed near the exudates using 100 mJ energy with exposure time of 0.05 seconds. On follow-up, visual acuity had improved to 0.2 at 1 week and 0.5 at 3 weeks. OCT also revealed a significant reduction of subretinal fluid at the macula.

**Conclusions:** We present a case of chronic central serous chorioretinopathy. Laser photocoagulation performed based on exudates at the retina might improve visual acuity and reduce subretinal fluid.

### Malignant Glaucoma: Management by Vitrectomy

*First Author: Umesh BHAMMARKAR*

**Purpose:** To describe the clinical presentation of malignant glaucoma and its management in 2 case reports.

**Methods:** Two patients in the immediate postoperative period developed classic clinical signs of malignant glaucoma. They were managed accordingly, with both conservative treatment initially and surgical approach (pars plana vitrectomy).

**Results:** The patients underwent combined surgery of pars plana vitrectomy and iridectomy. Postoperatively, the anterior segment become normal and corneal edema was gone. Vision improved and intraocular pressure (IOP) returned to normal levels.

**Conclusions:** Malignant glaucoma remains one of the most challenging complications of ocular surgery. Early recognition and treatment is essential for good visual prognosis.





## Management of Foveal Detachment Secondary to Intrachoroidal Cavitation With Vitrectomy and Capsular Membrane Transplantation

First Author: Chi Wai **TSANG**

Co-Author(s): Lai Man **WONG**

**Purpose:** To report the visual and anatomical outcomes of a patient with foveal detachment secondary to intrachoroidal cavitation after vitrectomy and capsular membrane transplantation.

**Methods:** A 53-year-old woman with high myopia of -10.0 diopters bilaterally presented to us with progressive blurring of left eye vision. Physical examination revealed subretinal fluid over the left macula. Optical coherence tomography (OCT) scans showed subretinal hyperreflective deposits in addition to subretinal fluid. Detailed assessment of OCT scans revealed peripapillary intrachoroidal cavitation and a direct communication between the choroidal cavitation and the vitreous cavity at the region around the temporal margin of the optic disc. Fundus fluorescein angiography (FFA) did not show any leakage accounting for the subretinal fluid accumulation. Phacoemulsification with insertion of intraocular lens, 23G pars plana vitrectomy (PPV), anterior capsular membrane transplantation (ACMT), and autologous blood injection to retinal defect at the optic disc were performed when the absence of spontaneous improvement was confirmed after 6 months of observation.

**Results:** The operation was uneventful; serial OCT scans and visual acuity measurements were used to monitor the progress. The foveal subretinal fluid was noted to reduce with time after the operation, and complete resolution of foveal detachment with recovery of the outer retinal layers (including external limiting membrane, ellipsoid zone, and interdigitation zone) on OCT were documented 18 months postoperatively. Her best corrected visual acuity (Snellen) improved from 0.7 preoperatively to 1.0 18 months postoperatively.

**Conclusions:** PPV with ACMT and autologous

blood injection to retinal defect could be a promising solution to foveal detachment associated with intrachoroidal cavitation.

## Management of Retained Intraocular Foreign Body by Pars Plana Vitrectomy

First Author: Pankaj **ROY**

**Purpose:** The objective of the study was to evaluate the structural and functional outcome of retained intraocular foreign body located in the posterior segment.

**Methods:** This prospective study was conducted from January 2014 to June 2017. Sixty-four consecutive eyes of 64 patients were included in the study. The mean age was  $26.34 \pm 9.40$  years, with an age range of 16-41 years. There were 60 males and 4 females who underwent pars plana vitrectomy. Visual acuity, slit lamp biomicroscopy, intraocular pressure (IOP), posterior segment examination, B-scan, and computed tomography (CT) scan of the orbit were done for all cases.

**Results:** Size of removed metallic foreign body ranged from 4-16 mm. Preoperative visual acuity included no perception of light in 2 eyes, only perception of light in 4 eyes, perception of light and projection of rays in 16 eyes, counting fingers at one half meter in 20 eyes, counting fingers at one half meter to 1/60 in 16 eyes, 2/60 to 5/60 in 4 cases, and 6/60 in 2 eyes ( $P = 0.003$ ). Anatomic success was obtained in 96.77% (62) of eyes. The postoperative visual acuity improved  $5.24 \pm 3.4$  letters on the Snellen visual acuity chart. Severe inflammation was noticed in 24 (37.5%) eyes in the early postoperative period, IOP elevated in 26 (40.63%) eyes, 1 silicone oil filled eye developed band keratopathy, and 1 eye became phthisical.

**Conclusions:** Pars plana vitrectomy is an important, effective, and essential surgical approach for maintaining ocular integrity and better functional outcome.





### Management of Uveal Effusion Syndrome in a Hypermetropic Eye: A Case Report

First Author: Shah-Noor **HASSAN**

Co-Author(s): Shahnaz **HASSAN**

**Purpose:** To report a case of uveal effusion syndrome and its management in a hypermetropic eye.

**Methods:** A 35-year-old male presented with decreased vision in the right eye. Fundus examination revealed 360-degree choroidal detachment with shallow exudative retinal detachment in the right eye. Axial length was 21 mm in both eyes. He was initially treated with systemic steroid but rather showed deterioration of vision over time in the right eye. Then 4 quadrant partial thickness sclerectomy with sclerostomy and SF<sub>6</sub> gas implant was done in the right eye as initial surgical procedure. Full thickness sclerectomy in a single quadrant with C3F<sub>8</sub> gas implant was done in a subsequent procedure.

**Results:** Visual acuity showed minimal improvement in partial thickness sclerectomy with sclerostomy. Visual acuity markedly improved with anatomical improvement of fundus picture in full thickness sclerectomy.

**Conclusions:** Surgical intervention is the choice of treatment in uveal effusion syndrome with hypermetropia. Full thickness sclerectomy might achieve the final outcome when partial thickness sclerectomy with sclerostomy fails.

### On-Table Macular Hole Closure Precludes Unnecessary Expansible Gas Tamponade and Head Positioning

First Author: Dipak **NAG**

Co-Author(s): Rinku **PAUL**, Pankaj **ROY**

**Purpose:** Standard treatment of macular hole is vitrectomy combined with expansible gas tamponade and proper head positioning. However, expansive gas is costly and often not free from side effects. Postoperative face down positioning is also sometimes punishing and exhausting. We tried to effect macular hole closure on the operating table and to

determine whether it persisted on subsequent postoperative follow-up.

**Methods:** The surgical procedure consisted of standard pars plana vitrectomy, removal of posterior cortical vitreous, peeling of the internal limiting membrane around the macular hole, closure of the hole using the tip of the soft tip, and a total air-fluid exchange. No face down positioning was advised postoperatively. The successful closure of the macular hole was defined as a postoperative biomicroscopic appearance in which the rim of the macular hole disappeared and on optical coherence tomography (OCT) there was no interruption in the continuity of foveal tissue above the retinal pigment epithelial layer after the surgery.

**Results:** Five eyes with stage 2 and 3 macular hole underwent surgery. Successful closure of the macular hole was found in postoperative biomicroscopic appearance and on OCT 15 days and 1 month after surgery. No remarkable complication was recorded perioperatively and during the follow-up periods.

**Conclusions:** Macular hole can be closed perioperatively without expansible gas and head down positioning.

### Outcome of Pars Plana Vitrectomy for Intraocular Foreign Body: Hospital-Based Study

First Author: Rajya **GURUNG**

**Purpose:** To find the outcomes of pars plana vitrectomy for intraocular foreign body (IOFB).

**Methods:** We retrospectively reviewed the medical charts of 31 consecutive patients who underwent 3-port pars plana vitrectomy (PPV) with/without pars plana lensectomy or cataract surgery with IOFB removal.

**Results:** Twenty-nine males and 2 females with a mean age of 28 years were evaluated. Cornea was the most common site of entry seen in 77.4% of patients. The location of IOFB was retinal in 26 patients, vitreous cavity in 4 patients, and subretinal in 1 patient. The most common surgery performed was PPV with



Cat, with IOFB removal with SOI done in 15 patients. Metallic foreign body was the most common foreign body seen in 24 eyes (77.4%). The largest foreign body was 12 mm in size. In the majority of eyes (29, 93.5%), PPV was done 7 days after ocular trauma. Thirteen eyes (42%) had postoperative best corrected visual acuity (BCVA) better than 20/200.

**Conclusions:** There was a statistically significant improvement in vision after pars plana vitrectomy and IOFB removal even though in the majority of patients PPV was done 7 days after trauma.

### **Pneumoretinopexy With Subretinal Fluid Drainage in Treatment of Bullous Rhegmatogenous Retinal Detachment**

*First Author: Diva MISRA*

*Co-Author(s): Pritam BAWANKAR, Ronel SOIBAM*

**Purpose:** To describe the functional and anatomical outcomes of pneumoretinopexy with subretinal fluid drainage in treatment of bullous rhegmatogenous retinal detachment (BRRD).

**Methods:** Twenty-one eyes with BRRD were included in the study. Under local anesthesia, peritomy of about 3-4 mm was made radial to limbus in the dependent area of detachment, then subretinal fluid (SRF) was drained externally and cryotherapy was applied around the breaks. After that, 0.3 mL of C3F8 gas was injected in the vitreous cavity and patients were advised to maintain the position depending on position of the break.

**Results:** There were 14 males and 7 females; duration ranged from 1 week to 3 months. Ten patients were myopic, 6 hyperopic, and 5 were emmetropic. All patients had superior break between the 10 to 2 o'clock position except one who had a break at 3 o'clock. Recurrence was noted in 5 eyes by the end of 1 month. In 4 out of these 5 eyes, a new break was noted at a different position from the old break leading to redetachment of retina and 1 patient had preexisting PVR changes. We tried this method of SRF drainage in pneumoretinopexy, due

to which even bullous RD could be resolved without major surgery.

**Conclusions:** This novel method can be tried in patients presenting with bullous rhegmatogenous retinal detachment with superior break. This not only eliminates the need for surgery and reduces the financial burden but is very safe and effective, too. Better results are seen if duration of detachment is less.

### **Postoperative Refractive Errors After Posterior Capsulectomy During Combined Vitrectomy and Cataract Surgery**

*First Author: Moosang KIM*

**Purpose:** To evaluate the difference between the predicted and actual postoperative refractions after combined vitrectomy and cataract surgeries with a posterior capsulectomy.

**Methods:** We performed a retrospective study of 33 eyes of 33 patients who underwent combined vitrectomy and cataract surgeries. The patients were divided into 2 groups: those who underwent a posterior capsulectomy (group A) and those who underwent combined vitrectomy and cataract surgeries (group B). The actual refractive errors were analyzed 3 months after surgery using spherical equivalent. We compared the results between the predicted and actual refractive errors in the 2 groups.

**Results:** Group A consisted of 25 eyes of 25 patients and group B of 8 eyes of 8 patients. In group A, the average difference between predicted and actual postoperative refractive errors was  $-0.16 \pm 0.38$  diopters (D) ( $P = 0.083$ ). The predicted refraction was  $-0.33 \pm 0.46$  D and actual refraction was  $-0.49 \pm 0.55$  D in group A. There was no statistically significant difference between the predicted refraction and actual refractive errors in group A ( $P = 0.083$ ). In group B, the average difference between predicted and actual postoperative refractive errors was  $0.27 \pm 0.29$  D ( $P = 0.078$ ). Additionally, the predicted refraction was  $-0.49 \pm 0.77$  D and actual refraction was  $-0.22 \pm$





0.59 D. The difference between the predicted refraction and actual refractive errors in group B was not statistically significant ( $P = 0.078$ ).

**Conclusions:** When a posterior capsulectomy is performed during combined vitrectomy and cataract surgery, no significant difference in refractive errors between the predicted refraction and actual refractive errors was observed 3 months after surgery.

### Protruding Retinal Hemangioma: A Case Report

*First Author: Farida SELVIANA*

*Co-Author(s): Angela Nurini AGNI, Arya PRADIPTA, Mohammad Eko PRAYOGO, Tri Wahyu WIDAYANTI*

**Purpose:** To report the clinical case of a 9-year-old-girl who presented with a protruding mass in her left eye since birth. Initial differential diagnosis was retinoblastoma; ancillary examination was done and enucleation performed. Histopathological examination revealed that the tumor was retinal cavernous hemangioma with capillary hemangioma. The presenting signs were unusual.

**Methods:** A case report.

**Results:** A 9-year-old girl had a mass protruding from her left eye since she was born. The visual acuity was no light perception in her left eye. From the examination, we found a bulging mass with involvement of ocular tissues and loss of anterior and posterior segment of the eye. Ultrasonography showed hyperechoic mass inside the eye without calcification. The computed tomography (CT) scan found a hyperdense intraocular mass measuring  $2.7 \times 2.6 \times 2.6$  cm, with calcified area and no expansion to the retrobulbar, extraocular muscles, nor the optic nerve. Enucleation was performed. Histopathology confirmed the diagnosis was retinal cavernous hemangioma with capillary hemangioma.

**Conclusions:** The intraocular space is an uncommon site of cavernous hemangioma, yet in this patient we found a case arising from said location. The CT scan showed similar appearance to retinoblastoma with calcification.

From this report we concluded that cavernous hemangioma can be considered as a differential diagnosis of intraocular tumor.

### Report on the Use of Iris-Claw Lens for Aphakia Correction Following Vitrectomy or Vitreolensectomy

*First Author: Yen Harn YEW*

*Co-Author(s): Stewart LAKE, Suthet MON*

**Purpose:** This study aimed to evaluate the 3-month postoperative visual outcome and complications in the use of iris-fixated anterior chamber intraocular lens (iris-claw lens) in patients with poor capsular support following vitrectomy or vitreolensectomy.

**Methods:** Retrospective review of cases performed by a single consultant in a tertiary public hospital.

**Results:** Twenty-one eyes of 19 patients aged 15 to 84 years old who underwent iris-claw lens implantation with either anterior or pars plana vitrectomy between January 2013 and August 2016 were studied. Indications for surgery included traumatic aphakia (3 cases), subluxed crystalline lens (11 cases), and subluxed acrylic intraocular lens (7 cases). Although 59% of patients recorded better best corrected logarithm of the minimum angle of resolution (logMAR) visual acuity (BCVA) at 3 months postoperatively, mean BCVA dropped from  $0.64 \pm 0.45$  to  $0.60 \pm 0.67$ . Two cases that suffered corneal complications unrelated to the use of the iris-claw lens resulted in the skewed data. Excluding those 2 cases, mean BCVA was found to be  $0.71 \pm 0.54$  preoperatively and  $0.45 \pm 0.38$  postoperatively ( $P = 0.038$ , Wilcoxon signed rank test). Other complications encountered were hyphema and cystoid macula edema, which were transient.

**Conclusions:** Iris-claw lens is an effective and safe technique to visually rehabilitate aphakic eyes following vitreous removal.





### Schwartz-Matsuo Syndrome in a Patient With Secondary Open-Angle Glaucoma Due to Chronic Atopic Eczema

First Author: Shee Win **CHUA**

Co-Author(s): Mae-Lynn **BASTION**

**Purpose:** To report the rare occurrence of elevated intraocular pressure (IOP) in rhegmatogenous retinal detachment (RRD) in a patient with secondary open-angle glaucoma and atopic dermatitis.

**Methods:** Retrospective case report.

**Results:** A 37-year-old man had chronic atopic dermatitis. His ocular history included bilateral cataract surgery, steroid-induced glaucoma, right eye amblyopia, and left eye successful retinal detachment surgery 10 years prior. His IOP was well controlled on 4 topical medications. He presented with right eye nasal field defect for 2 months. Vision was 6/36 in the right eye (OD) and 6/9 in the left (OS). IOP was 14 mm Hg and 16 mm Hg, respectively. Dilated right fundus examination showed a superior-temporal tear with RRD bisecting the macula. On admission, IOP was elevated at 32 mm Hg bilaterally despite compliance with medication. Right eye angles were open with anterior chamber cells 2+ and grade 1 vitreous haze. He underwent right trans pars plana vitrectomy, endolaser, cryotherapy, and gas injection. IOP postoperatively was 23 mm Hg OD. He received oral acetazolamide 250 mg 4 times per day, G brimonidine 2 times per day, and G timolol 2 times per day in addition to routine postoperative eye drops. At subsequent follow-up on postoperative day 4, right eye IOP was 24 mm Hg.

**Conclusions:** Schwartz-Matsuo syndrome, whereby elevated IOP is encountered during RRD rather than hypotony, may be expected in young individuals with atopic dermatitis and secondary glaucoma. IOP control is important to prevent irreversible glaucomatous optic neuropathy after successful surgical repair. Similarly, in the presence of elevated IOP and intraocular inflammation in retinal detachment, a tear must be excluded.

### Significant Reduction of Both Peripapillary and Subfoveal Choroidal Thickness After Panretinal Photocoagulation in Patients With Type 2 Diabetes

First Author: Hae Min **KANG**

Co-Author(s): Hyoung Jun **KOH**, Na Eun **LEE**, Sung Chul **LEE**

**Purpose:** To evaluate changes in peripapillary choroidal thickness (PCT) and subfoveal choroidal thickness (SFCT) after panretinal photocoagulation (PRP) for diabetic retinopathy (DR).

**Methods:** This retrospective interventional study included 59 treatment-naïve eyes of 33 patients who underwent PRP and completed  $\geq 12$  months follow-up. PCT and SFCT were measured at baseline and 1, 3, 6, and 12 months after PRP. Differences between baseline and 12 months ( $\Delta$ SFCT and  $\Delta$ PCT) and percentage changes ( $\Delta$ SFCT or  $\Delta$ PCT/baseline  $\times 100\%$ ) were determined.

**Results:** Mean SFCT was  $287.7 \pm 76.7 \mu\text{m}$  (139.0 to 469.0  $\mu\text{m}$ ) at baseline and  $225.8 \pm 62.0 \mu\text{m}$  (102.5 to 379.5  $\mu\text{m}$ ) 12 months after PRP ( $P < 0.001$ ). Mean PCT was  $161.2 \pm 16.5 \mu\text{m}$  (75.3 to 308.1  $\mu\text{m}$ ) at baseline and  $128.4 \pm 41.8 \mu\text{m}$  (73.0 to 212.9  $\mu\text{m}$ ) 12 months after PRP ( $P < 0.001$ ).  $\Delta$ SFCT was  $-61.3 \pm 28.7 \mu\text{m}$  ( $-139.5$  to  $-17.0 \mu\text{m}$ ) and %SFCT was  $21.2 \pm 7.2\%$  (6.8% to 36.1%).  $\Delta$ PCT was  $-36.4 \pm 23.2 \mu\text{m}$  ( $-149.1$  to  $5.4 \mu\text{m}$ ) and %PCT was  $22.4 \pm 12.0\%$  (2.5% to 62.6%). DR severity was the only factor significantly correlated with %SFCT ( $b = 0.500$ ,  $P = 0.004$ ) and %PCT ( $b = 0.152$ ,  $P = 0.024$ ).

**Conclusions:** Both PCT and SFCT reduced significantly after PRP. DR severity was significantly correlated with post-PRP changes of peripapillary and subfoveal choroidal thickness.

### The Feasibility and Efficacy of Intraoperative Laserpexy in Scleral Buckling Surgery

First Author: Roshija **RIJAL**

Co-Author(s): Deepesh **MOURYA**

**Purpose:** This study was done to assess





the feasibility and efficacy of intraoperative laserpexy in scleral buckling surgery.

**Methods:** Records of 25 patients who had undergone intraoperative laserpexy during scleral buckling were retrospectively analyzed.

**Results:** All patients were phakic and the macula was off in all cases. Adequate intraoperative laserpexy was achieved in 22 (88%) patients. Three (12%) patients required additional postoperative laser. Retina was attached in all patients at 3 months of follow-up.

**Conclusions:** Intraoperative laserpexy can give comparable results to cryopexy with lesser postoperative complications in scleral buckling surgery. Although further comparative studies are needed, this study establishes the feasibility of intraoperative laserpexy in scleral buckling, which has never been described before in literature as per our knowledge.

### Three Cases With Primary Scleral Buckling Following Open Globe Injuries

First Author: Shoyo **YOSHIMINE**

Co-Author(s): Kota **ARAI**, Kei **MIZOBUCHI**, Tadashi **NAKANO**, Ryo **TERAUCHI**, Akira **WATANABE**

**Purpose:** We describe favorable outcomes in 3 patients with open globe injuries who underwent primary scleral buckling.

**Methods:** We retrospectively investigated the patients' ocular trauma score (OTS), mechanism of injury, and progress, including visual acuity and anatomical outcome, from their medical records.

**Results:** Case 1: A 58-year-old man presented with rupture of his right eye due to a fall; his OTS score was 3 and visual acuity (VA) was 20/50. He was treated by primary scleral buckling and scleral wound closure. He secondarily received pars plana vitrectomy (PPV) with silicone oil tamponade and intraocular lens (IOL) implantation. Subsequently, his VA improved to 20/20. Case 2: A 37-year-old man suffered an injury of the right eye while doing construction work. His VA was 30 cm finger

counting. Computed tomography revealed a ruptured eye (OTS score 2). He underwent primary scleral buckling and scleral wound closure. Subsequent surgical treatment included PPV, lensectomy, and silicone oil tamponade. Thereafter, his VA improved to 20/40. Case 3: A 47-year-old man was injured while doing construction work and presented to us with a nail embedded in his eye. His VA was 20/500. Computed tomography revealed 2 perforations (OTS score 2). The nail was removed and he was treated by primary scleral buckling and scleral wound closure. He secondarily underwent PPV with silicone oil tamponade and IOL implantation, following which his VA improved to 20/100.

**Conclusions:** These cases confirm the favorable outcomes that can be achieved using primary scleral buckling in patients with open globe injuries with relatively low OTS scores.

### Utility of Microscope-Integrated Optical Coherence Tomography in the Treatment of Myopic Macular Hole Retinal Detachment

First Author: Prateek **KAKKAR**

Co-Author(s): Atul **KUMAR**, Pradeep **KUMAR**, R **KARTHIKEYA**, Raghav **RAVANI**

**Purpose:** To describe the utility of microscope-integrated optical coherence tomography (MIOCT) guided complete removal of posterior vitreous cortex (PVC) and internal limiting membrane (ILM) peeling with multilayered inverted ILM flap in the treatment of myopic macular hole retinal detachment.

**Methods:** A case of myopic macular hole retinal detachment (MMHRD) was diagnosed and underwent 23G pars plana vitrectomy (PPV). MIOCT was used to analyze the edges of the macular hole that showed presence of fine posterior vitreous attachment that was clinically not visible. It also helped to identify the complete removal of PVC in real time. An inverted ILM flap was peeled using MIOCT and an inverted flap was placed over the macular hole. An endotamponade was done using perfluorooctane gas.





**Results:** Intraoperative complete removal of posterior vitreous cortex was identified. Postoperatively the patient had a type 1 macular hole closure with gain in visual acuity. After 1 month the hole was closed with retina flat.

**Conclusions:** Pars plana vitrectomy with real-time MIOCT monitoring plays a critical role in treatment of patients with myopic macular hole. MIOCT helps to confirm the ILM peeling with proper placement of inverted ILM flaps in such cases.

### Visualization of the Posterior Vitreous Fluid Space Using Indocyanine Green During Vitreous Surgery in Proliferative Diabetic Retinopathy

*First Author: Takeshi MIYAMOTO  
Co-Author(s): Ai IZUTANI, Shin MIZOGUCHI, Masaki NAKAGAWA, Yukihisa TAKADA*

**Purpose:** To describe a technique of visualization of the posterior vitreous fluid space with indocyanine green (ICG) during vitreous surgery in proliferative diabetic retinopathy (PDR).

**Methods:** Five eyes (4 patients) underwent a vitreoretinal procedure using a 25-gauge 3-port system to treat PDR with incomplete posterior vitreous detachment (PVD). After core vitrectomy, a small hole was made in the posterior vitreous membrane with vitreous cutter. Through the hole, 0.5% ICG solution was injected to the posterior vitreous fluid space. After membrane recession, vitrectomy was completed. In some cases with retinal detachment, 20% SF<sub>6</sub> gas tamponade was performed.

**Results:** Injection of ICG to the posterior vitreous fluid space makes it easy to recognize the range of PVD and presence of proliferative membrane, even minor neovascularization, with the contrast of ICG and fibrous proliferative membrane. In some cases, ICG injection caused enlargement of PVD. In all cases, no complications like iatrogenic retinal break occurred during vitreous surgery.

**Conclusions:** This technique, visualization of the posterior vitreous fluid space by ICG injection, makes it easy to detect proliferative membrane, even minor epicenter, with the color contrast by fibrotic change and ICG. This technique may useful to prevent/reduce iatrogenic retinal break during vitrectomy for severe proliferative diabetic retinopathy.

### Vitrectomy for Proliferative Diabetic Retinopathy in Medium Myopia: Clinical Features and Surgical Outcomes

*First Author: Masahiko SANO*

**Purpose:** To investigate the clinical manifestations and surgical results after vitrectomy for proliferative diabetic retinopathy (PDR) in medium myopia.

**Methods:** We retrospectively reviewed 253 eyes of 218 patients who received 25-gauge vitrectomy for PDR between January 2012 and March 2016 and were followed postoperatively at least 3 months. The eyes with axial length more than 24.5 mm were classified as the myopia group.

**Results:** There were 46 eyes of 41 patients (18%) in the myopia group and 207 eyes of 177 patients (82%) in the nonmyopia group. The average age at operation was  $51.5 \pm 11.8$  and  $57.3 \pm 11.6$  years old, respectively ( $P < 0.001$ ). The differences in the preoperative and postoperative best-corrected visual acuity (BCVA), preoperative panretinal photocoagulation, status of lens, and severity of PDR [presence of tractional retinal detachment (RD) with or without rhegmatogenous RD, macular detachment, vitreous hemorrhage, and neovascular glaucoma] were not significant between the 2 groups. One hundred fifteen eyes did not have posterior vitreous detachment (PVD), and 16 eyes (35%) were in the myopia group and 99 eyes (48%) were in the nonmyopia group. In the eyes without PVD, the differences in the preoperative and postoperative BCVA, severity of PDR, and postoperative outcomes were not significant between the 2 groups. The incidence of





intraoperative retinal tears was significantly greater in the myopic group (10 eyes, 63%) than the nonmyopic group (34 eyes, 34%) ( $P = 0.03$ ).

**Conclusions:** In the myopia group, the average age at operation was younger and intraoperative retinal tears occurred more in the eyes without PVD than in the nonmyopia group.





## VIDEOS

### Intraocular Inflammation, Uveitis & Scleritis

#### Catch Me If You Can: Motile Subretinal Worm

First Author: Palmeera **DSOUZA**

Co-Author(s): Uendra **BABU**, Nidhee **JAIN**, Mohan **PODILE**, Parag **SHAH**, Prema **SUBBU**

**Purpose:** To describe effective management of a subretinal worm with immediate laser photocoagulation and antiparasitic drugs.

**Methods:** A 57-year-old male patient residing in a coastal area complained of decreased vision in the left eye for 20 days. He was a known diabetic. On examination his best corrected visual acuity was 6/6 in the right eye and 6/24 in the left eye. Intraocular pressure was 17 mm Hg in the right eye and 19 mm Hg in the left eye. Anterior segment examination was normal in both eyes. Fundus examination in the right eye was normal; left eye showed vitreous haze with vitreous cells 3+, retinal pigment epithelial tract lesions in the left superotemporal quadrant with subretinal fluid, greyish-white deep retinal lesions, and subretinal live worm with active motility, probably filarial worm, around 3000 µm. Barrage laser was performed on the worm and around the worm with Nd:YAG laser 532 nm, power 200 mW to 300 mW. At the end of the laser treatment, the live worm was noted. The patient was treated with oral steroids of tapering dosage along with albendazole 400 mg 2 times per day and diethyl carbamazime 100 mg 3 times per day for 21 days.

**Results:** On follow-up after 1 week visual acuity remained the same and the patient was better symptomatically. Vitritis reduced and scarring and pigmentation were noted in the superotemporal area. The dead segmented worm was confirmed on optical coherence tomography (OCT).

**Conclusions:** In patients with vitritis and subretinal scarring careful examination is required to detect live worms so that early

treatment and laser can be done to obtain good results and prevent visual loss.

### Retina (Surgical)

#### 3-Dimensional Guided Vitreoretinal Surgery

First Author: Sankeert **GANGAKHEDKAR**

Co-Author(s): Jay **CHHABLANI**, Vishal **GOVINDHARI**

**Purpose:** Our video presents a compilation of challenging vitreoretinal surgeries using a 3-dimensional (3D) visualization system.

**Methods:** Our vitreoretinal surgeries were performed with NGENUITY 3D heads-up visualization system. TruE Edit was used for editing the videos.

**Results:** The 3D system helped in macular hole surgery for careful internal limiting membrane peeling avoiding any collateral damage; in a case of diabetic retinal detachment, it could differentiate the fibrovascular proliferative membrane from the avascular thin retina, avoiding any inadvertent retinal tears.

**Conclusions:** In comparison to 2-dimensional visualization, operating under a 3-dimensional surgical experience showed better brightness resolution, magnification, and stereopsis.

#### A Novel Surgical Technique to Overcome Pitfalls

First Author: Mariam **DOCTOR**

Co-Author(s): Abhishek **DESAI**, Girish **RAO**

**Purpose:** We report a case of serous macular detachment complicating optic disc pit in a young female treated surgically with internal limiting membrane (ILM) peeling who showed dramatic improvement of vision postoperatively.

**Methods:** Optic disc pit, classified as a congenital excavation of the optic nerve representing a defect in lamina cribrosa, is generally associated with serous macular detachment resulting in decreased visual acuity





(VA) in more than 50% of patients. Existing techniques to plug the optic disc pit involve use of fibrin glue/sclera, which have their own inherent drawbacks. Autologous tissue is the most physiological option for sealing the optic disc pit, creating a permanent barrier to flow of fluid across the pit. The surgical procedure entails standard pars plana vitrectomy with PVD induction. ILM was stained with brilliant blue dye and peeled as a single sheet, with its pedicle attached to the edge of the disc. The peeled ILM was inverted and inserted to seal the optic disc pit. Next a laser PHC along the temporal edge of the pit was performed followed by fluid air exchange and air-C3F8 exchange. The patient was advised prone positioning postoperatively.

**Results:** Best corrected VA of the patient improved from 6/120 preoperatively to 6/24 at the first month and 6/12 at 3 months postoperatively, which was maintained in subsequent follow-ups. Postoperative optical coherence tomography (OCT) examination confirmed sealing of the optic disc pit with autologous ILM.

**Conclusions:** The proposed new technique shows excellent anatomic and VA results and could be a surgery of choice for optic disc pit maculopathy.

---

### Ahmed Glaucoma Valve Surgery in Vitrectomized Eyes: This Is Not the End!

First Author: Bhuvan **CHANANA**

**Purpose:** To describe vision-threatening posterior segment complications and discuss management following Ahmed Glaucoma Valve (AGV) implantation in eyes with previous vitreous surgery.

**Methods:** AGV surgery was performed in 2 vitrectomized eyes with intractable glaucoma. The first case was an 8-year-old boy with angle-recession glaucoma, who had previously undergone pars plana vitrectomy for dense vitreous hemorrhage in his right eye following injury with a cricket ball. The intraocular pressure (IOP) in his right eye was not controlled

despite maximum medical therapy. The second case was a 63-year-old female who underwent vitrectomy in her right eye for nonresolving vitreous hemorrhage following complicated cataract surgery. The best corrected visual acuity (BCVA) was 20/80 and IOP was 42 mm Hg on maximum antiglaucoma drugs and oral acetazolamide.

**Results:** Both eyes had severe hypotony (IOP < 4 mm Hg) on the first postoperative day. The first case developed premacular sub-internal limiting membrane (ILM) bleed, which clotted and became more organized with thickening and wrinkling of the overlying ILM after 4 weeks. In the second patient kissing choroidal detachment developed, which did not resolve with systemic and periocular steroids. Both cases required further surgical intervention. The thick firmly adherent ILM was removed successfully in the first case; and in the second case suprachoroidal fluid was drained using a modified sclerotomy technique.

**Conclusions:** AGV surgery in vitrectomized eyes can lead to severe vision-threatening complications. The absence of vitreous support in such eyes could be the possible cause of sudden decompression and severe hypotony leading to posterior segment complications. Both the cases in our study were managed successfully.

---

### Auro Keratoprosthesis and Pars Plana Vitrectomy: Combined Single-Stage Approach in Treatment of Severe Chemical Injury and Dislocated Nucleus With Retinal Breaks

First Author: Adarsh **NAIK**

Co-Author(s): Anant **BHOSALE**, Venkatapathy **NARENDRAN**, VR **SARAVANAN**

**Purpose:** To present a case of bilateral chemical injury where the left eye was absolute. The right eye was treated by a unique single-stage approach of Auro keratoprosthesis and vitrectomy surgery with silicone oil injection in the same setting.

**Methods:** A 70-year-old male presented with



bilateral tractor oil chemical injury and light perception and projection of rays (PL, PR) vision. He was primarily treated with amniotic membrane graft and episcleral mobilization. The left eye showed scarred cornea with no perception of light due to secondary glaucoma. The right eye showed increased vascularization of the cornea and conjunctivalization with mature cataract. Lensectomy was attempted but could not be completed due to hazy view. In view of progression of corneal pathology, total limbal conjunctival involvement, and lens dislocation, Auro keratoprosthesis with pars plana vitrectomy was planned. This video demonstrates a single-stage surgery where 360-degree peritomy and pannus removal was done; 8.5 mm host trephined. Dislocated lens was removed with vectis. Artificial cornea was sutured. Pars plana vitrectomy was done; horseshoe tear was noted, and endolaser done. Auro keratoprosthesis with donor cornea was sutured. Silicone oil was injected and peritomy sutured.

**Results:** The patient maintained best corrected 6/36 ambulatory vision through 6 months of follow-up with stable keratoprosthesis and attached retina with pink disc.

**Conclusions:** This case highlights the importance of the combined efforts of anterior and posterior segment surgeons in retrieving visual acuity in complicated situations. This surgery helped to rehabilitate a completely blind patient with complex chemical injury to attain ambulatory vision and effective rehabilitation.

### Autologous Internal Limiting Membrane Plug Technique for Treatment of Naive Large Macular Holes

*First Author: Akshay KOTHARI*  
*Co-Author(s): Aditya KELKAR, Hetal MEHTA*

**Purpose:** To examine the anatomical and functional outcome of autologous internal limiting membrane (ILM) plug technique for large macular holes.

**Methods:** Prospective interventional case study

was done on 8 treatment-naive eyes with large macular holes (>400  $\mu\text{m}$  basal diameter). After ILM peeling, a small plug of the free ILM was tucked under the edges of the macular hole with ILM forceps. Postoperative vision and type of macular hole closure was noted at 1 month. Main outcome measures were best corrected visual acuity (BCVA) and type of closure on optical coherence tomography.

**Results:** The mean maximum base diameter was  $1172 \pm 322 \mu\text{m}$ . The mean preoperative BCVA was  $1.46 \pm 0.08$  logarithm of the minimal angle of resolution (logMAR) units and improved to  $0.84 \pm 0.3$  logMAR units at 1 month postoperatively ( $P = 0.01$ ). Type 1 macular hole closure was observed in all eyes and 1 patient developed retinal pigment epithelium atrophy.

**Conclusions:** Autologous internal limiting membrane plug has good anatomical and functional outcomes and can be considered at the time of primary vitrectomy for large macular holes.

### Autologous Serum-Assisted Retinal Free Flap for Refractory Macular Holes

*First Author: Mudit TYAGI*  
*Co-Author(s): Jay CHHABLANI, Raja NARAYANAN, Rajeev R PAPPURU, Vishal RAVAL*

**Purpose:** To describe the surgical technique of autologous serum-assisted retinal free flap for refractory macular holes.

**Methods:** A 59-year-old patient had undergone an internal limiting membrane (ILM) peeling along with a subsequent autologous ILM transplant earlier and had a refractory macular hole for 1 year. Autologous serum was first injected on the macular hole bed and subsequently a retinal free flap was taken from the periphery and placed at the hole site. Subsequently silicone oil was injected.

**Results:** At the 1 week postoperative visit, optical coherence tomography showed a distinct hyperreflective graft and a closed macular hole. At 1-month follow-up, the retinal graft was still in place though it had contracted





in size. However, the patient's visual acuity had improved to a Snellen equivalent of 20/80. Silicone oil removal was done at 3 months. Postoperatively the graft was in place; however, it had contracted in size and the inferior edge of the hole was exposed. The patient's visual acuity had improved to 20/80 at the end of 3 months.

**Conclusions:** We believe that the autologous serum-assisted retinal free flap technique holds promise for refractory macular holes. However, we need further long-term follow-up of these cases. In view of the subsequent graft contraction, a larger graft size is advocated and autologous serum is helpful in stabilizing the graft.

### Complex Diabetic Combined Retinal Detachment Repair: 3D Visualization

First Author: Jay **CHHABLANI**

Co-Author(s): G **SANKEERT**, Vishal **GOVINDHARI**

**Purpose:** To demonstrate a case of complex diabetic combined retinal detachment repair using a 3-dimensional (3D) visualization system.

**Methods:** Careful delamination and segmentation of the fibrovascular proliferative membrane has been shown. After completion of membrane peeling, preretinal hemorrhage was removed. Fluid-fluid exchange followed by fluid-air exchange was performed. Persistent subretinal fluid could be easily visualized using the 3D system, which was removed to achieve retinal reattachment.

**Results:** The 3D system helped to differentiate the fibrovascular proliferative membrane from the avascular thin retina, avoiding any inadvertent retinal tears.

**Conclusions:** The advantages of the 3-dimensional system over the conventional 2-dimensional system include immersive view, better contrast sensitivity, crisp clear imagery, excellent detail detection avoiding collateral damage, greater field of view, better resolution in the periphery, lesser illumination, and better ergonomics.

### Extreme Trauma: Repairing an Eye Damaged in a Road Traffic Accident

First Author: Chinmay **NAKHWA**

Co-Author(s): Mohd Anash **PATHAN**

**Purpose:** To describe the surgical interventions and management performed to repair a globe traumatized in a road traffic accident (RTA).

**Methods:** A 32-year-old man was injured in a road traffic accident with multiple facial, ocular, and cranial injuries. The right side had an orbital fracture. A scleral laceration extending 17 mm posteriorly from the muscle ring, with total hyphema and retinobulbar detachment, was noted. The patient was monitored in intensive care (ICU) for his intracranial injuries. After stabilization, the open globe (scleral) injury was repaired primarily. A week later, vitrectomy with silicone oil injection was carried out under general anesthesia to repair the retina and posterior segment.

**Results:** The anatomical integrity of the globe was maintained at 4 months postoperatively with normal intraocular pressure (IOP). The patient had ambulatory peripheral vision in that eye. Central vision was limited due to a macular scar.

**Conclusions:** Cases of RTA may require a multispecialty approach for management. Repair of the primary wound should be done as early as possible. We performed a retinal procedure within a week with good anatomical and functional results. Timely surgical intervention with the use of modern tamponades like heavy silicone oil can be a useful tool in salvaging eyes that are severely injured.

### Fold Unfolded

First Author: Naresh **KANNAN**

**Purpose:** Macular fold is one of the rare complications following retinal detachment (RD) surgery whereby the final visual outcome is severely compromised despite an attached retina. Our purpose is to present a video on macular fold following RD surgery and its





management.

**Methods:** A 53-year-old male had developed retinal detachment in his left eye associated with a giant retinal tear. He was initially managed with vitrectomy, perfluorocarbon (PFCL) injection, endolaser, and a complete fluid/gas exchange. Postoperative examination had disclosed slippage of the retina and the formation of a macular fold centered at the fovea. The best corrected visual acuity (BCVA) of the patient did not improve beyond 4/60 and the patient was referred to us for further management. The case was then managed by surgically inducing a redetachment of the retina by injecting balanced saline solution into the subretinal space through a 41-gauge cannula in 4 quadrants, releasing the macular fold with PFCL, peeling of internal limiting membrane, endolaser, and silicone oil tamponade. Silicone oil was removed 3 months later.

**Results:** The patient has been on a regular follow-up for the subsequent 4 years and his BCVA is maintained at 6/12 in the operated eye. Macular fold was successfully unfolded with good improvement in vision.

**Conclusions:** Macular folds are a serious but underreported complication of retinal detachment surgery and very few cases of successful surgical management have been reported to date. We intend to present a fine surgical demonstration of its successful management through our video.

### Heavy Silicone Oil and Microincision Vitrectomy Surgery: Keep It Small Throughout the Journey

*First Author: Ainal Adlin NAFFI*

*Co-Author(s): Mushawiahti MUSTAPHA*

**Purpose:** To demonstrate the technique of heavy silicone oil removal using a 25G cannula.

**Methods:** Video.

**Results:** Heavy silicone oil has introduced a new phase for vitrectomy and, most importantly, better posturing options for the patient. Among the challenges faced dealing

with heavy silicone oil is during its removal. Various techniques were described in removing heavy silicone oil.

**Conclusions:** The best option is to preserve the use of small-gauge instruments even during its removal.

---

### Managing the Vitreoretinal Interface in Diabetic Vitrectomy: Different Case Scenarios

*First Author: Bhuvan CHANANA*

**Purpose:** To demonstrate management of the vitreoretinal interface in proliferative diabetic retinopathy.

**Methods:** The posterior hyaloid phase in proliferative diabetic retinopathy (PDR) is usually thick, taut, and firmly adherent to the underlying retina at multiple sites. Induction of posterior vitreous detachment (PVD) is often difficult due to strong attachments at the disc, areas of neovascularization, and frequent presence of vitreoschisis. Advances in vitreous surgery like microincision vitrectomy systems, better viewing devices, and careful dissection techniques have made it possible to manage such difficult cases.

**Results:** Video clips demonstrating successful PVD induction in difficult situations, management of dense subhyaloid hemorrhage in PDR, dissection of thick and firmly adherent fibrovascular fronds in advanced end-stage PDR, and use of perfluorocarbon liquids (PFCL) during diabetic vitrectomy will be presented.

**Conclusions:** The posterior hyaloid phase in PDR is usually thick and firmly adherent to the underlying retina at multiple sites. However, with the microincision vitrectomy system, advanced instrumentation, and careful dissection techniques, most of the cases can be managed successfully.

---

### Needle Drainage of Subretinal Fluid in Scleral Buckling: A Novel Technique

*First Author: Pradeep SUSVAR*

**Purpose:** This video aims to show a different and simple technique of draining subretinal





fluid (SRF) during scleral buckle surgery for retinal detachments.

**Methods:** Direct and bevelled entry into the sclera with 23-G hypodermic needle after taking the anchoring scleral suture, prior to or after the buckle placement, thereby allowing the SRF to drain externally.

**Results:** The SRF drainage was both continuous and well controlled from the drainage site. The technique did not have any complications that are commonly noted in other methods like the scleral dissection technique and draining through the choroidal knuckle. This technique could be reattempted in the same area multiple times without significant complications like choroidal bleeding and the need to look for another location.

**Conclusions:** This technique of SRF drainage is simple with fewer complications. The ease of performing it is complimented with the advantage of multiple times of entry in the same or adjacent areas in the same quadrant without significant complications. The technique can be a useful aid for young surgeons who tend to be safer in their scleral buckle surgeries.

### Pars Plana Vitrectomy With Angioma Excision in a Patient of Von Hippel-Lindau Syndrome With Rhegmatogenous Retinal Detachment

*First Author: Mohit DOGRA*

**Purpose:** To describe the critical steps in the surgical management of these patients.

**Methods:** A 1-eyed von Hippel-Lindau (VHL) syndrome patient who developed rhegmatogenous retinal detachment in his seeing eye was operated on and angioma excision with settling of the detachment are shown in the video.

**Results:** Retinal reattachment with attainment of ambulatory vision was achieved in our patient after the second surgery.

**Conclusions:** Meticulous planning, excision of all retinal angiomas, and long-term tamponade with gas/silicone oil can help

achieve satisfactory outcomes in patients of VHL syndrome with rhegmatogenous retinal detachment.

### Pearl in the Oyster!

*First Author: Krishnendu NANDI*

*Co-Author(s): Partha BISWAS*

**Purpose:** To report the surgical management of an Ozurdex implant into the crystalline lens in diabetic macular edema. A known diabetic patient reported with diabetic macular edema and nonproliferative diabetic retinopathy in both eyes with baseline vision of 6/18, N 12 in the right eye and 4/60, N 24 in the left eye. The patient was advised to receive Ozurdex in both eyes. Injection was given in the left eye first.

**Methods:** Ozurdex implant was misdirected into the crystalline lens instead of the vitreous cavity. The patient then received phacoemulsification with intraocular lens implantation along with vitrectomy with posterior vitreous detachment (PVD) induction.

**Results:** It was a challenge to preserve the Ozurdex implant while performing phacoemulsification and vitrectomy. The case was managed successfully and the implant was placed in the vitreous cavity.

**Conclusions:** To the best of our knowledge, such a case has never been reported before.

### Plugging All Loopholes: Surgically Managing Optic Nerve Head Colobomas With Retinal Detachment

*First Author: Ramachandran NAIR*

**Purpose:** This video demonstrates a potential modification to assist in the surgical management of retinal detachments associated with optic nerve head colobomas.

**Methods:** Vitreous surgery with silicone oil endotamponade was performed for a retinal detachment associated with a optic disc coloboma. Four weeks after vitreous surgery with silicone oil tamponade, the patient presented with a large nasal retinal detachment with schitic changes at the fovea.





On resurgery, intraoperatively it was noted that the detachment was due to subretinal silicone oil and the likely point of seepage was the defect in the coloboma edge. A large retinectomy was done to remove the subretinal oil and subsequently after a fluid-air exchange, fibrin glue was dropped inside the coloboma in an attempt to achieve temporary closure of the defect while the retina reattached. Sufficient endolaser was also done for retinopexy. Repeat silicone oil endotamponade was performed.

**Results:** The fibrin glue absorbed in 2 weeks as demonstrated by optical coherence tomography (OCT). Retinal reattachment was attained for more than 6 months; however, small persistent pockets of subretinal oil persisted. Fresh subretinal oil migration was prevented.

**Conclusions:** The use of silicone oil in patients with colobomas and retinal detachments may cause migration of the silicone oil through the defect in the edge and lead to subretinal oil. The temporary use of fibrin glue may assist in blocking this seepage till retinal reattachment occurs.

---

### Primary Posterior Vitreocapsulorrhexis in IOFB: A New Method, 23G All the Way

*First Author: Nivean MADHIVANAN  
Co-Author(s): Nidhee JAIN, Pratheeba Devi NIVEAN, Nishanth RADKE, Veena RAVEENDRAN, Sangeetha SEKARAN*

**Purpose:** Retained intraocular foreign body (IOFB) is a leading cause of ocular morbidity in young patients. The morbidity results from the mode of injury, the site of injury, and its associated complications such as endophthalmitis, siderosis, and so on. Hence, managing these cases appropriately is essential for good visual outcomes.

**Methods:** We present a case of retained metallic intraocular foreign body involving the macular region in a young patient. Various methods can be employed for the removal of foreign body. We showcase a novel technique of 23G pars plana vitrectomy along with

phacoemulsification of the lens and creation of a primary posterior vitreocapsulorrhexis through which the foreign body was brought into the anterior chamber and removed through the phacoemulsification clear corneal tunnel. A new extended depth of focus (EDOF) posterior chamber intraocular lens (IOL) was then placed in the bag for good range of vision in the young patient.

**Results:** This patient did well postoperatively and regained useful vision because of the minimally invasive surgery and the EDOF IOL helping in visual performance. The loss of vision from the primary injury was in the macular region. We have followed the patient with a series of postoperative fundus and optical coherence tomography (OCT) images.

**Conclusions:** This unique sutureless technique maximizes the postoperative visual recovery for the patient with minimal tissue trauma and good surgical outcomes in a single surgery.

---

### Ring of Broken Promise

*First Author: Nivean MADHIVANAN  
Co-Author(s): Sridhar BARATAN, Siva Mohan HALAHARVI, Pratheeba Devi NIVEAN, Abhiyan Kumar PATNAYAK*

**Purpose:** Despite advances in cataract surgical techniques, late dislocation of the intraocular lens (IOL)-bag complex is a challenge faced by ophthalmic surgeons in recent times. This is a case of a patient with pseudoexfoliation who presented with late dislocation of the IOL-bag complex.

**Methods:** This video shows a 23G vitrectomy for the removal of the IOL and the bag complex, which contained 2 capsular tension rings (CTRs), the presence of which was diagnosed on the table. They were carefully removed along the contour of the rings to make sure not to damage the intraocular structures. A secondary IOL, posterior-fixated iris claw lens, was then placed. This was selected instead of an anterior chamber IOL or a scleral-fixated IOL as it has the distinct advantages of less trauma to the sclera, less surgery time, less





postoperative inflammation, and less chances of corneal damage and raised IOP.

**Results:** Postoperatively, the patient had a round pupil with a well-centered IOL and good vision. This video highlights the surprises a surgeon may encounter on the operating table, as well as the need to be alert at all times and have a backup plan for secondary IOL placement.

**Conclusions:** Pseudoexfoliation is a known cause of progressive zonular weakness. The use of capsular tension rings for cases of zonular weakness help to stabilize the bag and aid in IOL placement and centration. Use of posterior chamber iris claw IOL can give good postoperative results with minimal complications.

### Submacular Mobile Pearl (Cysticercus)

*First Author: Vinod KUMAR*

*Co-Author(s): Pradeep KUMAR*

**Purpose:** To demonstrate surgical removal of submacular live cysticercus cyst.

**Methods:** A middle-aged male presented with decrease of vision (20/400) in his left eye (due to live submacular cysticercus cyst) of 1-month duration. He was assessed in terms of color fundus photograph, swept source optical coherence tomography, autofluorescence, and neuroimaging. After informed consent, the patient underwent 25-gauge vitrectomy, inferotemporal retinotomy, cyst aspiration into the vitreous cavity, and cystectomy. Brilliant blue-G assisted internal limiting membrane peeling was performed followed by SF<sub>6</sub> gas tamponade.

**Results:** The patient had no evidence of neurocysticercosis. Pars plana vitrectomy resulted in visual improvement to 20/60. Localized ellipsoid zone and retinal pigment epithelium abnormalities were the cause of limited visual outcome. The visual acuity was maintained through 6 months of follow-up and no epiretinal membrane was seen at last follow-up.

**Conclusions:** Despite the presence of cyst in the submacular space, the results of vitrectomy are rewarding. Outer retinal layers may, however, be affected, limiting the final visual gain.

### Surgical Removal of Intraocular Foreign Body Embedded in Ciliary Body

*First Author: Pradeep KUMAR*

*Co-Author(s): Vinod KUMAR*

**Purpose:** To demonstrate intraocular foreign body (IOFB) removal from the ciliary body in a phakic eye using the double handshake technique.

**Methods:** Case report. A 38-year-old male presented with metallic IOFB embedded in the ciliary body (CB). A 3 x 1.4 x 1.4 mm IOFB embedded in the nasal CB was seen on noncontrast computerized tomography (NCCT) scan of the left orbit. The challenges were phakic status of the patient, approach to IOFB located anteriorly, and means of expressing the IOFB embedded in the CB. A 23-gauge transconjunctival pars plana vitrectomy was done. Scleral indentation was done in a hypotonic globe (after plug removal from ipsilateral scleral port) to allow localization of IOFB in its anterior location. The IOFB was encapsulated, and the light pipe was used to tease it out into the vitreous cavity. Intraocular magnet introduced from a 20-gauge entry was used to lift the IOFB from the posterior pole. A double handshake technique, just posterior to the crystalline lens, under coaxial microscope illumination was used to deliver the IOFB outside.

**Results:** The metallic IOFB was successfully removed out of its embedded location in the CB. A complication in the form of localized anterior rhegmatogenous retinal detachment due to a circumferential tear was noted and successfully managed.

**Conclusions:** IOFB embedded in the CB in a phakic eye presents a unique challenge and can be successfully managed with hypotonic scleral indentation, use of intraocular magnet, and the





double handshake technique.

### **Surgical Removal of Large Brunescant Nucleus Under a Rhegmatogenous Retinal Detachment Associated With Giant Retinal Tear**

*First Author: Pradeep KUMAR*  
*Co-Author(s): Vinod KUMAR*

**Purpose:** To demonstrate removal of a large brunescant nucleus from the subretinal space under a rhegmatogenous retinal detachment (RRD) associated with giant retinal tear (GRT).

**Methods:** Case report. A 62-year-old woman presented 4 weeks after a complicated cataract surgery with best-corrected visual acuity (BCVA) of 1/200 with 9 mm superior sutured corneal wound, corneal edema, ocular hypotony, aphakia, total RRD with inferotemporal 150 degrees GRT, and underlying hard brunescant lens nucleus. The patient underwent 25-gauge pars plana vitrectomy (PPV), perfluorocarbon (PFCL) intraoperative tamponade to help levitate the subretinal lens nucleus, and delicate maneuvering of the lens nucleus inside the vitreous cavity. The lens nucleus was delivered from the corneal wound, the wound resutured, and the RRD associated with GRT was managed successfully with endolaser and direct PFCL silicone oil endotamponade. BCVA at 3 months postoperatively was 6/36.

**Results:** This case showed a novel technique of PFCL-assisted levitation and delicate maneuvering of the subretinal nucleus into the vitreous cavity and out of the eye from an anterior limbal route, preventing damage to the retina and the corneal endothelium.

**Conclusions:** GRT-associated RRDs may occur in complicated cataract surgery with subretinal migration of the entire lens nucleus. The surgeon operating for cataract should prevent these complications. Further, the complication can be safely managed using PFCL-assisted levitation out of the subretinal space.

### **Taming the Giant: Management of Giant Retinal Tear**

*First Author: Shaheeda MOHAMED*  
*Co-Author(s): Chi Wai TSANG*

**Purpose:** A surgical video demonstrating successful management of a 180-degree giant retinal tear retinal detachment. Intraoperative pearls of management are discussed, including meticulous vitreous removal, removal of pigment clumps, and techniques to avoid slippage.

**Methods:** A 55-year-old man presented with left eye loss of vision for 3 days. He was diagnosed with a temporal 180-degree giant retinal tear from 12 to 6 o'clock, with radial extensions at the ends. The surgical video demonstrates lens removal in a phakic eye using phacoemulsification and intraocular lens implant, 23-gauge pars plana vitrectomy without use of encircling band, removal of vitreous gel, excision of anterior flap, perfluorocarbon liquid to unfold and flatten the retina, 360-degree endolaser, and long-acting C3F8 gas tamponade.

**Results:** The retina was attached at 3 months postoperatively.

**Conclusions:** Giant retinal tears comprise 1.5% of rhegmatogenous retinal detachments but present vitreoretinal surgeons with unique and complex intraoperative challenges. Microincisional vitrectomy techniques, valved cannulas, wide-angle viewing systems, chandelier illumination, and perfluorocarbon liquids have radically improved anatomical success rates in the management of giant retinal tear detachments.

### **Transconjunctival Intrascleral Intraocular Lens Fixation With Yamane Double-Needle Technique and Flanged Haptics: Initial Experience**

*First Author: Akshay KOTHARI*  
*Co-Author(s): Aditya KELKAR, Hetal MEHTA*

**Purpose:** To report our initial experience in aspects of safety, outcome, and learning curve







with the Yamane technique.

**Methods:** Prospective interventional study on 31 consecutive patients undergoing scleral-fixated intraocular lens (SFIOL) with the modified Yamane technique was done. All patients underwent comprehensive evaluation including best corrected vision, intraocular pressure, ultrasound biomicroscopy, endothelial cell density, and macular thickness using optical coherence tomography (OCT). We excluded patients with visually significant coexistent pathology like corneal scars, macular pathology, glaucoma, etc.

**Results:** The mean age of subjects was  $57 \pm 16.9$  years and 23 were men (74%). Surgery was performed for aphakia following complicated cataract surgery in 10 eyes (32%), with lensectomy for subluxated/dislocated cataract in 6 eyes (19%), and with IOL explantation for subluxated/dislocated IOL in 15 eyes (48%). There were no intraoperative complications. Visual acuity improved from a median of 1.48 logarithm of the minimum angle of resolution (logMAR) units (IQR, 1.3–2 logMAR) at baseline to 0.3 logMAR (IQR, 0.2–0.4 logMAR) at 6 weeks ( $P < 0.001$ ), which was maintained at 6 months. There were no significant changes in endothelial cell density ( $P = 0.34$ ) and OCT-based macular thickness ( $P = 0.31$ ) at 6 months. Two eyes experienced slight IOL decentration but were managed with appropriate refractive correction.

**Conclusions:** Our initial experience suggests that the Yamane technique for SFIOL is a simple procedure and is independent of scleral flaps, tunnels, sutures, and fibrin glue. It has a short learning curve, is a potentially quicker surgery, and has faster postoperative recovery with excellent visual outcomes. Further studies are required for widespread acceptance of this technique.

## Woes of Vitreoretinal Surgery

*First Author: Vishal GOVINDHARI*

*Co-Author(s): Jay CHHABLANI, Sankeert GANGAKHEDKAR*

**Purpose:** To demonstrate rare complications encountered during vitreoretinal surgery, their cause, and successful management.

**Methods:** Surgical videos recorded over the past 5 years were retrospectively reviewed and surgeries with rare complications were chosen. All surgeries were recorded on a 3-chip camera (PMW-10MD, Sony, Japan) and the operating surgeons included vitreoretinal fellows along with a single consultant. The videos were edited using the Edius Pro 8 software (Grass Valley, Montreal, Canada) and the key steps involving the complications and their management were highlighted.

**Results:** The video encompasses 5 rare complications including subretinal foreign body migration, subretinal migration of brilliant blue dye, subretinal migration of air, suprachoroidal migration of perfluorocarbon liquid (PFCL), and a subretinal hemorrhage following external drainage in a chandelier-assisted scleral buckle surgery. The varied mechanisms leading up to these complications are discussed, which include persistent peripheral vitreous traction, iatrogenic retinal breaks during dye injection for macular hole surgery, iatrogenic choroidal breaks, and inadvertent retinal break during external drainage in a case of scleral buckling.

**Conclusions:** Rare and devastating complications may occur during vitreoretinal surgery. Early recognition and a clear understanding of the exact predisposing event/mechanism are crucial for a good visual outcome. This video also highlights the surgical learning curve a vitreoretinal fellow experiences during his/her tenure. A strong theoretical background, keen observational skills, and a calm attitude are the essentials for a budding vitreoretinal surgeon to tackle any intraoperative complication and deliver good surgical outcomes.

